



VCU

Virginia Commonwealth University
VCU Scholars Compass

Theses and Dissertations


Graduate School

2017

Prevalence and Clinical Characteristics of Teeth Extracted with a Diagnosis of Cracked Tooth: A Retrospective Study

Riley B. Sturgill
Virginia Commonwealth University

Follow this and additional works at: <https://scholarscompass.vcu.edu/etd>

 Part of the [Dental Public Health and Education Commons](#), and the [Endodontics and Endodontology Commons](#)

© The Author

Downloaded from

<https://scholarscompass.vcu.edu/etd/4820>

This Thesis is brought to you for free and open access by the Graduate School at VCU Scholars Compass. It has been accepted for inclusion in Theses and Dissertations by an authorized administrator of VCU Scholars Compass. For more information, please contact libcompass@vcu.edu.

© Riley B. Sturgill, DMD 2017
All Rights Reserved

Prevalence and Clinical Characteristics of Teeth Extracted with a Diagnosis of Cracked Tooth: A Retrospective Study

A thesis submitted in partial fulfillment of the requirements for the degree of Master of Science in Dentistry at Virginia Commonwealth University.

by

Riley B. Sturgill, DMD,
BS, King University, 2008
DMD, Arizona School of Dentistry & Oral Health, 2013

Director: Garry L. Myers, DDS
Director, Advanced Education Program in Endodontics, Department of Endodontics,
Virginia Commonwealth University School of Dentistry

Virginia Commonwealth
University Richmond, Virginia
May, 2017

Acknowledgement

The author wishes to thank several people. I would like to thank my husband, family, and friends for all of their many prayers, love, and support. I would also like to thank Drs. Best, Myers, and Coe for their help and guidance with this project.

Table of Contents

List of Tables	v
List of Figures	vi
Abstract	vii
Introduction.....	1
Materials and Methods.....	7
Results.....	11
Discussion.....	23
References.....	28
Appendix A.....	29
Vita.....	91

List of Tables

Table 1. Number of Extracted Teeth per Patient	12
Table 2. Characteristics of Extracted Teeth and Crack Prevalence	15
Table 3. Adjusted Odds Ratios for Teeth Characteristics	22

List of Figures

Figure 1.....	13
Figure 2.....	16
Figure 3.....	18
Figure 4.....	19
Figure 5.....	20
Figure 6.....	21

Abstract

PREVALENCE AND CLINICAL CHARACTERISTICS OF TEETH EXTRACTED WITH A DIAGNOSIS OF CRACKED TOOTH: A RETROSPECTIVE STUDY

By Riley B. Sturgill, DMD

A thesis submitted in partial fulfillment of the requirements for the degree of Master of Science in Dentistry at Virginia Commonwealth University.

Virginia Commonwealth University, 2017.

Director: Garry L. Myers, DDS

Director, Advanced Education Program in Endodontics, Department of Endodontics

The body of knowledge that exists regarding cracked teeth is limited. The purpose of this study was to determine the prevalence of cracks among extracted teeth. This retrospective longitudinal cohort study included patients of the Virginia Commonwealth University School of Dentistry that underwent extraction procedures over a 6 year period. The sample consisted of 20,408 patients and 40,870 teeth. Statistical analysis software was used to identify diagnoses of a crack, fracture, or split tooth prior to extraction of the tooth by analyzing the Electronic Health Record (EHR) (axiUm™, Version 6.03.03.1035, Exan Corporation, Vancouver, BC, Canada). There were 3,228 teeth identified as cracked in the 40,870 extracted teeth—an overall prevalence of 7.90%. The percentage of cracked teeth were compared using a chi-square test of homogeneity. The prevalence of cracked teeth varied according to tooth type (chi-square = 95.5, $df = 7$, $p < .0001$). Tukey's multiple-comparison procedure identified the groups of tooth types with a significantly different cracked prevalence. The mandibular 2nd molar had the highest prevalence (9.72%). Age and gender were also significantly correlated with cracked teeth.

Introduction

Cracked teeth or “cracked tooth syndrome,” as coined by Cameron (1) is a significant and complicated problem in dentistry. Restoring the cracked tooth has always been somewhat of a dilemma due to the unpredictability of the long-term prognosis. As the population ages, and more and more people are retaining their natural dentition for longer periods of time, this problem will continue to manifest itself, often with vague symptoms (2). Dental providers should seek to gain as much knowledge about the prevalence of common diseases encountered in their practice. The scope of the impact of cracked teeth on dentistry could be better understood if we knew how often it leads to tooth loss. It would be important for the dentist to have the capability of describing the projected outcome of a cracked tooth with a statistic. More research is needed in the area of cracked teeth so that dental professionals can be aware of the current best evidence in regards to treatment being rendered for teeth that have been diagnosed as cracked or fractured. It would be interesting to understand how and why some teeth are diagnosed as cracked and when they may exhibit vague symptomology. Learning about the characteristics of teeth that are extracted due to the diagnosis of a crack or fracture could give insight into possible risk factors or trends.

The human dentition is subject to numerous forces during functional and parafunctional habits. Destructive forces applied to teeth will negatively affect the longevity of a tooth and the dentition. The body of knowledge that currently exists regarding cracked teeth is limited. It is theorized that nocturnal bruxism can elicit much greater occlusal force on the teeth than

conscious effort due to inhibition of cortical suppressors (3). Other factors such as removal of tooth structure during restorative care can weaken a tooth's overall strength. Hiatt (4) was the first to posit that factors such as parafunctional habits, eccentric interferences, the wedging effect of cusp/fossa relations in posterior teeth, the lack of protection of transverse ridges in mandibular molars, and the lever principle of greater forces located more posteriorly near the fulcrum of the temporomandibular joint (TMJ) were factors that may predispose a tooth to fracture. Hiatt also noted that lack of placement of a cuspal coverage restoration greatly affects the likelihood of a crack in posterior teeth that are endodontically treated (4).

There are numerous theories on the causations of cracks, but once a crack is found to be present in a tooth, the clinician must be ready to offer treatment options with predictable outcomes. Many patients present complaining of diffuse pain, discomfort with chewing, and sensitivity to cold and sweets (5). The decision making process following a diagnosis of a crack in a tooth can be quite subjective. Some of the diagnostic aids employed by practitioners to diagnose cracked teeth include the common endodontic diagnostic testing regimen, i.e. cold, hot, EPT, percussion, palpation, bite test, periodontal probing and a radiographic exam. Seo, et al. found the most common clinical feature of cracked teeth was pain to the bite test (6).

Age was also a factor, with persons over the age of 40 having a higher prevalence of cracked teeth (6). Previous studies have found different common methods for successful detection of cracks. Often, a clinician will be suspicious that there is a fracture because of a combination of certain findings: radiographs, periodontal probings, mobility, sinus tract, and treatment history. In 2008, guidelines from the American Association of Endodontists stated that this combination of diagnostic tests and findings in a tooth that had received endodontic therapy (with or without a post) is often pathognomonic for a vertical root fracture (VRF). However, the

gold standard for diagnosis of a crack is visualization of the crack by surgically exposing the fracture or by inspecting an endodontic access prep internally with the dental operating microscope (7). Staining with methylene blue dye and transillumination have also been identified as enhancing techniques to help visualize cracks. Some authors recommend physically separating segments with a sharp instrument to help determine the presence or extent of a crack.

Ehrmann has suggested treatment of cracked teeth by placing an orthodontic band prior to crowning them, then re-evaluating 2-4 weeks later. If at the time of reassessment, the tooth is found to be symptomatic, he recommended nonsurgical root canal therapy in addition to the placement of a full coverage crown (8). Krell and Rivera found that 20% of cracked teeth with reversible pulpitis treated with a full coverage crown required nonsurgical root canal therapy within 6 months due to development of irreversible pulpitis or pulpal necrosis (9). Berman and Kuttler described fracture necrosis in a study showing that teeth with pulpal necrosis and mesial-distal cracks ultimately required extraction (10). The first longitudinal retrospective outcome study about cracks was done in 2006 by Tan, who found that in 49 patients, there was an 85.5% survival rate at 2 years and significant outcome variables included the tooth being in a terminal location, presence of multiple cracks or presence of pre-operative probing depths (10).

Cracks in teeth could allow a nidus of bacterial infection to penetrate into the dentinal tubules (11,12). Many clinicians equate a cracked tooth to a hopeless situation and recommend extraction as a knee jerk reaction. With new studies to classify cracks and more investigation into the extent of cracks (13) we can make more informed decisions about how to treat these teeth.

In the 1997 American Association of Endodontists' Colleagues for Excellence "Cracking the Cracked Tooth Code", Simon (7) reviewed this variability of presenting signs and symptoms.

He stated that the dental history may include chronic undiagnosed pain, repeated occlusal adjustments without relief of symptoms, and a possible history of other cracked teeth.

Radiographically the crack is rarely visible. The difficulty in diagnosing these cracks is compounded by their ability to mimic other orofacial disorders. These could include acute rhinosinusitis, TMJ disorders, headaches, ear pain, atypical facial pain, and other non-odontogenic related pain conditions (14,15). Abbott and Leow (16) confirmed the clinical difficulty in diagnosing cracked teeth with their finding that only 9% of patients are correctly identified with a cracked tooth by the referring general practitioner. In another study by Braly and Maxwell (17), 20% of patients referred to the endodontic practice with diagnostic uncertainties were diagnosed with incomplete tooth fractures. These difficulties in identifying clinical signs and symptoms and the confusing dental histories highlight the complexity of diagnosing and correctly treating these cracked teeth.

In 1973, in a study by Hiatt, 100 teeth were evaluated within a general dentistry practice and diagnosed with incomplete crown-root fractures (4). He confirmed the findings by Cameron (1) in that the most common symptoms were pain with mastication and thermal sensitivity. Cameron and Hiatt both studied the prevalence of cracked teeth. Cameron found that the most commonly involved tooth is the mandibular second molar (1, 4). Hiatt, et al (4) also found the mandibular second molar to be the most commonly cracked tooth, followed by the mandibular first molar, the maxillary premolars and lastly, the maxillary first molars. It is important to note that this was the first study to address the prevalence of these fractures in unrestored or minimally restored teeth. He found that 74% of these incomplete crown-root fractures occurred in unrestored or minimally restored teeth. Ehrmann and Tyas (8) supported this finding in recommending that we should suspect a cracked tooth in any patient presenting with abrupt onset

of pain in a non-restored or shallowly restored tooth. Seo, et al. studied cracked teeth and examined the types of cracks found in 107 teeth, and the characteristics of those teeth. They found that 81% were diagnosed as a cracked tooth, 13% as a VRF, 3.7% as a split tooth, and 1.9% as a fractured cusp. The most commonly cracked tooth type in order of greatest to least was as follows: maxillary first molar, mandibular first molar, mandibular second molar, and maxillary second molar (6). This is not surprising, as Arnold found the ratio of forces on molars, premolars and incisors to be 4:2:1, with significantly greater forces being applied to the most posterior tooth closest to the muscles producing the forces (18).

Terminology related to cracks or fractures seen in teeth has been unorganized and inconsistent over time. Researchers and clinicians alike use a plethora of terms to diagnose or describe the cracked tooth. These terms include: cuspal fracture odontalgia (6), incomplete tooth fracture (2), greenstick fracture (19), cracked tooth syndrome (1), vertical incomplete fracture (20), tooth structure crack (19), and vertical root fracture (21, 22). The terms crack and fracture are often used synonymously in the literature to describe a crack line within a tooth.

With these vastly different terms, one can understand the confusion amongst clinicians in describing a crack within the crown of a tooth. However, the term “cracked tooth” is used to denote a more centered fracture extending apically from the occlusal surface as described by Cameron (1).

There are very few studies that have been conducted addressing the prevalence and characteristics of cracked teeth that may inform the treatment decisions that are made for patients with cracked teeth. The purposes of this retrospective study were to: 1) Analyze the prevalence, demographics, and descriptive characteristics of cracked teeth extracted in a dental school setting, and 2) Evaluate the associations between type of provider (i.e. Faculty, Resident, or

Dental Student) and diagnostic tendencies.

Materials and Methods

The inclusion criteria for the current study were patients over the age of 18, having a permanent first or second premolar, or first or second molar extracted at the Virginia Commonwealth University School of Dentistry (VCU SOD) within the predoctoral, postdoctoral, or faculty practice clinics between January 1, 2010 and December 31, 2016. Eligibility was also based on the presence of a clinical note associated with the extraction on or before the extraction date. The ADA CDT codes that were included were codes for extraction of an erupted or exposed root (D7140) or surgical removal of erupted tooth requiring elevation of mucoperiosteal flap and removal of bone and/or sectioning of tooth (D7210).

A pilot study was performed over a 2-month period of clinical records from February 1, 2016 through March 31, 2016 of all patients meeting the inclusion criteria in order to develop methods to extract pertinent data and identify cracked teeth that were extracted. Keywords were formulated by the authors to develop a list of the common and unusual diagnostic terms that practitioners use to denote a cracked tooth. Yes- and No-words were identified to analyze how to most accurately search clinical notes for true diagnoses of cracked teeth versus mentions of common words associated with cracks that are used in other contexts. For example, the following excerpt from a clinical note includes a Keyword contained within a No-word: “#31 DB abfraction lesion noted, but restorable.” In this patient, #31 would therefore be counted as Crack=No because the Keyword “fract” is associated with a No-word “abfraction”. Also, if Keywords were located in specific relationships to No-words, the program would count a tooth as “not cracked,” as in the following examples: “broken fillings,” “distal marginal ridge broken

down,” or “crown broken off.”

The pilot study was done to compare the accuracy, sensitivity, and specificity of the computer algorithm to a manual review of the clinical notes by the authors. The sensitivity was calculated to be 99.4%. The specificity was found to be 84.6%, and the overall accuracy of the computer algorithm was 96%.

Next, the axiUm™ clinical database at VCU SOD was queried to first identify patients having first and second molars and premolars extracted over a period of seven years, from January 1, 2010 through December 31, 2016. Two separate AxiUm™ queries were requested, the first of which identified all eligible extracted teeth from the procedure codes database. The query downloaded records of all patients that had eligible teeth extracted within the date range. This resulted in 61,016 reported teeth. After the removal of records not meeting all inclusion criteria and duplicates, a total of 60,363 teeth remained as potentially eligible. Using this list, all of the unique chart numbers were extracted, along with the last extraction date. These were deidentified as per IRB guidelines for this study.

A second AxiUm™ query was used to aggregate all of the clinical chart notes for these patients, on or before the latest extraction date. This request resulted in charts from 28,785 patients. The results were again checked for any patients not meeting the inclusion criteria, and any duplicates were eliminated. There were 20,408 patients and 40,870 extracted teeth eligible for the study. The chart notes were imported as blocks of text that were then broken into “sentences” of text—where a “sentence” was defined by a line-feed character or by a block of text ending with a period and a space.¹ In order to determine whether a particular extracted tooth

¹ The following words were not considered the end of a sentence: Dr., Pt., pt., max., Max., min., Min., appt., Appt., Neg., neg., Pos., or pos.. Additionally, all non-ASCII characters were removed—ASCII (American Standard Code for Information Interchange) characters are all the letters, numbers, and standard punctuation.

was cracked, these sentences were searched. Only the sentences from chart notes on or before the date of extraction were searched—except that the “chief complaint” line in the chart note was not searched. Additionally, portions of the text that were in quotations, as would be subjective information spoken by the patient and recorded in the EHR, were not searched. The search was done in two steps. First, the tooth number from the extraction file was used to identify a chart note sentence that referred to that tooth. That is if tooth #14 was extracted, then “#14” was searched in the sentence from the chart note. If a sentence did not refer to the extracted tooth, it was not searched further. If a sentence did refer to the extracted tooth, then the sentence was searched for the following key-words: “crack”, “split”, “broke”, “fx”, “vrf”, or “fract.” The pilot study revealed that fracture was often abbreviated as “fract,” and sometimes misspelled as “farct,” which was corrected for prior to the initial search in the current study to eliminate false negatives. Also, if “fx” was contained within the abbreviation for infection: “infxn,” it was not counted as a keyword. If one of the keywords was found, then the sentence was marked with the found word and saved for further consideration. Candidate sentences were further searched for the following Yes-words: “root”, “horizontal”, or “vertical.” Secondly, the following No-words (including fragments of words) were searched: “clasp”, “bracket”, “appliance”, “amalgam”, “porcelain”, “retainer”, “denture”, “partial”, “deliver”, “forcep”, or “elevat.” A “phrase” which included the keyword in conjunction with the tooth number and 100 characters before and after the key word was then isolated using the search algorithm. Finally, the extracted tooth was marked as “Cracked=Yes” if any Yes-words were found and none of the No-words were found. Extracted teeth phrases without Yes-words or with any of the No-words were marked as “Cracked=No.”

Variables

Patient age at the time of tooth extraction was calculated by using the patient's date of birth and the extraction date, in whole years. For the purposes of analysis, these ages were grouped into four categories: 18 to 35 years, 36 to 50 years, 51 to 65 years, and 66 years and older. Teeth were then categorized into 8 tooth types (maxillary first premolar, maxillary second premolar, mandibular first premolar, mandibular second premolar, maxillary first molar, maxillary second molar, mandibular first molar, and mandibular second molar).

The retrospective study design was independently reviewed and approved by the VCU Institutional Review Board (IRB #: HM20006705). Results were summarized with counts and percentages or with means and standard error, as appropriate. Associations were tested using likelihood-ratio chi-square analysis. A multi-variable logistics regression was used to test for the associations between all the patient and tooth characteristics jointly. All statistical analyses were performed using SAS software (JMP pro 11, SAS Institute Inc., Cary NC). Statistical significance was declared at $\alpha=0.05$.

Results

A description of the patients and extracted teeth are presented first. Next, the individual associations between tooth characteristics and cracked teeth are reviewed. Finally, the joint associations are described.

Characteristics of the Patients

The 20,408 patients were more often male (50%, n =10,192) than female (49.8%, n=10,173) or unidentified gender (0.2%, n=41). The average age was 45.2 years (SD = 16.45, range = 18 to 101). There were 28% of the patients in the 18-35 years age range (n = 11,384), 26% in the 36-50 years age range (n = 10,605), 31% in the 51-65 years age range (n=12,490), and 16% were in the 66 years or older age range (n = 2,626). Sixty-two percent of patients had a single tooth extracted (**Table 1**) and an additional 19% had two teeth extracted. Approximately 2% of the sample had 10 or more extractions.

Table 1. Number of Extracted Teeth per Patient

Number of extracted teeth	<i>n</i>	Percent
1	12583	61.66
2	3861	18.92
3	1501	7.35
4	820	4.02
5	452	2.21
6	277	1.36
7	236	1.16
8	168	0.82
9	118	0.58
10	88	0.43
11	91	0.45
12	55	0.27
13	54	0.26
14	41	0.20
15	23	0.11
16	40	0.20
Total	20408	100.00

Figure 1. Number of Extracted Teeth Across Time

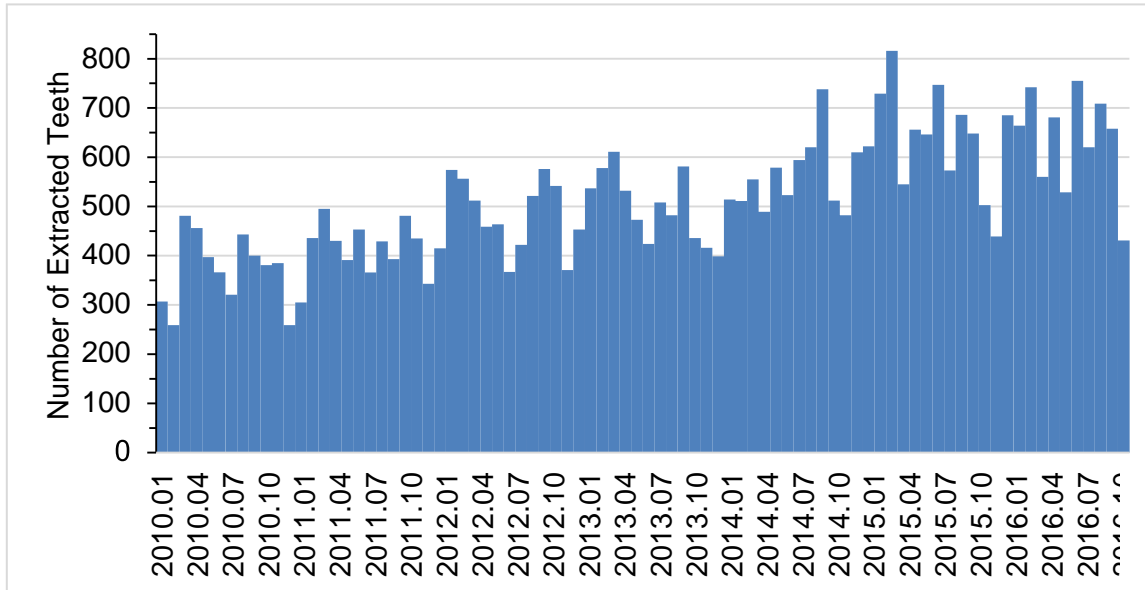


Figure 1 illustrates the number of extractions over the course of the study. An overall increase in extractions is seen from January 2010 through December 2016.

Characteristics of the Extracted Teeth

The search algorithm isolated phrases within the patient’s EHR that contained keywords indicating a cracked tooth. The most common keyword was “fract”, found in 6.5% (n = 2663) of all extracted teeth. Next most common was “broke” (1.43%, n = 586), followed by “crack” (0.36%, n = 147), “fx” (0.27%, n = 109), “split” (0.08%, n = 34), and three instances of “vrf”. Yes-words were used to confirm the keywords. The most commonly found Yes-word was “root” (n = 410), followed by “vertical” (n = 97), and “horizontal” (n = 9). No-words were used to deny the keywords. The most common no-word was “amalgam” (n = 145), followed by “elevat” (n = 73), “forcep” (n = 35), “partial” (n = 27), “porcelain” (n = 19), “deliver” (n = 7), “denture” (n = 4), “clasp” (n = 2), followed by single instances of “bracket” and “retainer”.

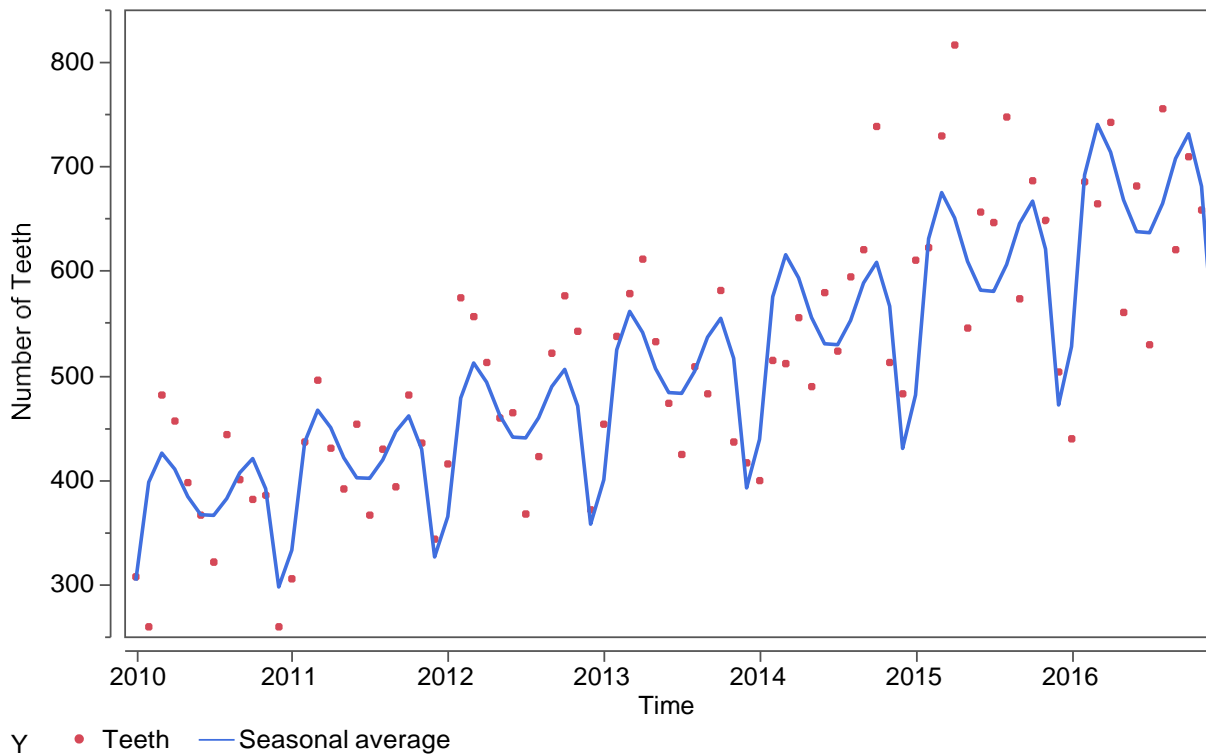
In the 40,870 extracted teeth eligible for the study, the most common tooth type was the second mandibular molar (17%) and the least common was the first mandibular premolar (7%). (See “Extracted Teeth” columns in.). 63% were molars and there were more extracted teeth in the maxillary arch (54%). Across the 7-year time span, the number of extractions increased from 4,138 in 2010 to 7,106 in 2016.

Table 2. Characteristics of Extracted Teeth and Crack Prevalence

Characteristic	Extracted Teeth		Cracked			95% CI	P-value	SE
	n	%	No	Yes	% Yes			
Overall	40870	100.0	37642	3228	7.90	(7.64 to 8.16)		0.13
Tooth type							<.0001	
Max 1 st Premolar	4404	10.78	4018	386	8.76	(7.93 to 9.60)	ab	0.43
Max 2 nd Premolar	4825	11.81	4417	408	8.46	(7.67 to 9.24)	abc	0.40
Max 1 st Molar	5794	14.18	5339	455	7.85	(7.16 to 8.55)	bc	0.35
Max 2 nd Molar	5962	14.59	5548	414	6.94	(6.30 to 7.59)	bc	0.33
Mand 1 st Premolar	2901	7.10	2780	121	4.17	(3.44 to 4.90)	d	0.37
Mand 2 nd Premolar	3763	9.21	3467	296	7.87	(7.01 to 8.73)	bc	0.44
Mand 1 st Molar	6318	15.46	5704	614	9.72	(8.99 to 10.45)	a	0.37
Mand 2 nd Molar	6903	16.89	6369	534	7.74	(7.11 to 8.37)	c	0.32
Tooth Type							0.0959	
Premolar	15893	38.89	14682	1211	7.62	(7.21 to 8.03)		0.21
Molar	24977	61.11	22960	2017	8.08	(7.74 to 8.41)		0.17
Arch							0.8384	
Mandibular	19885	48.65	18320	1565	7.87	(7.50 to 8.24)		0.19
Maxillary	20955	51.27	19322	1633	7.79	(7.43 to 8.16)		0.19
Age							0.0137	
18-35	11384	27.85	10427	957	8.41	(7.9 to 8.92)	a	0.26
36-50	10495	25.68	9673	822	7.83	(7.3 to 8.35)	b	0.26
51-65	12490	30.56	11575	915	7.33	(6.9 to 7.78)	b	0.23
66+	6501	15.91	5967	534	8.21	(7.5 to 8.88)	ab	0.34
Gender							0.5020	
Female	19883	48.65	18294	1589	7.99	(7.61 to 8.37)		0.19
Male	20941	51.24	19305	1636	7.81	(7.45 to 8.18)		0.19
other	46	0.11	43	3	6.52			3.64
Year							<.0001	
2010	4138	10.12	3942	196	4.74	(4.09 to 5.38)	bc	0.33
2011	4625	11.32	4405	220	4.76	(4.14 to 5.37)	b	0.31
2012	5502	13.46	5320	182	3.31	(2.84 to 3.78)	d	0.24
2013	5766	14.11	5561	205	3.56	(3.08 to 4.03)	cd	0.24
2014-pre template	1900	4.65	1844	56	2.95	(2.19 to 3.71)	d	0.39
2014-post template	4349	10.64	3822	527	12.12	(11.15 to 13.09)	a	0.49
2015	7483	18.31	6549	934	12.48	(11.73 to 13.23)	a	0.38
2016	7106	17.39	6198	908	12.78	(12.00 to 13.55)	a	0.40
Provider							<.0001	
Faculty	4512	11.04	4303	209	4.63	(4.02 to 5.25)	c	0.31
Resident	10969	26.84	10384	585	5.33	(4.91 to 5.75)	b	0.21
Student	25388	62.12	22954	2434	9.59	(9.23 to 9.95)	a	0.18

Figure 2 shows the number of extracted teeth over the course of the study. Each dot represents the number of teeth extracted during a calendar month and the blue line is a linearly increasing, seasonally-adjusted average. The dips in the line correspond to the December-January time frame when the School of Dentistry clinics are open less often and the June-July time frame when summer holidays occur and the clinics are closed during a 2-week period.

Figure 2. Number of Extracted Teeth: Seasonal Changes



Prevalence of Cracked Teeth

There were 3,228 teeth identified as cracked in the 40,870 extracted teeth—an overall prevalence of 7.90%. Also note that the shading in Table 2 indicates the magnitude of the difference, as compared to the overall average with red indicating more cracks and green indicating less cracks. That is, %Yes values around 7.90% are shaded yellow and values 4% more are shaded red (i.e., 11.90%) and values 4% less are shaded green (i.e., 3.90%). In the

20,408 patients, 12.58% (n=2,567) had at least one cracked tooth, and the per-person prevalence was 10.58%.

Relationships Between Teeth Characteristics and Cracked Teeth

The percentages of cracked teeth were compared using a chi-square test of homogeneity. The prevalence of cracked teeth varied between the eight tooth types (chi-square = 95.5, df = 7, p <0.0001). Tukey's multiple-comparison procedure identified the groups of tooth types with significantly different cracked prevalence. The superscripts next to the "%Yes" column values indicate group difference. Groups sharing the same letter are not significantly different. That is, the mandibular first molar group had the highest prevalence (9.72%), which was significantly higher than all the other tooth types except the two maxillary premolar groups. The mandibular first premolar teeth had the lowest prevalence (4.17%), which was significantly lower than all other tooth types.

Molars had somewhat of a higher prevalence of cracks than premolars (8.08% vs. 7.62%), but the difference was not significant (chi-square = 2.77, p = .0959) and there was no evidence for a difference between the prevalence in mandibular teeth and maxillary teeth (7.87% vs. 7.79%, chi-square = 0.04, p = .8384). There is some evidence for a difference depending upon age (chi-square = 8.57, df = 2, p = 0.0137). Those aged 18-35 years of age had a higher prevalence than those aged 36-50 years or 51-65 years (8.41% vs. 7.83% & 7.33), but not significantly higher than those aged 66 and older (8.21%). Males had a lower prevalence than females (OR = 0.92, 95% CI 0.855-0.991, p = 0.0280).

A curious and dramatic increase in the prevalence rate (chi-square = 1084, p < .0001) was seen across time. Upon further inspection, it was observed that the prevalence of cracked teeth throughout 2013 and into the first few months of 2014 averaged 3.3%. And then in May, 2014 it

was 9.2%. In the last eight months of 2014 the average prevalence was 11.9%. This was attributed to the adoption of a standard clinical note diagnosis template utilized in the predoctoral clinics. Also, there were numerous research projects being done within the VCU SOD, namely in the endodontic department, involving diagnosis of cracked teeth.

Figure 3. Prevalence of Cracked Teeth by Month

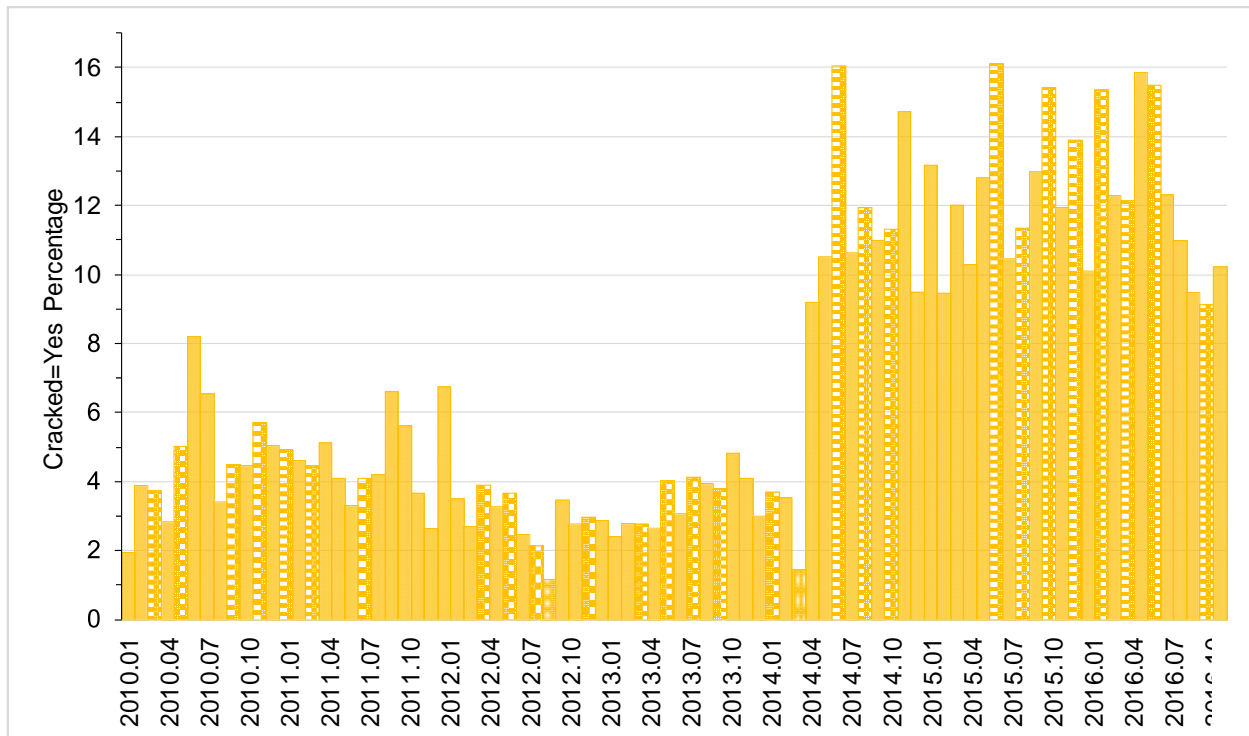


Figure 3 shows differences “2014-pre template” and “2014-post template”. However, it also complicates the primary aim of the study. Estimating prevalence depends upon the methods used to diagnose a cracked tooth—if a practitioner uses rough, informal methods, they see fewer cracks and if a practitioner uses a more systematic approach, they see many more cracks.

Changes across the months seemed to be mostly localized in the dental students (Figure 4). In the figure, there is one dot per month and provider group. The three trend-lines correspond to smoothed trends across time.

Figure 4. Prevalence of Cracked Teeth by Year and Provider

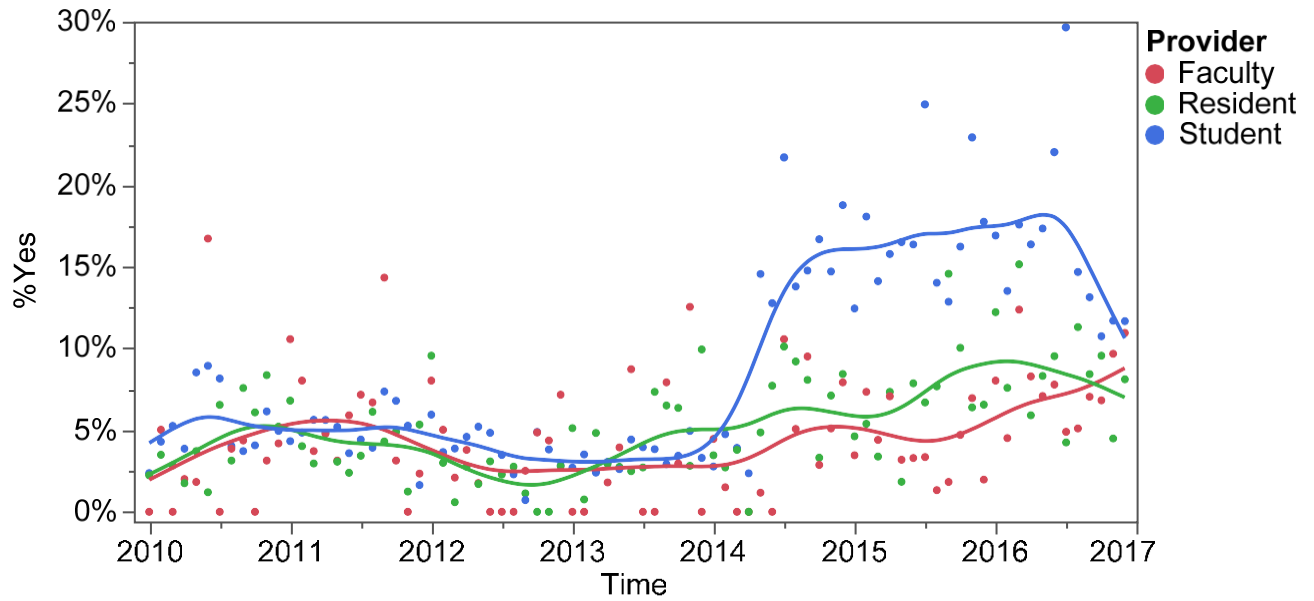


Figure 4 illustrates the prevalence of cracked teeth reported per month over the course of the study, parsed by provider type. The faculty, resident, & student groups are relatively similar during the “pre-template” time period. A marked increase in prevalence is then seen among the student provider group during the “post-template” time period.

Figure 5. Prevalence of Cracked Teeth by Tooth Type, Pre- vs. Post-template

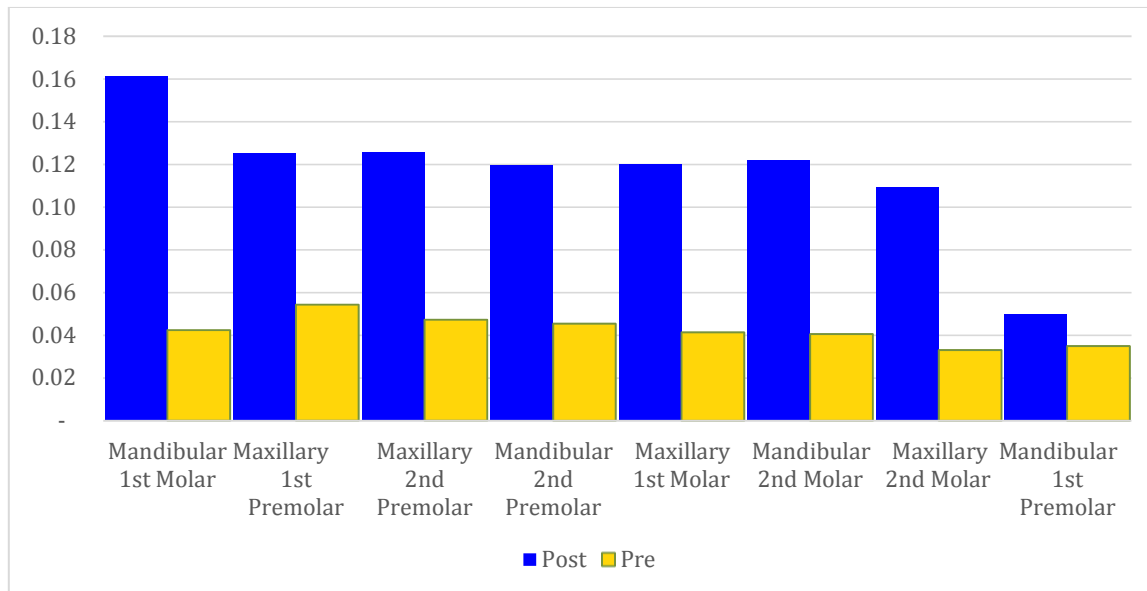


Figure 5 shows the difference between pre- and post-template prevalence of cracked teeth per tooth type.

Figure 6. Prevalence of Cracked Teeth by Age

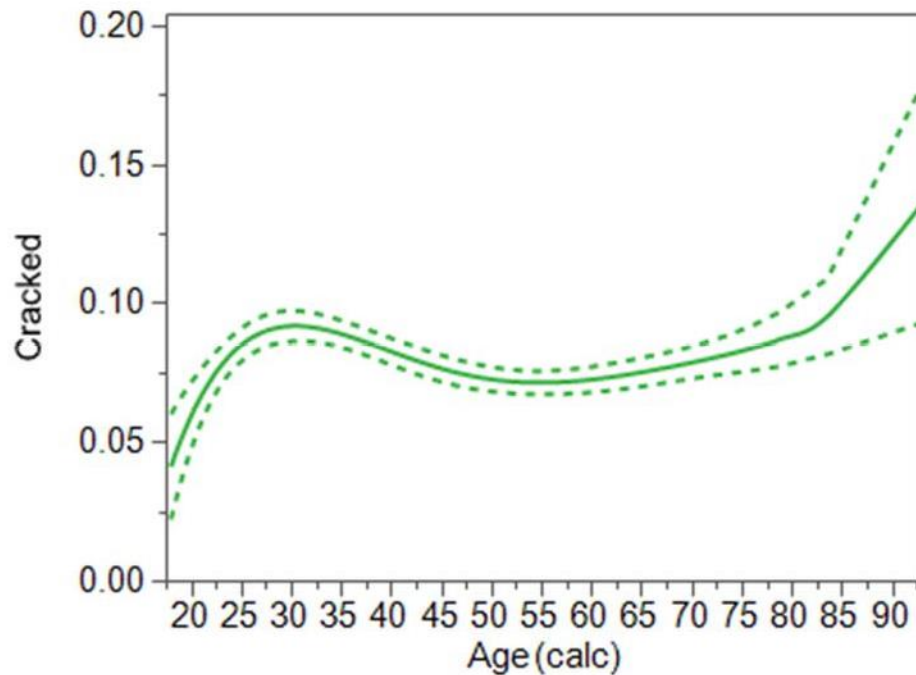


Figure 6 illustrates that the prevalence of teeth extracted following the diagnosis of a crack sharply increases at the third decade of life, plateaus until the eighth decade of life, and then sharply increases again.

Logistic regression

Note that all of the previously described differences according to teeth characteristics have been univariate analysis. That is, each characteristic was considered individually. A logistic regression was used to consider all of the characteristics together. The results of the multi-variable logistic regression indicated that tooth type, age, year and provider all remained statistically significant and, after adjusting for other factors, gender became significant.

Table 3. Adjusted Odds Ratios for Teeth Characteristics

Effect	OR	95% CI	P-value
Tooth type			<.0001
Max 1 st Premolar	1.000		
Max 2 nd Premolar	0.945	(0.815 to 1.097)	
Max 1 st Molar	0.859 *	(0.744 to 0.993)	
Max 2 nd Molar	0.736 *	(0.634 to 0.853)	
Mand 1 st Premolar	0.466 *	(0.375 to 0.574)	
Mand 2 nd Premolar	0.911	(0.775 to 1.070)	
Mand 1 st Molar	1.086	(0.947 to 1.247)	
Mand 2 nd Molar	0.838 *	(0.728 to 0.965)	
Age			0.0423
18-35	1.000		
36-50	0.942	(0.853 to 1.041)	
51-65	0.878 *	(0.796 to 0.969)	
66+	0.995	(0.886 to 1.117)	
Gender			0.0298
Female	1.000		
Male	0.922 *	(0.856 to 0.992)	
Year			<.0001
2010	1.000		
2011	0.952	(0.781 to 1.161)	
2012	0.672 *	(0.546 to 0.826)	
2013	0.714 *	(0.585 to 0.873)	
2014-pre template	0.586 *	(0.429 to 0.787)	
2014-post template	2.780 *	(2.347 to 3.305)	
2015	2.900 *	(2.477 to 3.411)	
2016	2.995 *	(2.557 to 3.525)	
Provider			<.0001
Faculty	1.000		
Resident	1.287 *	(1.095 to 1.519)	
Student	2.426 *	(2.100 to 2.817)	

* Significantly different from the reference, $p < .05$.

Discussion

The current study sought to identify the prevalence of extractions of cracked teeth and to analyze associations to gender, age and tooth type. In this study, the most commonly extracted cracked teeth were mandibular first molars, followed by maxillary first and second premolars, mandibular second premolars, maxillary first molars, mandibular second molars, maxillary second molars, and mandibular first premolars. These results were determined after adjusting for sex and age.

It has been hypothesized that the frequency of cracks among females is higher because of behavior patterns leading to better dental care (11). Other studies argued that males show more cracks because of more advanced development of their masticatory muscles (27, 28, 34). In contrast to these speculations, other studies did not find any sex-related differences (14, 35). The current study does link gender to a higher prevalence of cracked teeth—7.99% in females vs. 7.81% in males—a statistically significant difference after adjusting for all other factors ($p = 0.0280$).

Factors related to cracked teeth have been identified in previous studies. Cuspal flexure of teeth restored due to caries or endodontic access, malocclusion, bruxism, and longer tooth retention are implied risk factors for cracked teeth (29, 30, 31, 32). With an aging population, heavily restored dentitions are becoming increasingly common.

Previously, Hiatt evaluated the prevalence of cracks and noted that the most commonly involved teeth for incomplete fractures were the mandibular second molars, followed by the mandibular first molars, maxillary premolars and maxillary first molars (3). The sample size was

100 teeth, and no statistical analysis was done. Seo studied 107 teeth with longitudinal fracture and found the maxillary first molar was most frequently cracked, followed by the mandibular first molar, the mandibular second molar, and the maxillary second molar. Fisher's Exact Test was used due to the small sample size, and there was no adjustment for sex or age in the statistical analysis. Cameron's seminal study included 50 cracked teeth and simply tabulated the results. The current study generally agrees with both of these studies' findings, with mandibular first molars being cracked most often followed by maxillary first and second premolars, maxillary first molars, mandibular second molars, maxillary second molars and lastly mandibular first premolars. However, after adjusting for sex and age, this study indicates that perhaps maxillary premolars are more prone to cracks than previously expected. The current and previous studies also found an increased incidence of cracked teeth in the third and fourth decades of life (31, 33). Also, there was a marked increase around the eighth decade of life. The confidence interval in the youngest and oldest age ranges was larger than the middle age ranges, reflecting the lower number of enrollees among the young and old. Perhaps the age ranges chosen for this study were not ideal in reflecting significant differences. Figure 6 illustrates more clearly the changes in prevalence of cracked teeth based on age.

Osaghae has reported a prevalence of split teeth requiring extraction to be 5% out of a sample of 670 extracted teeth (40). Bader completed an insurance-based study that included 74,503 HMO plan enrollees. Clinicians documented detection of complete crown fractures and reported a prevalence of 4.4% (41). The current study reports a prevalence of 7.9%.

The data from this study indicates that dental professionals should not only recognize the increasing prevalence of cracked teeth, but also work to take preventive measures of the same ilk that other dental diseases, such as caries and periodontal disease are met with.

Endodontists are very familiar with high magnification for inspection, and utilize transillumination frequently to assess for cracks. General dentists should be encouraged to utilize these diagnostic aids as well. Pen lights are a convenient alternative to transilluminators. Working as an interdisciplinary group with other specialists, such as orthodontists, to correct malocclusions that attribute to destructive occlusal wear will help reduce the risk of tooth fracture for our patients.

Limitations of this study became evident in the form of inconsistencies with diagnostic terms and lack of thorough clinical note documentation. The patients that were seen only for extractions (i.e. they were not established patients of record within any of the clinics,) had only short diagnostic descriptions within their EHR. This could be attributed to patients presenting with grossly carious teeth, obviously being nonrestorable. In such cases, the clinician may have then only noted “nonrestorable” as the reason for extraction. This could have led to an errantly low reported prevalence of cracks using the methods of this study, or inaccuracy in diagnosing cracked teeth.

Conceivably, if this study were to be prospective, with standardized diagnostic measures completed on every tooth by only experienced clinicians, the reported prevalence could be more accurate. For example, if each patient’s dental history was carefully recorded, and cold testing, tooth slooth and bite testing, inspection for cracks using transillumination and staining under high magnification were completed, more accuracy could be achieved. The biggest challenge with study design is the lack of a standard protocol for detecting and diagnosing cracks. Each clinician forms their individual methods for diagnosing a cracked tooth. Another consideration is the variability in a patient’s subjective and objective clinical findings.

Patients that had multiple teeth extracted (Table 1) could have done so due to prosthodontic

treatment plans (i.e. full dentures), in which case the diagnostic procedures may have been abbreviated or incomplete. However, over 80% of the patients included in this study had only one or two teeth extracted. Another likely scenario that could have occurred is a patient presented with gross decay on multiple teeth, or even a single tooth, and the tooth was deemed “nonrestorable.” Oftentimes, in an emergency visit, if a tooth is not restorable and the patient elects to have an extraction, the full gamut of endodontic and diagnostic testing may have been minimized or forgone.

Another factor that affects treatment decisions is cost. This consideration could have had a similar effect on the reported prevalence as nonrestorability of teeth. For example, a patient reports for an emergency visit and requests an extraction instead of root canal therapy and restoration of a tooth. In these cases, the practitioner may not have completed thorough diagnostic testing or electronic health record charting. This would decrease the reported prevalence of cracked teeth in this study.

Other design errors of this study may include insufficient recognition of Yes-words and No-words due to unusual misspellings and possibly other uncommon diagnostic terms used by some clinicians. Future study designs could be more thorough in pre-correcting misspellings and grammar in clinical notes prior to searching for Yes-words and No-words. Another limitation of this study was the inconsistency of the use of a diagnosis template, as was adopted in the middle of 2014 at VCU SOD. The use of the template significantly increased the reported prevalence of cracked teeth diagnoses. This is interesting, in that it seems that prompts within the EHR of axiUm™ required clinicians to describe teeth being extracted more thoroughly (i.e., examining for fractures in order to fill in a drop down questionnaire) thus resulting in more diagnoses of cracked teeth. However, it also complicates the primary aim of the study. Estimating prevalence

depends upon the methods used to diagnose a cracked tooth—if a practitioner uses rough, informal methods, they see fewer cracks and if a practitioner uses a more systematic approach, they see many more cracks.

The study design used for the current study could be modified for future research. One could answer the question, “How many endodontically treated teeth, previously diagnosed as cracked, ultimately lead to extraction?” Also, the variable of longevity of survival of endodontically treated cracked teeth could be isolated.

Within the dental school setting, it seems of utmost importance that students be aware that cracked teeth are becoming more commonplace with the aging of the population as a whole. EHR templates could be tailored to aid in thorough diagnostic testing to be recorded and analyzed in future studies. This was shown clearly in the present study, because with the introduction of the diagnosis templates at VCU SOD, the reported incidence of cracked teeth increased significantly.

It is important for dentists to realize that the cracked tooth is one of the most prevalent reasons for tooth loss. With that in mind, dental practitioners can be more proactive to prevent tooth loss resulting from cracks as more data is accumulated from studies related to cracked teeth.

References

1. Cameron CE. Cracked-tooth syndrome. J Am Dent Assoc. 1964;68:405-11.
2. Ritchey B, Mendenhall R, Orban B. Pulpitis resulting from incomplete tooth fracture. Oral Surg Oral Med Oral Pathol. 1957; 10:665-70.
3. Hiatt WH. Incomplete crown-root fracture in pulpal-periodontal disease. J Periodontol. 1973; 6:369-79.
4. Ehrmann EH, Tyas MJ. Cracked tooth syndrome: diagnosis, treatment, and correlation between symptoms and post-extraction findings. Aus Dent J. 1990;2:105-12.
5. Krell KV, Rivera EM. A six-year evaluation of cracked teeth diagnosed with reversible pulpitis: treatment and prognosis. J Endod. 2007; 33:1405-7.
6. Berman LH, Kuttler S. Fracture necrosis: diagnosis, prognosis assessment, and treatment recommendations. J Endod. 2010; 36:442-6.
7. Tan L, Chen NN, Poon CY, Wong HB. Survival of root filled cracked teeth in a tertiary institution. Int Endod J. 2006; 39:886-9.
8. Bergenholtz G. Pathogenic mechanisms in pulpal disease. J Endod 1990;16:98-101.
9. Tronstad L, Langeland, K. Electron microscopy of human dentin exposed by attrition. Scand J Dent Res. 1971;79:160–171.
10. Detar MS. Evaluation of the prevalence and clinical characteristics of intrapulpal cracks

utilizing a novel classification system. VCU Scholars Compass 2014.

11. Homewood CI. Cracked tooth syndrome- Incidence, clinical findings and treatment. *Aus Dent J.* 1998;43:217-22.
12. Arnold M. Bruxism and the occlusion. *Dent Clin North Am.* 1981; 25:395-407.
13. Attanasio R. Nocturnal bruxism and its clinical management. *Dent Clin North Am* 1991; 35:245-52.
14. Seo D, Yi Y, Shin S & Park J. Analysis of factors associated with cracked teeth. *J of Endod* 2012;38:288-92.
15. Cracking the cracked tooth code. *Endodontics: Colleagues for Excellence* 1997 (Fall/Winter): 1-13.
16. Snyder DE. The cracked-tooth syndrome and fractured posterior cusp. *J Oral Surg.* 1976; 10:698-704.
17. Brynjulfson A, Fristad I, Grevstad T, Hals-Kvinnslund I. Incompletely fractured teeth associated with diffuse longstanding orofacial pain: diagnosis and treatment outcome. *Int Endod J.* 2002; 35:461-6.
18. Abbott P, Leow N. Predictable management of cracked teeth with reversible pulpitis. *Aus Dent J.* 2009; 54:306-15.
19. Braly BV, Maxwell EH. Potential for tooth fracture in restorative dentistry. *J Pros Dent.* 1981; 4:411-414.
20. Gibbs JW. Cuspal fracture odontalgia. *Dent Dig.* 1954; 60:158-60.
21. Sutton PR. Greenstick fracture of the tooth crown. *Brit Dent J.* 1962; 113:362-3.
22. Johnson WT, Leary JM. Vertical root fractures: diagnosis and treatment. *Gen Dent.* 1984; 32:425-9.

23. Talim ST, Gohil KS. Management of coronal fractures of permanent posterior teeth. *J Pros Dent.* 1974; 31:172-8.
24. Abou-Rass M. Crack lines: the precursors of tooth fractures – their diagnosis and treatment. *Quintessence Int.* 1983; 4:437-47.
25. Cohen S, Berman LH, Blanco L, Bakland L, Kim JS. A demographic analysis of vertical root fractures. *J Endod.* 2006; 32:1160-3.
26. Chladek W, Lipski T, Karasinski A: Experimental evaluation of occlusal forces. *Acta Bioengineering Biomech.* 2001; 3(1):25-37.
27. Helkimo E, Ingervall B: Bite force and functional state of the masticatory system in young men. *Swed Dent J.* 1978, 2:167-175.
28. Arnold M: Bruxism and the occlusion. *Dent Clin North Am.* 1981; 25:395-407.
29. Rosen H: Cracked tooth syndrome. *J Prosthet Dent.* 1982; 47:36-43. 10.1016/0022-3913(82)90239-6.
30. Udoye CI, Jafarzadeh H: Cracked tooth syndrome: characteristics and distribution among adults in a Nigerian teaching hospital. *J Endod.* 2009; 35:334-336. 10.1016/j.joen.2008.12.011.
31. Rivera EM, Williamson A: Diagnosis and treatment planning: cracked tooth. *Texas Dent J.* 2008, 120 (3):278-283.
32. Roh BD, Lee YE: Analysis of 154 cases of teeth with cracks. *Dent Traumatol.* 2006, 22:118–123.
33. Helkimo E, Ingervall B: Bite force and functional state of the masticatory system in young men. *Swed Dent J.* 1978, 2:167–175.
34. Turp JC, Gobetti JP: The cracked tooth syndrome: an elusive diagnosis. *J Am Dent Assoc.*

1996, 127:1502–1507.

35. Opdam NJ, Roeters JJ, Loomans BA, Bronkhorst EM. Seven-year clinical evaluation of painful cracked teeth restored with a direct composite restoration. *J Endod.* 2008, 34:808-11.
36. Roh BD, Lee YE. Analysis of 154 cases of teeth with cracks. *Dent Traumatol.* 2006; 22:118-23.
37. Cracking the cracked tooth code: detection and treatment of various longitudinal fractures. *Endodontics: Colleagues for Excellence 2008 Bonus Material G (Summer):* 1-19.
38. Silvestri AR, Singh I. Treatment rationale of fractured posterior teeth. *J Am Dent Assoc.* 1978; 97:806-10.
39. Cracking the cracked tooth code: Detection and treatment of various longitudinal tooth fractures. *Endodontics: Colleagues for Excellence 2008 (Summer):* 1-8.
40. Osaghae IP, Azodo CC. Analysis of split tooth as an unstudied reason for tooth extraction. *BMC Res Notes.* 2014; 7:630.
41. Bader JD, Martin JA, Shugars DA. Preliminary estimates of the incidence and consequences of tooth fracture. *J Am Dent Assoc.* 1995, 126:1650-54.

Appendix A

Sentences found to have the cracked key-words, and potentially a No-word, or a Yes-word.

Date	Tooth	Key-No-Yes	phrase
1/4/2010	14	fract--	#14 fractured, temporary material in canal, pulpectomy started in December 09
1/4/2010	14	fract--vertical	vertical root fracture of #14
1/4/2010	15	broke--root	#15, #16 broken down, root tips
1/4/2010	3	fract--	#3 gross caries, crown fractured
1/5/2010	18	fract--	#18 fractured during extraction and (resident) extracted surgically with handpiece.
1/8/2010	31	fract--	#31 buccal abfraction
1/8/2010	31	fract--	#31 DB abfraction lesion noted, but restorable.
1/8/2010	31	fract--	pt have significant abfraction lesion on DB of #31.
1/22/2010	18	fract--	Lingual portion of #18 fracture and is movable.
1/22/2010	18	fract--	A: #18 is non-restorable due to the depth of the fracture.
1/22/2010	18	fract--	P: Informed patient that #18 is non-restorable due to the severity of the fracture.
1/22/2010	18	fract--	Fractured #18
1/29/2010	31	fract-amalgam-	#31 has large pin retained amalgam build-up with a fracture line running M-D.
1/29/2010	31	fract--	Took 1 PA #31, Explained to pt that tooth is fractured and has poor prognosis.

Date	Tooth	Key-No-Yes	phrase
2/4/2010	30	fract--	Number 30 presents with a fractured restoration and severe periodontal loss and also recc.
2/8/2010	14	fract--	fractured non restorable 14
2/8/2010	14	fract--	Fractured 14
2/8/2010	14	fract--	fractured tooth 14
2/9/2010	15	broke--	O: BP: 106/64 Pulse 72 bpm, Med +, All +, Hosp+, Ill +, POE revealed broken fillings #'s 29 & 31, primary decay #15, recurrent decay #20, no other pathology noted
2/9/2010	2	broke--	Caries on #2 with crown broken off
2/11/2010	14	crack--	and it was suggested at that time to have #14 removed, last week tooth cracked, no pain
2/11/2010	14	broke-partial-	partially edentulous, broken #14 unrestored from prior endo.
2/16/2010	18	crack--vertical	PA of #18 shows a vertical line, but may or may not be crack.
2/18/2010	3	fract--vertical	vertical fracture #3
2/18/2010	5	fract--horizontal	O: #5 horizontal root fracture, needs ext
2/18/2010	5	fract--root	#5 oblique root fracture, nonrest
2/18/2010	5	fract--root	root fracture #5
2/18/2010	5	fx--vertical	Oblique root fx #5 with vertical defect.
2/18/2010	5	fx--root	61 yo male with #5 oblique Root fx, non restorable.
2/22/2010	2	fract--	Fractured #2 and 15 at the gum line.
2/22/2010	5	broke--	tooth #5 has distal margin broken down with a deep carious lesion.

Date	Tooth	Key-No-Yes	phrase
2/22/2010	5	broke-partial-	pt points to #5 which has deep carious lesion and is partially broken down.
2/23/2010	14	fract--	pt had plans to restore #14 but it fractured off and deemed non restorable by restorative dentist.
2/23/2010	14	fract--vertical	35 yo female with controlled HTN and carious #14 vertical fracture.
2/23/2010	5	fract--	fractured #5 to gum line with previous RCT.
2/23/2010	5	fract--	#15 crown fracture.
3/1/2010	28	fract--	#28,29 with caries and fractured crowns.
3/1/2010	28	fract--	3x1 radiopacity in max post right, #28,29 with frank caries and fractured crowns.
3/1/2010	29	fract--	#28,29 with caries and fractured crowns.
3/1/2010	29	fract--	3x1 radiopacity in max post right, #28,29 with frank caries and fractured crowns.
3/3/2010	19	fract--	fractured #19
3/5/2010	2	fract--	deep caries and fractured crown #2
3/5/2010	2	fract--	multiple carious lesions, #2 is severely carious with entire lingual wall and cusps fractured off to the gingival margin.
3/8/2010	2	fract--horizontal	32 year male with reversible pulpitis/possible horizontal root fracture #31, irreversible pulpitis #2
3/9/2010	21	broke--	During apPt Pt also expressed interest in discussing replacement of 21, which is broken down and unrestorable.
3/9/2010	31	fract--	buccal fracture of #31.
3/10/2010	13	broke--	Broken crown on #4 and #13
3/10/2010	13	broke--	broken crown #4, 13

Date	Tooth	Key-No-Yes	phrase
3/10/2010	13	broke--	broken crown #4, 13 : non restorable
3/10/2010	4	broke--	Broken crown on #4 and #13
3/10/2010	4	broke--	broken crown #4, 13
3/10/2010	4	broke--	broken crown #4, 13 : non restorable
3/11/2010	21	fx--	#10 and #21 fx to gumline, recommended implant placement, #18: non-restorable, discussed with pt risk vs.
3/12/2010	15	fract--	#15-B fracture.
3/12/2010	30	crack--	EXT #30 pain, unrestorable cracked
3/29/2010	13	fract--vertical	#13 Hopeless- vertical root fracture
3/29/2010	13	fract--vertical	Distal of #13 has a vertical root fracture.
3/30/2010	3	fract--	it was also discussed that #19 and #30 have crowns on them to protect the tooth structure and help them resist fracture before implants are placed.
3/30/2010	3	fract--vertical	#30 also needs to be evaluated for whether or not it has a vertical fracture (suspicious gingival recession on the buccal).
3/30/2010	31	fract--	Gross decay #31 and fracture of #4
3/30/2010	4	fract--	Gross decay #31 and fracture of #4
3/30/2010	4	fract--	#4 fractured with recurrent decay-->EXT
3/31/2010	14	fract--	Fractured #14
3/31/2010	3	broke--	#3 mesial broken
3/31/2010	3	broke--	#3 mesial half broken and causing pain - Ext
4/8/2010	12	fract--	fractured #12
4/9/2010	13	fract--	#13 crown is fractured.

Date	Tooth	Key-No-Yes	phrase
4/12/2010	3	fract--root	1 PA of #3 taken - PARL noted, possible fracture of MB root.
4/12/2010	3	fract--root	DX: root fracture #3 MB Rec.
4/13/2010	12	broke--	dental decay on multiple teeth, broken restorations, #6, 12 crowns have broken down due to decay, #18, 19 fractured cusps and sharp margins
4/13/2010	15	broke--	#15 draining fistula #32 broken filling
4/13/2010	18	broke--	dental decay on multiple teeth, broken restorations, #6, 12 crowns have broken down due to decay, #18, 19 fractured cusps and sharp margins
4/13/2010	19	broke--	dental decay on multiple teeth, broken restorations, #6, 12 crowns have broken down due to decay, #18, 19 fractured cusps and sharp margins
4/16/2010	5	fract--	Fractured #5
4/21/2010	20	fract--	gross caries, RCT, fractured teeth, fractured crown #20-non restorable, #4, 5, and 12 recommended for extraction, nonrestorable
4/21/2010	20	fract--	fractured crown #20-non restorable today, #4, 5, and 12 recommended for extraction, nonrestorable
4/22/2010	28	fract--	PPTC with fractured #28.
4/26/2010	19	fract--	IOE-caries #14-DL, #19-B, #20-B, abfraction #28, slight ledge on #29-B near crown margin, watch at every appt, xerostomia
4/28/2010	14	broke--	#2 and 14 broken down- non restorable.
4/28/2010	2	broke--	#2 and 14 broken down- non restorable.

Date	Tooth	Key-No-Yes	phrase
5/3/2010	29	fract--	Informed patient that the post and core on #29 would have to be removed, and since the post may cause fracture of the tooth when it is removed, the tooth may have to be extracted.
5/3/2010	30	fract--	severe crown fracture/decay #30, 31
5/3/2010	31	fract--	severe crown fracture/decay #30, 31
5/4/2010	19	broke--	Next time should eval pain in #19, and broken 31
5/5/2010	15	fract--	#15 Fractured distal
5/5/2010	2	crack--	PPD < 6mm Dr did exam findings 2 cracked this tooth is guarded with questionable prognosis , 3 needs occ patch, 5 needs occ patch and poss.
5/5/2010	2	fract--	NV: Eval #2 (fractured restoration/cusp)
5/5/2010	2	fract-amalgam-	Tx: Eval of #2 reveals fractured ML cusp adjacent to amalgam.
5/5/2010	2	fract--horizontal	PA of #2, mod horizontal bone loss coupled with fracture.
5/5/2010	31	fx--	#31 caries, fx, poor rest.
5/6/2010	2	broke--	Caries: #2 Buccal gingival at gumline, very deep under restoration, #3 MOB caries (broken rest), #14 OL, #19 Occl MB cusp tip, and #32 Occl repair.
5/6/2010	2	broke--	RTC: #2 Buccal overhang and caries, #3 MOB broken rest.
5/7/2010	19	fract-amalgam-	fractured DO amalgam #19 with caries
5/7/2010	30	fract--	Fractured #30
5/10/2010	3	broke--	A: broken tooth structure facial of #3.
5/12/2010	30	broke--	A: PFM #30 no present intraoral, severely broken down crown

Date	Tooth	Key-No-Yes	phrase
5/12/2010	30	fract-denture-root	P: maxillary denture wax try-in, adjusted and accepted by patient, PA and BW #30, dx is non-restorable endo treated #30 with crown and root fracture, discussed the need for extracting the tooth today
5/12/2010	30	broke--	nts of sore areas, intraoral exam reveals no ulcerations or redness maxillary edentulous, severely broken down crown #30
5/12/2010	31	broke--	Broken restoration #31 with caries
5/12/2010	31	broke-amalgam-	broken amalgam restoration #31, decay on #31, decay noted on several max anterior teeth
5/13/2010	14	fract--	A: abfractions #4 and #11, chipped porcelain buccal cusp #14
5/13/2010	14	fract--	O: PMH reviewed no changes, fractured off crown w/ pins, tooth structure and core build up inside, tissue overgrowth on lingual, 1 carp 1.8 cc 2 percent Lido w/ 1:100 epi local infiltration #14L, remo
5/13/2010	14	fract--	A: recurrent caries/ fractured crown #14
5/13/2010	18	broke--	Broken Crown #18
5/13/2010	18	broke--	#18 broken with sensitivity to percussion and palpation
5/13/2010	2	fract--	Fractured FPD #2-4.
5/13/2010	2	fract--	PFM bridge #2-4 is fractured so that it is sectioned between #3&4.
5/13/2010	2	fract--	pptc for revision of tx plan after fracturing fpd #2-#4.
5/13/2010	2	fract--vertical	A: vertical root fracture #14, poor prognosis for C:R ratio #2 (#2 had previous root amputation and currently has 1 root)

Date	Tooth	Key-No-Yes	phrase
5/13/2010	29	fract--	fractured off crown #29
5/13/2010	29	fract--	fractured symptomatic #29
5/13/2010	29	fract--	fractured crown #29
5/13/2010	31	broke--	Gross caries and Broken crown #31.patient elects extraction over RCT
5/13/2010	31	broke--	Gross caries & broken crown #31
5/13/2010	31	broke--	Broken Crown #31 and positive to percussion
5/19/2010	12	fract--	A- Fracture of crown on #12 down to gingival margin.
5/20/2010	19	crack--root	A: #19 had a crack on the D root
5/20/2010	19	crack--	Perio - #19 has been diagnosed as cracked and needs to be extracted.
5/21/2010	18	fract--	Tx: Clinical exam of #18 reveals limited tooth structure remaining from fractured restoration.
5/26/2010	19	fract--	carious #19 lingual cusps fractured TTP
5/27/2010	14	fract--	fracture #14
5/28/2010	14	fract--	Fractured 14, 19 and 30 with restorations in place but missing tooth structure.
6/1/2010	31	fract--	crown fracture #31
6/3/2010	31	fract--	caries and fracture #31
6/3/2010	31	fract--	33 yo female with caries #31 and fracture
6/3/2010	31	fract--	#31 fractured at DB
6/3/2010	31	broke--	Tooth #31 broken ref.
6/3/2010	31	broke--	O: #31 MODB amal, broken in two places and loose, upon removing amal caries is into chamber space to height of alveolus, sens to percussion, cold sens for 3 seconds, similar to adjacent tooth.

Date	Tooth	Key-No-Yes	phrase
6/3/2010	31	fract--	A: L decay on #31 and lingual cusps are now fractured into attachment but not off.
6/3/2010	31	fract--	fractured #31
6/3/2010	31	fract--vertical	16 yo AAM with vertical fractured #31
6/7/2010	3	fract--	fractured cusp #3DL
6/7/2010	3	fract--	fractured cusp DL #3
6/7/2010	5	fract--	#8 is grossly carious DF, #7 is grossly carious and the enamel is loose like a shell, #5 buccal cusp is fractured off to gumline.
6/8/2010	14	fract--	fractured and carious #14-nonrestorable
6/8/2010	28	fract--	#28 tender to fine touch class III mobility--> fractured crown due to caries
6/8/2010	28	fract--	51 yo female with fractured #28 due to caries
6/9/2010	29	broke--	Pt came cc teeth 29, 30, with broken and painful teeth.
6/9/2010	30	broke--	Pt came cc teeth 29, 30, with broken and painful teeth.
6/10/2010	12	fract--	fractured and carious crown #12
6/10/2010	12	fract--	fractured #12 restoration
6/11/2010	12	fract--	Tooth #12 fractured on lingual from occlusal surface to below gingiva
6/11/2010	12	fract--	fracture on tooth #12.
6/11/2010	12	fract--	Fracture and previous endo treatment of #12 may make extraction more difficult.
6/11/2010	12	broke--	S: PPTC for emergency evaluation of broken tooth #12 CC: "QUOTE"

Date	Tooth	Key-No-Yes	phrase
6/21/2010	13	fract--	#13 and #14 - extensive decay, fractured crowns, non-restorable
6/21/2010	13	fract--	Pt is asymptomatic but has extensive decay/fractured tooth structure #13, #14, and #30.
6/21/2010	14	fract--	#13 and #14 - extensive decay, fractured crowns, non-restorable
6/21/2010	14	fract--	Pt is asymptomatic but has extensive decay/fractured tooth structure #13, #14, and #30.
6/21/2010	14	fract--root	#14 crown fractured leaving 3 sectioned roots.
6/21/2010	31	fract--	#31 fractured DB cusp, #32 erupting
6/21/2010	31	fract--	fractured cusp #31
6/22/2010	19	crack--	Crack identified radiographically within the furcation of #19.
6/22/2010	19	fract--	fractured #19
6/22/2010	19	fract--	#19 endodontically treated with crown, fractured
6/22/2010	5	fract--	#15 Fractured distal
6/23/2010	18	fract--	#18 caries and fractured crown
6/23/2010	19	fract--	S: Pt presents to clinic for evaluation of "QUOTE", pointing to #19 fractured tooth.
6/23/2010	19	fract--	IOE: #19-fractured tooth, and + gingival inflammation in area, + parulis tract, + pain on palpation in area
6/23/2010	30	fract--	#30-fractured previous RCT
6/23/2010	31	fract--	#31 fractured cusp for a week.
6/23/2010	31	fract--	#31 unrestorable and fractured distolingual cusp
6/23/2010	31	fract--	unrestorable #31, Fractured distolingual
6/29/2010	2	fract--	Fractured #2/ Irreversible pulpitis

Date	Tooth	Key-No-Yes	phrase
6/29/2010	2	fract--	#2 Mesial marginal ridge is fractured off.
6/29/2010	2	fract--	#12 crown is fractured off.
6/29/2010	30	fract--	Fractured #30
6/29/2010	31	fract--	Caries/fractured #31
6/30/2010	12	fract--	#4 Fractured, #5 Abrasion, #12 Abfraction and severe mobility
6/30/2010	12	fract--	#4 Fractured, #5 Abfraction, #12 Abfraction
6/30/2010	18	fract--	#18 has a DB fracture, Gross Caries
6/30/2010	18	fract--	#18 Gross Caries and DB Fracture
6/30/2010	19	fract--	#19 - cervical decay, fractured DL crown
6/30/2010	4	fract--	#4 Fractured, #5 Abrasion, #12 Abfraction and severe mobility
6/30/2010	4	fract--	#4 Fractured, non-restorable.
6/30/2010	4	fract--	#4 Fractured, #5 Abfraction, #12 Abfraction
6/30/2010	5	fract--	#4 Fractured, #5 Abrasion, #12 Abfraction and severe mobility
6/30/2010	5	fract--	#4 Fractured, #5 Abfraction, #12 Abfraction
7/1/2010	15	broke--	my tooth broke off some more and is very sharp cutting my cheek points to #15
7/2/2010	14	fract--	Also discovered fractured margin on distal of 14 that needs replaced since tooth is causing him pain.
7/2/2010	28	fract--	Re-treatment of #28 in Grad Endo at no charge to the patient will be attempted with observation for fracture while under microscope.
7/6/2010	14	fract--	Fractured #14

Date	Tooth	Key-No-Yes	phrase
7/6/2010	3	broke--	New PA's and 4 BWs taken: #2 and 3 hopeless prognosis, #15 decay and broken DL and ML cusps.
7/6/2010	5	fract--	#5 fractured to slightly above gingiva,
7/8/2010	12	fract--	Fractured tooth #2 and 12
7/8/2010	2	fract--	O: #20 has abfraction lesion, attachment loss.
7/8/2010	2	fract--	Fractured tooth #2 and 12
7/8/2010	30	fract--	fractured #30, tender to palpation on buccal
7/8/2010	30	fract--	fractured/carious #30
7/8/2010	30	fract--	fractured #30
7/9/2010	18	fract--	fractured #18
7/9/2010	19	fract--	fractured #19
7/13/2010	2	fract--	Fractured crown #2, no other pathology noted
7/16/2010	15	fract--	fractured restoration #15
7/16/2010	3	broke-partial-	Adjusted partial and clasp #18 F 1/3 end broke during adjustment.
7/16/2010	30	fract--	fractured #30
7/19/2010	18	fract--	#18 fractured and possibly not restorable.
7/20/2010	30	fract--	fractured DL cusp #30
7/20/2010	30	fract--	#30 fractured
7/20/2010	30	fract--	PPTC with fractured #30
7/20/2010	30	fract--	fracture #30
7/23/2010	15	fract-amalgam-	15 decayed/missing filling, 18 lost amalgam filling and decayed, 30 large amalgam fractured on distal, #31 decay and needs to be extracted or RCT w/crown lengthening

Date	Tooth	Key-No-Yes	phrase
7/23/2010	5	broke--	tooth on UR is broken, pt points to #5
7/27/2010	28	fract-elevat-root	ext #28 fractured and had to elevate root tip out separately.
7/28/2010	14	fract--vertical	exam: missing #3, pd recorded on 2/25/10, only change on distofacial #14-12 mm pd, indication of vertical root fracture.
7/28/2010	14	fract--vertical	dx: vertical root fracture #14, missing #3.
7/28/2010	14	fract--vertical	A: vertical root fracture #14, poor prognosis for C:R ratio #2 (#2 had previous root amputation and currently has 1 root)
7/28/2010	19	fract--vertical	32 yo healthy m, presenting with pain from vertically fractured #19.
7/28/2010	19	crack--	crack line runs below gingival margin, and there is PAP on #19 visible on the panorex.
7/28/2010	19	fract--vertical	Vertical fracture on #19 on the mesiolingual cusp, fracture runs below gingival margin.
7/29/2010	20	fract--	76 yo f, presenting for extraction of #20 due to fracture.
7/29/2010	20	broke--	Broken and carious #20
7/30/2010	30	split--root	split with handpiece ext #30 roots separately, irrigated, gauze placed and hemostatic.
8/2/2010	30	fract-elevat-root	simple forcep ext of tooth #30, distal root fracture but elevated out separately.
8/5/2010	12	fract--	O: Tooth #12 L half fractured.
8/5/2010	15	fract--	#15 and 16 crown fractures
8/6/2010	31	fx-amalgam-	A: occlusal lesion on 31 appears connected to a recurrent lesion under MO amalgam which has existing decay on buccal and lingual and possible

Date	Tooth	Key-No-Yes	phrase
			fx in amalgam toward occlusal - tooth requires a core build
8/6/2010	31	crack-amalgam-	crack on DL of 31 - large MOB amalgam with recurrent decay and primary caries on unprepared O surface - removal of existing amalgam and recurrent decay results in pulp exposure
8/6/2010	31	crack--	pulp exposure during recurrent caries removal on 31 - explained risks and benefits and costs of RCT and crown treatment versus extraction - when presented with choice between RCT and crown or extraction
8/9/2010	15	broke--	New PA's and 4 BWs taken: #2 and 3 hopeless prognosis, #15 decay and broken DL and ML cusps.
8/10/2010	18	fract--	#18 dental caries with crown fracture,
8/12/2010	13	fract--	#13 large MOBL temporary restoration, buccal abfraction, portion of lingual cusp fractured off, no percussion or palpation sensitivity
8/12/2010	18	broke-elevat-root	Cut off bridge distal to #22 with straight diamond bur and high speed handpiece, elevated #18, crown broke off, removed root tips with cryer elevator.
8/13/2010	21	fract--root	#20 DL recurrent decay, #21 root caries and recurrent occlusal caries, #22 DLIF caries, #26 D caries, #28 fractured w/ occlusal caries.
8/16/2010	5	fract--	Fractured #5
8/16/2010	5	fract--	#5 fracture of crown to gum line
8/16/2010	5	fract--	non-restorable fracture #5
8/18/2010	5	broke--	5 Had a filling that broke off a couple of months ago.

Date	Tooth	Key-No-Yes	phrase
8/18/2010	5	fract--	Fractured lingual cusp to the gumline #5
8/18/2010	5	fract--	Lingual cusp of 5 fractured to gum line.
8/20/2010	13	fract--	Fracture on 13
8/20/2010	13	fract--	Buccal cusp fracture to gumline on 13 with decay.
8/23/2010	31	broke--	#31 - broken crown (distal half).
8/24/2010	30	fract--	caries and fractured #30
8/24/2010	30	fract--	#30 fractured and caries, radiolucency periapical
8/24/2010	30	fract--	fractured, caries #30
8/24/2010	30	fract--	#30 fractured 2 years ago, started to hurt 1 month ago.
8/24/2010	30	broke--	TREATMENT I COMMENTS: BP 175/84 P 64 Max rt bridge broken Pa's #30, 28, 5&6, 15
8/24/2010	30	broke--	RTO #28 b, evaluate broken bridge and ext #30
8/24/2010	31	fract--	fractured and caries #31
8/24/2010	31	fract--	fractured and caries #31, 1, 17
8/24/2010	31	fract--	#31 fractured and caries
8/24/2010	31	fract--	fractured, caries #31
8/24/2010	4	fract--	rampant caries, fractured #4 (mb cusp)
8/24/2010	4	fract--	Caries/fractured facial cusp #4
8/27/2010	4	fract--	fractured tooth #4
8/30/2010	31	fract-amalgam-	#31 has a large occlusal amalgam restoration with a fracture on the buccal.
9/1/2010	31	broke--	broke tooth in lower right (#31)
9/1/2010	31	broke--	broken crown/caries #31

Date	Tooth	Key-No-Yes	phrase
9/1/2010	31	broke--	#31 broken with gross decay- decay also noted on #s19 and 30 (pt informed)
9/1/2010	31	broke--	#31 broken with gross decay
9/3/2010	13	broke--	#13- 2 months pain, #22- broke a year ago
9/7/2010	29	fract--	fractured, carious #29
9/7/2010	29	fract--	grossly carious and fractured #29 with PAP, no other pathology noted, no lesions
9/7/2010	29	fract-partial-	partially dentate, attrition on remaining maxillary and mandibular teeth, mild buccal vestibule swelling adjacent to #29 with erythema, ttp, Fractured and carious #29, FOM soft, NT, NR, uvula midline,
9/8/2010	28	broke--	Broken down #28.
9/8/2010	28	fract--	carious, fractured #28
9/8/2010	5	broke--	#5 broken at gingival line, multiple areas of recession and prosthetic work, no other pathology noted.
9/9/2010	4	fract--	Tooth #4- carious decay, fractured crown, irreversible pulpitis.
9/9/2010	4	fract--	Tooth #4 gross carious decay, fractured crown.
9/9/2010	4	fract--	Tooth #4- gross carious decay, fractured crown.
9/13/2010	2	fract--	Tooth 2 shows complete buccal cusp fractures and decay.
9/14/2010	12	fract--	A: Abfraction lesion #12 and #13 buccal.
9/14/2010	14	crack--	large crack #14.
9/14/2010	14	crack--	can see crack #14 on PA
9/14/2010	14	fract--	fracture #14

Date	Tooth	Key-No-Yes	phrase
9/15/2010	12	broke--	rous temporary restorations that are breaking down, #3 has fractured/carious and is nonrestorable, #12 and 15 are broken below the gumline and are nonrestorable, #18, 19 have large cavitated carious l
9/15/2010	15	broke--	mporary restorations that are breaking down, #3 has fractured/carious and is nonrestorable, #12 and 15 are broken below the gumline and are nonrestorable, #18, 19 have large cavitated carious lesions.
9/15/2010	19	broke--	restorations that are breaking down, #3 has fractured/carious and is nonrestorable, #12 and 15 are broken below the gumline and are nonrestorable, #18, 19 have large cavitated carious lesions.
9/16/2010	19	fract--	#19 fractured crown/caries
9/16/2010	19	crack--	cracked off crown of #19 about 2 weeks ago, asymptomatic, poor prognosis/unrestorable, pt opts for ext
9/16/2010	19	fract--	carious/fractured #19
9/20/2010	28	fract--vertical	Dx: vertical root fracture #28, reduced periodontium, gingivitis, localized severe periodontitis (#30 - B and L).
9/21/2010	4	crack--	#4 had severe M caries and D crack that was detected with the transilluminator that goes subgingivally.
9/21/2010	4	crack--	A: #4 Irreversible pulpitis with symptomatic apical periodontitis/ Crack tooth.
9/21/2010	4	crack--	Patient informed about the questionable prognosis on #4 because of the crack on the distal.

Date	Tooth	Key-No-Yes	phrase
9/23/2010	18	fx--	#10 and #21 fx to gumline, recommended implant placement, #18: non-restorable, discussed with pt risk vs.
9/24/2010	18	fract--	Fracture ML cusp #18
9/24/2010	18	fract--	#18 has a fractured mesiolingual cusp with caries and existing restoration, tooth is sensitive to percussion but not palpation.
9/24/2010	31	fract--	A: Dx: Pulp Necrosis/Symptomatic Apical Periodontitis #31 with possible fracture.
9/30/2010	5	crack--vertical	DX: #5 Previously tx with Symptomatic apical periodontitis due to Cracked tooth/likely vertical fracture of palatal root.
10/4/2010	21	fract--	2 week ago angioplasty and stent placed, fractured #21
10/4/2010	21	fract--root	Impacted tooth apical to 18-19, and impacted tooth between roots of 20-21, 21 fractured on root
10/4/2010	3	broke--	Broken tooth on top right, points to #3
10/4/2010	3	broke--	Pt reports that broken tooth on top right (points to #3) started hurting severely last night.
10/8/2010	4	fract--	#4 has deep caries and D half is fractured
10/8/2010	4	fract--	consult in 11/2009 and was assigned to Dr in grad perio for implant placement in place of fractured/non-restorable #4.
10/12/2010	2	fract--	Fractured 2.
10/12/2010	2	fract--	Fractured symptomatic 2.
10/12/2010	21	fract--	The metal crown on #21 has fracture on occlusal and gross caries.

Date	Tooth	Key-No-Yes	phrase
10/14/2010	20	broke--	Medical history updated: pt recently broke left wrist/arm (9/20/10) and is currently in a cast.
10/14/2010	20	broke--	2003 pelvic floor collapse, 1996 broke arm after fell off chair, child birth, hernia, tonsillectomy, hysterectomy
10/18/2010	29	fract--	Fractured crowns on #29 and 30.
10/18/2010	29	fract--	Fractured #21, 29, and 30.
10/18/2010	30	fract--	Fractured crowns on #29 and 30.
10/18/2010	30	fract--	Fractured #21, 29, and 30.
10/19/2010	13	broke--	broken crown #13.
10/19/2010	13	fx--	PA also reveals previously endo treated #13 with a coronal fx.
10/19/2010	13	fract--	Clinically, Teeth #'s 11 and 13 coronally fractured.
10/21/2010	18	broke--	broken crowns teeth #s 2, 3,6, 7, 8, 9, 10, 11, 12, 13, 14, 15, 18, 19, 20, 21-30, all else WNL
10/21/2010	19	broke--	broken crowns teeth #s 2, 3,6, 7, 8, 9, 10, 11, 12, 13, 14, 15, 18, 19, 20, 21-30, all else WNL
10/21/2010	20	broke--	broken crowns teeth #s 2, 3,6, 7, 8, 9, 10, 11, 12, 13, 14, 15, 18, 19, 20, 21-30, all else WNL
10/21/2010	21	broke--	broken crowns teeth #s 2, 3,6, 7, 8, 9, 10, 11, 12, 13, 14, 15, 18, 19, 20, 21-30, all else WNL
10/21/2010	30	broke--	broken crowns teeth #s 2, 3,6, 7, 8, 9, 10, 11, 12, 13, 14, 15, 18, 19, 20, 21-30, all else WNL
10/21/2010	30	fract--	fractured #30 crown
10/25/2010	29	fx--	#29 unrestorable carious lesion without RCT, Crown #29 not in fxn.

Date	Tooth	Key-No-Yes	phrase
10/26/2010	29	broke-amalgam-	am patch appeared to be performed on previous recurrent decay under crown in '08, during removal of broken off crown/ amalgam #29 DB that was still attached, core build up came off and reveled signifi
10/26/2010	29	fract--	Tooth #29 fractured at the CEJ and lost crown, previously endo tx.
10/28/2010	13	broke-partial-	PPTC recall, update med hx, BP 110/53 pa 13 taken , cc broken tooth and loose partial, ultrasonic, handscale prophy pt can not remember all meds and did not fill out med hx prior to coming into clinic
10/28/2010	13	fract--	#13 crown has fractured off due to decay.
10/28/2010	13	fx--	Fx #13 needs EXT.
10/29/2010	14	fract--	O: Caries as charted, review of previous rads reveals fractured #J, pit and fissure caries of 14 and 19, smooth surface caries #H and M.
11/1/2010	12	fract--	g, FOM soft, nt,nr, no palatal drape, uvula midline, no i/o drainage, no ecchymosis, no step offs, #12 crown fractured and tender to palpation, no percussion sensitivity, all else WNL
11/1/2010	12	broke--	broken distal crown #12
11/1/2010	12	broke--	#12-broken crown -patient elects extraction over RCT and restoration
11/1/2010	12	broke--	#12-broken crown
11/1/2010	12	broke--	broken crown #12
11/4/2010	12	broke--	broken crowns teeth #s 2, 3,6, 7, 8, 9, 10, 11, 12, 13, 14, 15, 18, 19, 20, 21-30, all else WNL
11/4/2010	13	broke--	broken crowns teeth #s 2, 3,6, 7, 8, 9, 10, 11, 12, 13, 14, 15, 18, 19, 20, 21-30, all else WNL

Date	Tooth	Key-No-Yes	phrase
11/4/2010	14	broke--	broken crowns teeth #s 2, 3,6, 7, 8, 9, 10, 11, 12, 13, 14, 15, 18, 19, 20, 21-30, all else WNL
11/4/2010	15	broke--	broken crowns teeth #s 2, 3,6, 7, 8, 9, 10, 11, 12, 13, 14, 15, 18, 19, 20, 21-30, all else WNL
11/4/2010	18	fract--	Fractured #18
11/4/2010	21	fract--	Fractured #21
11/4/2010	21	fract--	fractured coronal structure of #21
11/4/2010	21	fract--	Coronal fracture of #21, part of restoration fractured as well
11/4/2010	3	broke--	broken crowns teeth #s 2, 3,6, 7, 8, 9, 10, 11, 12, 13, 14, 15, 18, 19, 20, 21-30, all else WNL
11/5/2010	15	fract-forcep-root	non surgical extraction 5 with 150 forceps - approx. 1mm palatal root tip fracture
11/5/2010	20	fract--	A: #20 crown fracture and decay.
11/5/2010	5	fract-forcep-root	non surgical extraction 5 with 150 forceps - approx. 1mm palatal root tip fracture
11/9/2010	14	fract--	#30 crown completely fractured off, #14 1/2 crown is missing.
11/9/2010	14	fract--	#14 M restoration fractured 3 weeks ago, #30 crown fractured 3 days later.
11/9/2010	14	broke--	Broken down crown #14 and #30.
11/9/2010	14	broke--	Broken crown and restoration #14 and #30.
11/9/2010	14	broke--	#14 and #30 crown broken down.
11/9/2010	3	fract--	A: fracture #3 DO caries
11/9/2010	3	fract--	A: fractured #3 DO, generalized plaque and calculus, watch #6 DL, #18 O, #11 marginal repair DLF, #20 marginal repair MLD,#5 survey crown for RPD

Date	Tooth	Key-No-Yes	phrase
11/9/2010	3	fract--	#3 fractured, #20 L redo defective margin, edentulous mandibular spaces.
11/9/2010	30	fract--	#30 crown completely fractured off, #14 1/2 crown is missing.
11/9/2010	30	fract--	#14 M restoration fractured 3 weeks ago, #30 crown fractured 3 days later.
11/9/2010	30	broke--	Broken down crown #14 and #30.
11/9/2010	30	broke--	Broken crown and restoration #14 and #30.
11/9/2010	30	broke--	#14 and #30 crown broken down.
11/11/2010	3	broke--	Broken #3
11/15/2010	31	fract--	Caries and fractured distal cusp on #31, and temporary filling on #2.
11/17/2010	15	crack--	#15 cracked tooth
11/17/2010	15	crack--	#15- cracked tooth that is nonrestorable.
11/17/2010	15	crack--	#15- cracked tooth that is nonrestorable
11/19/2010	5	fract--	51 yo female with fractured #28 due to caries
11/19/2010	5	broke--	She took in in 1995 and broke out in a sweat and fainted and woke up in an ambulance.
11/22/2010	4	broke--	Carious broken down #4 painful last 2-3 months
11/23/2010	13	fract--	Tooth #13 positive to transillumination with fracture noted mesial marginal ridge moving diagonally across occlusal surface to lingual aspect of DO composite.
11/23/2010	13	fract--	Re: consult for fractured #13 - pt reviewed Tx options with Dr and decided to pursue implant option due to questionable to poor prognosis.
11/29/2010	30	broke--	broken and decayed #30, mild vestibular swelling

Date	Tooth	Key-No-Yes	phrase
11/29/2010	30	broke--root	#30 had two D roots and DL root tip broke off which was retrieved after removing minimal interseptal bone with #8 round bur.
11/29/2010	31	broke--	Tooth 31 broken to gumline.
11/29/2010	31	fract--	#31crown fractured Aug 2010
11/29/2010	31	fract--	Oral exam wnl, except max tori, left mand tori, crown fracture #31, carious #1
11/29/2010	31	fract--	Fractured crown #31, caries #1-O
11/29/2010	4	fract--	During recementation of #4 with Panavia, a small piece fractured.
11/29/2010	4	fract--	A: Fractured post and core #4.
11/30/2010	13	fx--	DX: pptc w/ fx off d portion of #13 previously RCT'd on 10/6/09...
12/1/2010	12	broke--	pain when pt talks, sharp pain shoots through entire head upon biting, sharp pain on hot and cold, #12 broke about a week ago, #17 broke a couple years ago
12/1/2010	12	fract--	gross caries/fractured crown/symptomatic #12
12/1/2010	12	fract--	gross caries/fractured crown #12 - other tx options to save tooth were presented and pt elects to extract
12/1/2010	12	broke-elevat-root	extraction #12: crown fractured off, sectioned roots using handpiece and round bur and elevated out, buccal plate broke off, buccal gingiva incised, placed one 3.0 chromic gut suture through buccal gi
12/1/2010	12	fract--	caries, fractured crown, symptomatic #12
12/1/2010	30	fract--	white female presents upon referral from PP for evaluation of fractured 30.

Date	Tooth	Key-No-Yes	phrase
12/1/2010	30	fract--	A: Dx: generalized gingivitis on a reduced periodontium, fractured 30
12/2/2010	30	broke--	Decayed and broken crown #30 with periodontitis.
12/2/2010	30	broke--	Gross decay #30 and 31 with broken crowns
12/3/2010	14	fract--	Fracture on #14 MODL need PA to determine restorability.
12/3/2010	14	fract--	fractured #14.
12/3/2010	14	fract--	#14 has been fractured for 5+ years.
12/3/2010	19	fract--	fractured crown, grossly carious #19, pain started about a year ago, produces on and off shooting pains through lower left jaw, pain also provoked by cold and biting, no hx of swellings associated wit
12/3/2010	19	broke--	broken down distal #19, symptomatic to percussion
12/3/2010	19	broke--	linea alba left side, broken down distal #19, #19 symptomatic to percussion, fissured tongue, #1,3,and #16 carious, missing #2, no other pathology noted
12/3/2010	19	broke--	broken down distal #19
12/7/2010	14	fract--	Fractured tooth #14
12/7/2010	15	fx--root	A: Palatal root of #15 Fx.
12/7/2010	15	fract--root	PA #15 taken and fracture noted on Palatal or Distal root.
12/10/2010	31	broke--	#31 Broken buccal wall, caries, pulp exposed.
12/10/2010	31	broke--	#31 Broken tooth and caries
12/10/2010	31	broke--	#31 Broken tooth, requires RCT and crown, pt wants extraction

Date	Tooth	Key-No-Yes	phrase
12/10/2010	31	broke--	Tooth on LR (#31) broke two weeks ago and it has been painful since then.
12/14/2010	15	fract--	decayed and fractured #15
12/14/2010	15	fract--	grossly decayed and fractured crown #15.
12/14/2010	15	fract--	fractured and decayed #15
12/14/2010	18	fract--	#17 carious, #18 has distal fracture
12/14/2010	18	fract--	#18 distal fracture
12/14/2010	18	fract--	#18 distal caries and fracture
12/14/2010	2	fract-amalgam-	Removed existing amalgam restoration and excavated mesial caries from #12 (restoration was fractured in the mesial box w/recurrent caries).
12/14/2010	2	fract--	Pt called clinic and informed us that the crown of #20 has fractured.
12/14/2010	20	fract--	Pt called clinic and informed us that the crown of #20 has fractured.
12/14/2010	28	fx--	#28 fx at gum line but will try to save with RCT, post/core, crown.
12/14/2010	28	fract--	#28 with fractured crown.
12/23/2010	28	fract--root	#1 root tip, #2 fractured, #17 fractured, #28 fractured, #30 root tip
1/3/2011	31	broke--	Decayed #31, crown broken down
1/4/2011	18	broke--	broke 18 12/31/10 painful went to ER
1/4/2011	18	fract-partial-	Fractured/Carious buccal on 18, swollen and inflamed gingiva on lower left, partial erupted 17, 32
1/4/2011	18	fract--	Pain, fractured crown, caries #18

Date	Tooth	Key-No-Yes	phrase
1/5/2011	15	broke--	broken down crown #15.
1/5/2011	5	fract--	#5 fractured tooth (lost with PFM crown).
1/5/2011	5	fract--	Pt presents for eval--fractured crown #5 with previous pins placed for retention.
1/5/2011	5	broke--	Pt had tooth broke 2 months ago and is here to be evaluated for an implant at #5
1/5/2011	5	broke--	healthy 71 y F with broken #5.
1/6/2011	4	crack--	large crack #14.
1/6/2011	4	crack--	can see crack #14 on PA
1/6/2011	4	fract--	fracture #14
1/6/2011	4	fract--	A: Fractured lingual cusp #4.
1/6/2011	4	fract--	Clinical exam and diagnosed lingual fractured cusp #4.
1/6/2011	4	fract--	#4 fractured lingual cusp.
1/7/2011	18	fract--	Fractured crown #18
1/7/2011	2	broke--	#1,2,3 broken crown, gross caries
1/7/2011	3	crack--	cracked tooth #3
1/10/2011	14	fract--vertical	#14 Vertical fracture non restorable
1/10/2011	14	fract--	#14 Fractured tooth with irreversible pulpitis which is non restorable. Numerous other fractured/Carious teeth present.
1/10/2011	14	fract--vertical	#14 vertical fracture, Palatal cusp is fractured and mobile on palpation.
1/12/2011	3	fract--vertical	vertical fracture #3
1/13/2011	29	fract--	intra-oral: 27-28 normal to percussion, no perio > 3 mm; #29 slightly sensitive to percussion in buccal-lingual direction, 6-7mm narrow perio

Date	Tooth	Key-No-Yes	phrase
			pocket distal, PA indicates previously treated with long p
1/13/2011	29	fract--horizontal	A: #29 Horizontal root fracture with corresponding periodontal abscess
1/19/2011	18	fract--	#18 fractured and carious.
1/20/2011	13	broke--	O: #13 has comp core temp buildup that extends below gum with voids #31 temp restoration, tooth broken off to gum line, light calculus, generalized recession.
1/21/2011	14	fract--	Clinical exam: #14 fractured M-D.
1/21/2011	14	fract--	consult for fractured tooth 14.
1/21/2011	14	fract--	60 yo male eating peanut 3 days ago fractured #14.
1/25/2011	15	crack--	pt exhibits poor oral hygiene and rampant decay, #7 has large carious lesion (that pt is calling a crack) and the buccal cusps have fractured off due to a large buccal carious lesion on #15.
1/28/2011	19	fract--	#19 fractured crown
2/1/2011	20	fract--	Gross decay and crown fracture on #17, 20
2/7/2011	2	broke--	Broken Restorations #2, #7.
2/8/2011	2	fract--	A: #18 has fractured mesial with caries, #2 would need crown lengthening (very little coronal structure left), #3 has small caries on lingual.
2/8/2011	2	broke--	#2 is broken down tooth, recommended extraction, which pt agreed to.
2/8/2011	2	broke--	#2 short clinical crown with decay, has been broken down for months.
2/8/2011	2	broke--	carious #2 broken down crown

Date	Tooth	Key-No-Yes	phrase
2/8/2011	2	broke--	#2 broken down crown with caries
2/8/2011	2	broke--	#2 broken down crown with decay, short clinical crown
2/8/2011	5	fract--	Abfractions #2,3,14,15.
2/9/2011	4	fract--	Fractured tooth #4 unrestorable and missing tooth #13, all other WNL
2/9/2011	4	fract--	Fractured tooth #4
2/9/2011	4	fract--	Fractured cusp #4L
2/9/2011	4	broke--	broken #4 non-symptomatic.
2/11/2011	20	fract--	Gross decay and coronal fracture #20.
2/11/2011	3	broke--	Gross caries and broken down #3
2/14/2011	28	fract--root	EXT root tips of #7, 18, 20, 28 (fractured crown), 29, 32.
2/14/2011	28	broke--root	Root tips of #7, 18, 20, 28 (broken down crown), 29, 32 remain
2/14/2011	28	fract--root	Dental: Root tips of #7, 18, 20, 28 (fractured crown), 29, 32 remain.
2/14/2011	29	fract--root	EXT root tips of #7, 18, 20, 28 (fractured crown), 29, 32.
2/14/2011	29	broke--root	Root tips of #7, 18, 20, 28 (broken down crown), 29, 32 remain
2/14/2011	29	fract--root	Dental: Root tips of #7, 18, 20, 28 (fractured crown), 29, 32 remain.
2/15/2011	14	fract--	Sig findings: fibroma in LR buccal mucosa, PAR of #19, crown fractured to gumline and decay on #5, 14.
2/15/2011	14	fract--	non restorable #14, fracture of crown #5

Date	Tooth	Key-No-Yes	phrase
2/15/2011	29	fract--	#29 fractured and has symptomatic apical periodontitis.
2/15/2011	5	fract--	Sig findings: fibroma in LR buccal mucosa, PAR of #19, crown fractured to gumline and decay on #5, 14.
2/15/2011	5	fract--	non restorable #14, fracture of crown #5
2/15/2011	5	fract-amalgam-	#5 has fractured crown with retained amalgam core material- no pathology noted from 3-3-08 radiograph.
2/16/2011	12	crack--	Pt states that his upper left tooth (pt points at #12) cracked about two years ago and was sensitive to cold at that time.
2/16/2011	12	crack--	IOE reveals cracked tooth mesiodistally #12.
2/16/2011	12	crack-amalgam-	Performed comprehensive exam: cracked tooth #12, caries #13 occl, large amalgam restoration #18, fractured crown #31, generalized plaque accumulation.
2/16/2011	12	fract--vertical	limited bleeding on probing, mild deposits of supragingival plaque and calculus, fair oral hygiene, #12-horizontal and vertical fracture.
2/16/2011	12	fract--	periapical radiographs and bwxs reviewed: healthy bone levels, #12-periapical pathology noted, as well as fracture.
2/16/2011	12	fract--	DX and PX: #12-hopeless due to fracture.
2/22/2011	12	fract--	"annoying, and lately my gums around the tooth are sore when I brush my teeth." Upon inspection, #12 appears to have fractured into buccal and lingual halves (each segment is mobile independent of t
2/22/2011	12	crack--	Cracked/hopeless tooth 12

Date	Tooth	Key-No-Yes	phrase
2/22/2011	12	fract--	Loss of intra-coronal tooth structural on tooth 12, class 3 fracture running MD through center of tooth
2/22/2011	19	broke--root	/ML root caries with class III mobility, 8DL/ML root caries, 9 DL root caries, 10DF root caries, 11 broken at gumline/RCT need to be retx, 12 O/F/L/D root caries, 19 D interprox caries.
2/23/2011	14	fract--	Cariou tooth #14 with fractured cusp.
2/23/2011	15	broke--	#15 broken endo tooth.
2/23/2011	15	fract--	Patient states approx two months ago she fractured the crown of #15 which her dentist attempted to place a restoration without success due to li
2/23/2011	15	broke--	eval for ext upper left #15 broken
2/23/2011	2	broke--	Severely broken and carious #2
2/23/2011	2	broke--	2) #2- Majority of the crown has broken off, soft tissue is growing in coronal area of fracture- Non-restorable
2/23/2011	2	broke--	3) Severely broken and carious #2
2/23/2011	2	broke--	3) Moderate to Severely Broken teeth (#15 and #2)
2/23/2011	2	fract--	#2 Crown was fractured severely.
2/23/2011	31	crack--	P- Review med hx, Limited oral exam- head and neck exam, PA #31, Endodontic Testing, #31 unrestorable due to internal resorption and lowered prognosis due to mesial and distal cracks if NSRCT, post and
2/25/2011	19	crack--	60 yo pt of record seen in predoc clinic presented with #19 DOL missing and tooth cracked.

Date	Tooth	Key-No-Yes	phrase
2/25/2011	19	crack--	#19 (previously endo-treated) cracked M-D, both B and L portions mobile
2/25/2011	19	crack--	#19 (previously endo-treated) cracked M-D.
2/25/2011	19	crack-amalgam-root	A: #19 (previously root canal treated) existing amalgam DOL missing, tooth cracked M-D, both pieces mobile.
2/25/2011	19	crack--	P: Examined #19 - tooth cracked, both B and L portions mobile.
2/25/2011	30	fx--	of #30 due to occlusal fxn on pt right side.
2/28/2011	4	fract--	neralized plaque and minimal calculus, crown margin for #7 defective with possible caries leakage, #4 never had permanent restoration placed after NSRCT that was completed here years ago- temporary re
2/28/2011	4	fract--	Crown of previously endodontically treated #4 fractured at gum line- Ellis Class III
2/28/2011	4	fract--	#4 previously endodontically treated with Ellis Class III fracture
2/28/2011	4	fx--	#4 unrestorable endo tx with crown fx
3/1/2011	19	fract--	crown fracture #19
3/1/2011	19	broke--	#19 broken off at gum line.
3/1/2011	31	fract--	DE - Dr- chip on DI #7, lost crown #31 - recemented with Tempbond NE, recommend perio eval prior to placement of new crown - noted mobility of recemented crown, there is a hole on O surface and
3/2/2011	13	fract--	Fractured #13
3/2/2011	13	fract--	Fractured #13 wants extracted

Date	Tooth	Key-No-Yes	phrase
3/3/2011	18	fract--root	EXT root tips of #7, 18, 20, 28 (fractured crown), 29, 32.
3/3/2011	18	broke--root	Root tips of #7, 18, 20, 28 (broken down crown), 29, 32 remain
3/3/2011	18	fract--root	Dental: Root tips of #7, 18, 20, 28 (fractured crown), 29, 32 remain.
3/3/2011	20	fract--root	EXT root tips of #7, 18, 20, 28 (fractured crown), 29, 32.
3/3/2011	20	broke--root	Root tips of #7, 18, 20, 28 (broken down crown), 29, 32 remain
3/3/2011	20	fract--root	Dental: Root tips of #7, 18, 20, 28 (fractured crown), 29, 32 remain.
3/7/2011	12	broke--	Tooth 12 badly broken down, no other significant soft tissue findings
3/9/2011	5	fract--	fractured #5 on distal.
3/9/2011	5	broke--	distal marginal ridge broke off of #5.
3/10/2011	13	broke--	broken down and painful #13 and #14
3/10/2011	14	broke--	broken down and painful #13 and #14
3/10/2011	20	fract--	fractured distal portion of #20.
3/10/2011	30	fract--	30 crown fracture, unrestorable, acute apical periodontitis
3/10/2011	31	fract-amalgam-	#31- fractured amalgam restoration, fractured DMR
3/10/2011	31	broke--	#31- broken filling, restorable, explained to patient restorability options, patient elects to have #31 ext.
3/10/2011	31	broke-amalgam-	#31- broken amalgam, patient elects ext
3/11/2011	18	broke--	18, 31, 32 broken down.

Date	Tooth	Key-No-Yes	phrase
3/11/2011	31	broke--	Tooth broke, points to tooth #31..
3/11/2011	31	broke--	18, 31, 32 broken down.
3/11/2011	4	fract--	fractured restoration #3 & #4 with recurrent decay
3/11/2011	4	fract--	pt cannot point to a specific tooth that hurts, but knows that two teeth are fractured (#3,4)
3/14/2011	5	fract--	fractured and infection #5
3/14/2011	5	broke--	reports tooth #5(pointed to it) has been broken for a long time and now is starting to really hurt
3/14/2011	5	split--	5 split into buccal and palatal halves.
3/15/2011	2	fract--	Caries #2 non-restorable and fractured,
3/15/2011	2	fract--	Caries #2, non-restorable and fractured
3/17/2011	30	crack--	Isolated 9mm probing on the DL of #30 (Possible crack).
3/21/2011	12	fract--	fractured #12 non restorable.
3/21/2011	12	fract--root	Coronal fracture tooth #12, Root remaining.
3/21/2011	30	fract--	Buccal fracture #29, Pain on percussion and palpation #30.
3/23/2011	19	fract-elevat-	Minor tooth movement to elevation and crown fracture necessitated surgical extraction of #19 w/ buccal flap and aveloplasty.
3/23/2011	5	fract--vertical	Explained to patient that #5 may have vertical fracture and due to PAP will require RCT and crown.
3/23/2011	5	crack--	NV: #5 endo access (determine extent of crack and if subgingival --> EXT)
3/23/2011	5	crack--	p: #5: has MD crack and it is hopeless.

Date	Tooth	Key-No-Yes	phrase
3/25/2011	3	fract--	Multiple carious teeth - #3 -fractured tooth and restoration, recurrent decay
3/25/2011	3	fract--	1) - fractured crown on #3 w/ recurrent decay - explained restorative options, and patient elected extraction.
3/30/2011	20	fract-porcelain-	Fractured porcelain at distal cusp of pontic of FPD #18-20.
3/30/2011	20	fx-porcelain-	A: Fx porcelain of pontic #18-20 bridge otherwise intact and non carious; No need to replace bridge at this time
3/30/2011	20	fract--	#20 fractured below gumline with caries on all surfaces and exposure of nerve.
4/4/2011	31	fract--	A: Fractured and carious #31.
4/5/2011	3	fract--	#3 severely carious fractured crown
4/5/2011	3	fract--	#3 severely carious fractured crown - extract
4/5/2011	3	fract--vertical	Extraction of roots #3 and vertically fractured #4.
4/5/2011	3	fract--	#3 crown fractured off months ago, asymptomatic
4/5/2011	4	fract--vertical	#4 vertical root fracture w/ irreversible pulpitis - sensitive to percussion and pressure
4/5/2011	4	fract--vertical	#4 vertical root fracture w/ irreversible pulpitis - sensitive to percussion and pressure - pt elects to extract
4/5/2011	4	fract--vertical	Extraction of roots #3 and vertically fractured #4.
4/5/2011	4	crack--	pain on #4, 4 is cracked due to decay.
4/7/2011	3	fract--root	Buccal draining fistula #3 opp MB root approx 4.0 mm in diameter, mesio-distal fracture #3 (endodontically treated tooth restored with resin) with entire buccal of crown mobile.

Date	Tooth	Key-No-Yes	phrase
4/7/2011	3	fx--	Likely non-restorable fx crown #3..Referred for eval to oral surgery and extraction if indicated.
4/7/2011	3	crack--	diabetes, htn, knee replacement in feb, cracked tooth 3,
4/7/2011	3	crack--	#3 was discovered to have a crack by student yesterday during cleaning radiograph shows PAP and visible abcess on B mucosa
4/8/2011	19	fract--	#19 Fractured lingual cusp that extends subgingivally
4/8/2011	19	fract--	Non-restorable subgingival fracture #19.
4/8/2011	19	fract--vertical	#19 vertical crown fracture that clinically extends subgingivally.
4/11/2011	30	broke-amalgam-	#30 MODBL amalgam restoration broken on buccal.
4/11/2011	30	fract--	48 yo male with fractured tooth #30, pt stated tooth fractured several weeks ago, is not currently causing problems.
4/11/2011	30	fract-amalgam-	Fractured tooth #30, large amalgam restoration with defect on mesial of #30
4/11/2011	30	fract--	3 mm x 3 mm lesion on right lateral tongue, whtie, non painful, appears traumatic from fractured tooth #30, no other pathological findings
4/12/2011	29	fract--	Originally thought an implant crown had come off, but the pt presents with a noncomplicated crown fracture #29.
4/12/2011	29	fract--	#29 horizontontally fractured to the level of the gingiva, caries noted.
4/12/2011	29	fract--	black male presents upon referral from AEGD for eval and tx plan re: #29, which is fractured off at the gumline.

Date	Tooth	Key-No-Yes	phrase
4/12/2011	29	fract-partial-	A: Dx: fractured #29 due to caries, partial edentulism
4/13/2011	3	fx--	of #30 due to occlusal fxn on pt right side.
4/14/2011	19	fx--	Caries with crown fx #19.
4/18/2011	14	fract--	Fractured tooth #14
4/18/2011	18	fract--root	root tip #28, multiple decayed and missing teeth, tooth #18 fractured into pulp, no other pathology
4/18/2011	18	fract--	hypertensive-newly diagnosed , will monitor BP, gross decay, fractured #18 and patient desires to have tooth removed after given options of rct, crown length, cbu, and crown or ext.
4/18/2011	18	fract--	fractured tooth #18, multiple other decayed and fractured teeth
4/18/2011	31	fract--	Tooth #31 has a large fracture and a temp filling is showing
4/18/2011	31	fract--	RCT treated #31 with temp filling and fracture
4/18/2011	31	fract--	#31 failed endo due to fracture and temp filling
4/19/2011	21	fract--	es control to ODCT and keep original RPD - not recommended because torque would potentially lead to fracture of #21 & 22
4/19/2011	28	broke--	#28 broke off at level of bone
4/19/2011	28	fract--	PA - #28 -caries/fractured, #27 large carious lesion
4/25/2011	31	broke--	DE: recurrent decay 19 L under crown margin, 31 broken down crown has fallen of and needs ext, 28 leakage around composite margin
4/25/2011	31	broke--	#31 broken down, previous treated with crown
4/25/2011	31	fract--	Fractured tooth #31

Date	Tooth	Key-No-Yes	phrase
4/25/2011	5	fract--	Extraction of fractured #5
4/25/2011	5	fract--	#5-fractured crown with previous RCT
4/25/2011	5	fract--	Fractured #5/non restorable
4/25/2011	5	fract--	abfraction areas #5,6,8,9,11,12,13
4/25/2011	5	fract--	Radiographs reveal possible fracture of #5
4/26/2011	18	fract--	Fractured tooth, Non-restoreable #18
4/26/2011	29	fract--	deeply carious tooth #29, crown fracture
4/26/2011	29	fract--	RCT performed on tooth #29, #30, Crown fracture on tooth #29 as well as deep caries present.
4/26/2011	29	fract--	Dental: Frank carious lesions, RCT #29,#30 along with crown fracture tooth#29
4/27/2011	19	fract--	Fractured #19.
4/27/2011	19	fract--root	fractured #19 (mesial and distal roots remaining), no hard tissue pathology.
4/27/2011	19	fract--	Fractured #19: asymptomatic, pt interested in ext, socket preservation, and implant.
4/28/2011	5	fract--	PT phoned me over the weekend reporting that since his last visit he experienced a fracture to tooth #5.
4/29/2011	20	fract--root	Abfraction lesion noted #14-B, severe bone loss and root caries #20, caries #21-DB, abfraction #29 and #28 buccal.
5/3/2011	30	fract--	DE: Dr notes porcelan fracturs #4 M, suggests that patient is refered to perio for 8-9 mm PD on 30 DB and 8 mm PD 31 M
5/5/2011	20	fract--	#17 gross caries, #20 gross caries, #18 fractured restoration, 28 y/o female history of hypertension and hypothyroid

Date	Tooth	Key-No-Yes	phrase
5/5/2011	20	fract--	#17 gross caries, #20 gross caries, #18 fractured restoration
5/5/2011	31	fract--	#31 fractured subgingivally, percussion sensitive
5/6/2011	30	crack--	P: Palpation/percussion 18-20,28-31 Neg Tooth sleuth only painful on #31-ML cusp neg on 29-30, #31-D appears to have crack in D marginal ridge not symptomatic, Slight red area <1mm on lingual gingiva
5/6/2011	30	fract--	S: PPTC for POE and adult prophy, CC"QUOTE" HPI Pt came in 6/15/10 with biting sensitivity on 30 PA taken then and differential diagnosis of fractured tooth/furcation involvement made.
5/6/2011	30	fract--root	O: BP 158/98 HR 80R, 2x2mm redish ulcer with hyperkarotic ring Distal to #2, exposed and fractured root on DB of 30, radiographic change in 30 from 6/15/10 to today has been rapid with boney destructi
5/9/2011	3	broke--	patient points to tooth #3, says it broke a few days ago.
5/10/2011	19	fract--	Grossly decayed and fractured #19
5/11/2011	15	crack--	#15 - Cracked tooth - non-restorable
5/11/2011	15	crack--	Tooth #15 is cracked down to nerve of tooth.
5/11/2011	15	crack--	#15 Ext, cracked tooth not restorable
5/11/2011	15	crack--	Tooth #15 is cracked down to nerve of tooth - nonrestorable.
5/11/2011	29	fract--	#29 fractured at the gingiva.
5/11/2011	29	broke--	broken restoration #29
5/11/2011	29	broke--	broken restoration with caries #29

Date	Tooth	Key-No-Yes	phrase
5/12/2011	30	fract--	Pt is asymptomatic but has extensive decay/fractured tooth structure #13, #14, and #30.
5/12/2011	30	fract--	Missing teeth, #30 Fractured restoration
5/12/2011	30	broke--	Severely broken down tooth #30.
5/12/2011	30	fract--	#30 Fractured , Pt elects to ext
5/13/2011	30	fract--	Tooth #30: fractured to the gingiva (pt reports history of NSRCT, repeated fractures, discomfort, and recommendation for ext by restoring dentist)
5/16/2011	28	broke--	broken down #27 and #28
5/17/2011	19	fract--	fracture buccal cusps tooth #19 with carious extending cervically.
5/17/2011	19	fract-elevat-root	surgical extraction of tooth #19, attempted elevation, crown fractured, tooth sectioned m/d, root removed as atraumatically as possible.
5/17/2011	19	fract--	46 yo female with HTN, Asthma, Heart palpitations, Sleep apnea, Acid Reflux, DM presents with fractured tooth #19.
5/19/2011	12	broke--	#12 broken down
5/19/2011	12	fract--	e Pt sustained facial and dentoalveolar trauma including lip laceration, avulsion of #9 and 11, and fracture of #12 on March 13, 2011 when she was hit in the face with a champagne bottle.
5/19/2011	12	broke-elevat-	A crestal incision made for broken down tooth #12, tooth elevated atraumatically, socket irrigated.
5/19/2011	29	crack--	#29 filling fractured and tooth is cracked mesial distal
5/19/2011	29	crack--	#29 tooth cracked

Date	Tooth	Key-No-Yes	phrase
5/31/2011	12	crack--	RAD: #12 cracked
5/31/2011	12	split--	#12 Split segment removed to 1mm below bone.
5/31/2011	12	fract--	pt indicates that he fractured #12 approx 2m ago - no pain associated with #12 at this time.
5/31/2011	12	fract--	pt interested in implant to replace #12 - deemed unrestorable due to fracture (see above).
5/31/2011	12	broke--	Patient reported having CT scan earlier this morning for broken #12 for planned implant.
5/31/2011	15	broke--	broken down carious #15.
5/31/2011	3	broke--	DE: performed by Dr performed dental exam and noted fx filling #29 and broken filling #30, she also advised a perio referral for #3 to have the mucogingival defect evaluated.
5/31/2011	3	fract--horizontal	Radiographs: DB root has horizontal root fracture on 3.
5/31/2011	3	fract--	Fractured restoration #30DO.
5/31/2011	30	fract--	When #30 becomes symptomatic again, it is recommended to extract the tooth or if the patient desires we will perform an exploratory surgery to confirm presence of fracture.
6/1/2011	15	crack-amalgam-	- #15 is asymptomatic, but amalgam core buildup is failing and the enamel walls are cracking.
6/1/2011	31	fract--	Gross decay and severe fracture of #31
6/1/2011	31	fract--	1) Severely fractured and grossly decay of #31.
6/1/2011	31	fract--	Coronal fracture and gross decay of #31.
6/6/2011	13	fract--root	pt charting updated - root tip #3 + fracture #13 (no other restorative needed)
6/6/2011	13	fract--	crown fracture #13

Date	Tooth	Key-No-Yes	phrase
6/6/2011	13	fract--	Crown fracture #13
6/6/2011	13	fract--root	crown fracture #13 non-restorable,root 3
6/6/2011	13	fract--	fractured tooth #13, fractured restoration tooth #14.
6/6/2011	3	fract--root	pt charting updated - root tip #3 + fracture #13 (no other restorative needed)
6/6/2011	3	fract--	crown fracture #13
6/6/2011	3	fract--	Crown fracture #13
6/6/2011	3	fract--root	crown fracture #13 non-restorable,root 3
6/7/2011	5	fract--root	Perio consult Dr confirmed the tooth #5 has a root fracture.
6/14/2011	31	broke-partial-	O: no facial swelling, no palpation sensitivity, tooth #31 sensitive to percussion, temporary crown is partially broken, calculus on the lingual of #31, lingual gingival is inflamed, BOP.
6/15/2011	19	fract--	19 has a fracture to the furcation.
6/15/2011	19	fract--	#3 incomplete endo treatment with temporary filling missing, #19 Fractured and very sensitive to percussion
6/15/2011	3	fract--	#3 incomplete endo treatment with temporary filling missing, #19 Fractured and very sensitive to percussion
6/16/2011	31	fract--	#31 lingual fracture and caries.
6/20/2011	30	fract--	#30 caries/fracture
6/20/2011	30	fract--	#30 Carious crown fracture
6/20/2011	30	fract--	#30 crown fracture w/ caries.
6/20/2011	4	broke--	A: #4 crown broken off subgingivally.

Date	Tooth	Key-No-Yes	phrase
6/22/2011	18	fract--	Pt is aware, however, that with this restoration acting as the definitive treatment for #18, there is a chance that the tooth could fracture.
6/22/2011	18	fract-amalgam-	At pt's last visit, complex amalgam placed #18, but the mesial marginal ridge fractured during occlusal adjustment.
6/22/2011	18	fract--	Fractured #18 nonrestorable
6/22/2011	18	fract--	Fractured and periodontally compromised #18
6/22/2011	18	fract--	fractured #18
6/22/2011	18	crack--	Cracked tooth #18 2 weeks ago.
6/24/2011	19	fract--	#19 gross decay and distal fracture.
6/27/2011	14	fract--	exam reveals that #14 PFM fractured at gingivia.
6/27/2011	14	fract--	#14 -cariou fracture
6/27/2011	18	fract-amalgam-root	IOE - #18 existing MOL amalgam w/ fractured ML cusp, extending down along the root.
6/27/2011	18	fract--	She was seen by UG recently for a fractured cusp on #18 which will need CRLN sx.
6/27/2011	19	fract--	Cariou lesion on #19, cariou fracture on #13.
6/27/2011	3	fract--	MOL restoration fractured on #3
6/30/2011	31	fract--	Evidence of bruxism with genearlized wear facets and fractured restorations #29,30,31.
7/1/2011	4	fract--	fractured tooth #4 due to gross decay
7/1/2011	4	fract--	Fractured #4 due to gross caries
7/5/2011	13	fract--	S: patient reports concern about #fractures of tooth sturcture or restoration: 13, 20, 30.
7/6/2011	30	fract--	fractured DB cusp #30, Fractured lingual cusp #5, Fractured DL cusp #15.

Date	Tooth	Key-No-Yes	phrase
7/6/2011	30	fract--	Gross decay on #30 with a fractured DB cusp and PA radiolucency.
7/6/2011	30	fract--	Gross caries and fractured cusp #30
7/6/2011	30	broke--	My broken tooth hurts (points to 30)
7/7/2011	20	fract--	#20 has fractured restrotaion and diagnosed with irreversible pulpitis.
7/7/2011	20	fract--	#20 has fractured restoration sensitive to percussion
7/8/2011	15	fract--	Tooth #15 is fractured due to gross caries.
7/8/2011	15	fract--	Fractured #15 due to gross caries
7/14/2011	28	fract--	fractured #28
7/18/2011	5	broke--	26 yom presents with broken tooth #5 with sensitivity to cold.
7/18/2011	5	crack--	Pt thinks he cracked it about 1.5 weeks ago while eating.
7/18/2011	5	split--	split tooth #5, perio probings of 8-10mm on both sides, inflammation around the mesial and distal of tooth 5, sensitive to percussion,
7/18/2011	5	fract--vertical	vertical fracture on tooth #5
7/18/2011	5	split--	pt has controlled HTN, is being medicated for diabetes type 2, and has high cholesterol, tooth #5 is split and non restorable
7/18/2011	5	split--	split tooth #5
7/19/2011	13	crack--	A-PPTC with cracked tooth #13, clinically visible, the crack runs from the mesial wall to the distal wall along the lingual aspect of an exisiting occlusal composite restoration

Date	Tooth	Key-No-Yes	phrase
7/19/2011	13	crack--	P- Med Hx updated, tooth #13 tested for cracks: tooth sleuth yielded pain on bite release on buccal and lingual cusps, transillumination showed a visible crack running in the mesial/distal direction t
7/19/2011	13	fract--vertical	PPTC upon referral from UG for evaluation of implant #13 which had been dx with a vertical fracture and deemed non-restorable.
7/20/2011	14	fract--	Tooth 14 fractured and symptomatic
7/20/2011	14	crack--	Pt has c/o occasional pain when brushing UL (#14 previously diagnosed as having a crack in the floor of th epulp chamber at time of RCT)
7/20/2011	14	crack--root	Crack visualized originating from Mesial marginal ridge of #14 and progressing apically over Mesiobuccal root.
7/20/2011	14	fract--root	A: #14 non-restorable root fracture with localized severe chronic periodontitis.
7/20/2011	14	fract--	Fractured #14 with hopeless prognosis.
7/20/2011	19	broke--	/77, cc pt thinks she may have lost a filling, ultrasonic, handscale, pro , ocs,h and n wnl, pt has broken d marg ridge 19 and has questionable areas 2.o and 3 o (Dr out) , willl have pt return
7/20/2011	19	fract--	O: PROBLEM FOCUSED EXAM/ MED-DENT HX REVIEWED W NO APPARENT or OBVIOUS CONTRAINDICATIONS TODAYS TX/ 1PA/ CLINICAL and RADIOGRAPHIC EXAM REVEALS #19 DISTAL/TOOTH FRACTURE (endo performed 10+ years ago)
7/20/2011	19	fract--	O: Reports NCMH/ Problem focused emergency exam + 1 PA/ #19 there is a crown fracture of the margin of previously endodontically treated tooth

Date	Tooth	Key-No-Yes	phrase
			and recently crown core (TYCOR) with exposed metal-acryli
7/20/2011	19	fract--	A: Fractured facial wal #19 / guarded prognosis for restorability/ radiograph not appreciably different from initial exam PAI
7/21/2011	4	fract--	Coronal fractures 4, 5
7/21/2011	5	fract--	Coronal fractures 4, 5
7/25/2011	2	broke--	tooth #12 broken down to gingival level, missing teeth
8/1/2011	30	broke--	number 30 broken off crown
8/2/2011	15	fract--vertical	#15 vertical fracture, non-restorable.
8/2/2011	18	fract-forcep-	#18 crown fractured with forceps
8/2/2011	19	fract--	Fractured #19
8/3/2011	18	fract--	Fractured #18
8/9/2011	4	fract--	#4 fractured
8/12/2011	12	broke--	gross caries and severe broken teeth 8,11,12,13,14,1-27 and 29, teeth 8,11,12,13,14 hardly visible
8/12/2011	13	broke--	gross caries and severe broken teeth 8,11,12,13,14,1-27 and 29, teeth 8,11,12,13,14 hardly visible
8/12/2011	14	broke--	gross caries and severe broken teeth 8,11,12,13,14,1-27 and 29, teeth 8,11,12,13,14 hardly visible
8/12/2011	4	fract--	Fractured lingual cusp #4 with caries, #20 recurrent caries B near crown margin, #30 recurrent caries B.

Date	Tooth	Key-No-Yes	phrase
8/12/2011	4	fract--	, Face/lips -, TMJ -, I/O: Buccal musosa -, palate-, FOM -, tongue -, Fractured restoration #13 D, fractured tooth #4 with only buccal cusp remaining of crown.
8/12/2011	4	fract--	Teeth #13 and 4 are fractured.
8/12/2011	4	broke--	Talked to pt about the need to ext #4 as it was severely broken down.
8/12/2011	4	fract--	nctive therapy in treatment of heart failure (afterload reduction); treatment of acute myocardial infraction within 24 hours in hemodynamically-stable patients to improve survival; treatment of left v
8/12/2011	4	broke--	Tooth #4 presents as an asymptomatic fractured tooth broken off at the gingival margin.
8/12/2011	4	fract--	#4 Fractured tooth
8/15/2011	19	fract--	fractured #19
8/17/2011	4	fract--	Upon eval, noticed fracture of #4 from mesial to distal.
8/17/2011	4	fract--	IOE: #14 fractured distal margin, #29 overhang of composite with recurrent caries.
8/17/2011	4	fract--	Fracture of D surface of #14 with recurrent caries present.
8/17/2011	5	fract--	#5-radiograph shows mesial fracture line and concurrent pd of 9mm, diagnosis-fracture from post, non restorable
8/19/2011	2	crack--	#2 is cracked.
8/23/2011	12	fract--	Coronal fractures on #12, 13, 14
8/23/2011	12	fract--	Coronal fractures on teeth #12, 13, 14, 18, 19, 21
8/23/2011	13	fract--	Coronal fractures on #12, 13, 14

Date	Tooth	Key-No-Yes	phrase
8/23/2011	13	fract--	Coronal fractures on teeth #12, 13, 14, 18, 19, 21
8/23/2011	14	fract--	Coronal fractures on #12, 13, 14
8/23/2011	14	fract--	Coronal fractures on teeth #12, 13, 14, 18, 19, 21
8/23/2011	3	crack-amalgam-	Limited oral eval: #3 B PA abscess (with draining puss), OL amalgam restoration fractured, MD fracture (M,D MR fractured areas and MD crack).
8/23/2011	3	fract--	Percussion positive for #3 (2---+, 3+++ , 4---+, 5---), transillumination verifying MD crown fracture line.
8/25/2011	30	crack--	likely cracked tooth #30, pt referred for ext of tooth
8/25/2011	30	fract--	After examining the the further it showed that she a fracture of mesial cusp going below crest of her ridge. Therefore , since restoration of the tooth would be impossible, she was advised to have #30
8/25/2011	30	fract--	Mesial marginal ridge fracture #30.
8/25/2011	30	fract--	A: previously treated with symptomatic apical periodontitis #30 with likely fracture.
8/25/2011	30	fx--root	possible root fx 30
9/1/2011	30	fract--	The tooth #30 had fractured exposing a sharp margin that was rubbing against the right lateral border of the tongue.
9/1/2011	31	fract--	#31 PAP and gross caries with crown fracture
9/1/2011	31	broke--	broken th #31, broken th #3
9/1/2011	31	fract--	gross caries, fractured #31
9/1/2011	31	fract--	#31 fractured with abscess

Date	Tooth	Key-No-Yes	phrase
9/2/2011	20	fract--	#20 is sensitive to percussion and palpation, #20 has a distal fracture of the crown which descends below the level of the gingiva, this tooth may be restorable with endodontics
9/2/2011	20	fract--	#3 crown missing, #20 distal crown fracture, #31 buccal crwn fracture, #17 missing crwn
9/6/2011	2	fract--	#2 causing sensitivity prior to fracture, after fracture, dull pain on and off.
9/6/2011	2	fract--	Tooth fractured about 2 weeks ago
9/7/2011	12	fract--	Prob: Fractured marginal ridge #29-M, pt complains of heavy occlusion #12
9/9/2011	18	fract--	Fractured cusp #18, retained rt tip #30
9/9/2011	18	fract--	Fractured cusp #18,
9/9/2011	18	broke--	#18 broke off a month ago.
9/9/2011	18	fract--	#18 fractured crown
9/9/2011	18	fract--	#18 fractured crown
9/9/2011	29	broke--	gross caries and severe broken teeth 8,11,12,13,14,1-27 and 29, teeth 8,11,12,13,14 hardly visible
9/12/2011	15	broke--	gross caries on #15 and broken crown.
9/12/2011	31	fract--	#31-D fractured off
9/13/2011	19	broke--	She took in in 1995 and broke out in a sweat and fainted and woke up in an ambulance.
9/14/2011	19	fract--	Fractured #19
9/15/2011	5	fract--	HTC: abrasion noted, refer to dental student for #19-MOL (secondary decay) and #5 loose crown, possible fracture

Date	Tooth	Key-No-Yes	phrase
9/15/2011	5	fract--	P: DH Tx Plan: DE (Dr - #19-MOL (secondary decay) and #5 loose crown, possible fracture, AP (hand instrumentation, SRCP, c-shaped flossing, Superfloss used around bridge on UL, 5 percent fluo
9/19/2011	29	broke--	Tooth #29 broke 4 months ago, pain started 3 days ago.
9/19/2011	31	fract--	#31 fractured crown
9/19/2011	31	fract--	Fractured crown on #31
9/19/2011	31	fract--	Fractured crown #31
9/20/2011	15	fract--	Fractured crown #15,23 hopeless teeth
9/20/2011	15	fract--	Dental: Fractured crowns #6,7,15,23.
9/20/2011	15	fract--	Fractured crowns #6,7,15,23.
9/21/2011	12	fract--	Fractured core on tooth 12.
9/21/2011	12	fract--	Possible fracture discussed with Pt Pt understands that definitive crowns for #11 and #13 will be fabricated after #12 evaluation in grad endo.
9/21/2011	12	fract--	Caries #1,4,5,17 and #12 fractured.
9/21/2011	15	fx--	severely decayed/fx off crown #15D
9/21/2011	15	fx--	severely decayed/fx off crown #15
9/21/2011	15	fx--	severely carious/fx #15
9/21/2011	4	fract--	consult 4, fracture.
9/21/2011	5	broke--	FOM soft, nt,nr,sockets healing well with no OA communication, periodontally involved teeth 5,21,22,23,24,25,26,27 with broken 18,19, FPD area of 5,6,7,8,11
9/23/2011	13	fract--	#13 gross decay fractured lingual cusp

Date	Tooth	Key-No-Yes	phrase
9/26/2011	14	fract--	fractured tooth #13, fractured restoration tooth #14.
9/26/2011	14	fx--	O: Comp Exam/ MDHx reviewed/ 97/61-77/ 3 and 14 DL cusp fx / hEAVY PLAQUE poor homecare / Hx of advanced restorative tx/ +PA#3 / both teeth asymptomatic at the time of exam
9/26/2011	30	fract--	All within normal limits except MB fracture #30 and DL fracture #32.
9/27/2011	20	fract--	Fracture tooth #20.
9/27/2011	20	fract--	#20 is fractured and not restorable.
10/3/2011	15	broke--	A: #15 is broken down to the osseous level and has a hopeless prognosis.
10/3/2011	18	fract--	All WNL except for Large crown fracture and carious lesions #6,12,18, 30 and complete crown fracture #29
10/3/2011	18	fract--horizontal	All WNL except for generalized horizontal bone loss, crown fracture and caries #6, 12,18,29,30
10/3/2011	18	fract--	Dental - large carious lesion + Large crown fracture and carious lesions #6,12,18, 30 and complete crown fracture #29
10/4/2011	19	fract--	All WNL Except for retained primary right and left canine, Gross decay and crown fracture #19, Decay and restoration fracture #30
10/4/2011	28	broke--	TREATMENT I COMMENTS: BP 175/84 P 64 Max rt bridge broken Pa's #30, 28, 5&6, 15
10/4/2011	28	broke--	RTO #28 b, evaluate broken bridge and ext #30
10/4/2011	28	fract--	Pt presents with crown #28 very loose and fractured nearly all the way through
10/4/2011	3	split--	A: Healthy 62 yr/old male presents with tooth #3 split and tooth is unrestorable.

Date	Tooth	Key-No-Yes	phrase
10/4/2011	3	split--	split tooth #3 non-restorable
10/4/2011	31	fract--	Fractured tooth #31, no caries noted.
10/4/2011	31	fract--	fractured tooth #31, generalized plaque and calculus.
10/4/2011	31	fract--	Fracture line running cervical-occlusally between mesial buccal and distal buccal cusp on tooth #31, - cold test, - palpation, - percussion, + tooth sleuth.
10/5/2011	12	broke--	PPTC recall, update med hx , Mar 2010 7 ribs and collar bone broken BP 149/88 Pt 12 min late for appt
10/5/2011	12	fract--	Examination reveals #12- fractured lingual cusp and existing restoration, tooth has badly decayed subgingivally. Tooth is asymptomatic.
10/5/2011	13	fract--	All WNL except for occlusal cavitation #3, Gross Decay #13 and crown fracture, symptomatic to percussion
10/6/2011	3	fract--	Fractured crown #15,23 hopeless teeth
10/6/2011	3	fract--	Dental: Fractured crowns #6,7,15,23.
10/6/2011	3	fract--	Fractured crowns #6,7,15,23.
10/10/2011	2	fract--	A: Fractured #20.
10/10/2011	2	fract--	P: PA and BWX #20, show that fracture is below gingiva.
10/10/2011	31	fract-amalgam-	Caries #2 MLB #24F, #25F, #31MO , #4 fractured MO amalgam.
10/11/2011	12	crack--	Discussed above findings with Pt Showed pt images from microscope and informed pt that due to crack in pulpal floor and lack of sound tooth structure, prognosis for tooth #12 is unfavorable.

Date	Tooth	Key-No-Yes	phrase
10/11/2011	12	fract--	#12 crown fractured
10/12/2011	21	fract-amalgam-	Lingual cusp of #21 is fractured off with occlusal amalgam remaining on tooth.
10/12/2011	21	fract--	A: Fractured lingual cusp #21.
10/12/2011	21	broke--	S,: PPTC for restoration of broken lingual cusp #21.
10/12/2011	21	broke-amalgam-	A: Broken lingual cusp #21 with existing DO amalgam still present.
10/14/2011	12	broke--	Broken and unrestorable #12
10/14/2011	29	broke--	A: #29 cast post and crown broken off at gingiva on Mesial and 2mm incisal to gingiva on Distal
10/14/2011	29	fract--root	gingival level fracture/ remaining roots tooth #29 with PAP
10/14/2011	4	fx--	A: Fractured #4 with apical abscess- needs EXT, caries and other fx noted in tx plan
10/17/2011	5	fract-amalgam-	Upon checking contact noticed class 2 mobility and fractured amalgam on #12 w/ 5-6 mm probings on distal.
10/17/2011	5	fract--root	failed endo tx on #5, periodontal involvement, possible root fracture
10/17/2011	5	fract--	Fractured tooth #5
10/18/2011	15	fract--	Assesment of #15: Crown fracture to gumline, asmpomatic, decay present on remaining tooth structure. Tissue overgrowth around margins and onto surface with localized infection present.
10/18/2011	15	fract--	fracture tooth #15 with caries to gum line, no visible caries on tooth #14.
10/18/2011	15	fract--	fractured tooth #15, RCT #21 with apico, no other gross bony patholgy

Date	Tooth	Key-No-Yes	phrase
10/18/2011	18	fract--	Fractured #18
10/18/2011	29	fract--	S: PPTC for fractured #29.
10/18/2011	29	fract--	H and N exam WNL, #29 crown fracture with only the lingual cusp remaining.
10/18/2011	29	fract--	A: Fractured #29 crown.
10/19/2011	12	fract--	PPTC for emergency/screening for fractured #12
10/19/2011	18	fract--	fractured #18
10/21/2011	18	fract--	#18 fractured crown
10/21/2011	2	broke--	Tooth broke 2 years ago, Pain started a2 weeks ago, Pt was given antibiotic (Augmentin 850mg) 2 weeks ago
10/21/2011	2	fract--	Tooth fracture, Gross decay #12
10/21/2011	2	fract--	Tooth fracture, Gross decay, Non restorable #12
10/26/2011	14	broke--	(points to #14), broken for a while, painful to hot and cold, difficulty chewing on left side, difficulty sleeping
10/28/2011	18	broke--	States he broke #18 and Dr is working with the grad perio department about possible ext and implants #18 and #19.
10/28/2011	18	crack--	19 is edentulous spce, and 18 had MD crack, rendering it unrestorable.
10/28/2011	18	crack-partial-	A: Dx: partial edentulism, cracked tooth 18.
10/28/2011	2	fract--	fractured mesial, caries to pulp...consider prognosis of extraction if 31 cannot recieve RCT and crown and instead gets extracted...then consider prognosis for #2 lingual lesions
10/28/2011	2	fract--	gross caries, RCT, fractured teeth, fractured crown #20-non restorable, #4, 5, and 12 recommended for extraction, nonrestorable

Date	Tooth	Key-No-Yes	phrase
10/28/2011	2	fract--	fractured crown #20-non restorable today, #4, 5, and 12 recommended for extraction, nonrestorable
10/28/2011	3	broke--	2003 pelvic floor collapse, 1996 broke arm after fell off chair, child birth, hernia, tonsilectomy, hysterectomy
10/28/2011	3	broke--	2010 wrist surgery to fix fracture (no complications), 2003 pelvic floor collapse, 1996 broken arm, child birth, hernia, hysterectomy
10/28/2011	3	broke--	2010 left wrist surgery to fix fracture (no complications), 2003 pelvic floor collapse, 1996 broken arm, child birth, hysterectomy
10/31/2011	18	fract--	endo treated #18 with fractured crown
10/31/2011	18	broke--	rt tips #14, #18 broken
11/1/2011	14	crack--	tooth #14 has a crack from occlusal to gingiva on the buccal
11/1/2011	14	crack--	Cracked tooth abcess on palatal gin #14
11/1/2011	29	fract--	A: PRTC with large carious lesion on #30 and fractured IRM restoration on #29.
11/3/2011	19	broke--	#19 carious and broken down, deemed non-restorable, painful, multiple teeth with caries
11/3/2011	29	fract--vertical	A: Dx: #29: Previously treated, Symptomatic apical periodontitis, Vertical Root fracture.
11/3/2011	29	fract--root	vert root fracture #29, pn w/ pressure
11/8/2011	14	fract--	gross caries and fractured tooth #14.
11/8/2011	20	fract--	#20 fractured
11/8/2011	31	fract--	#31 crown fracture

Date	Tooth	Key-No-Yes	phrase
11/14/2011	30	fract--	All WNL Except for retained primary right and left canine, Gross decay and crown fracture #19, Decay and restoration fracture #30
11/14/2011	30	fract--	Fractured restoration and gross caries on #30
11/14/2011	31	fract--	fractured #31 Mesial
11/14/2011	31	fract--	#31 Mesial Fracture
11/14/2011	31	fract--	pt presents with fractured #31.
11/14/2011	31	fract--	fractured #31 mesial
11/17/2011	31	fract--	#31 crown fracture, gross caries
11/17/2011	31	fract--	#31 crown fracture
11/17/2011	31	fract--	#31 fractured mesial part of crown 6 months ago.
11/17/2011	31	fract--	#31 fractured.
11/17/2011	31	fract--	#31 fractured and sensitive to palpation and percussion
11/21/2011	4	split--	#4 split in january.
11/22/2011	12	broke--	#8,12 broken teeth
11/22/2011	13	fract--	Fractured crown #13,20
11/22/2011	13	fract--vertical	Pt understands that the longterm prognosis for tooth #13 is guarded due to class 1 mobility, size of distal restoration and presence of vertical fracture lines on buccal and lingual.
11/23/2011	31	broke--	A: #31 broken crown.
11/30/2011	3	crack-amalgam-	S: PPTC for prophy, poe, and cracked restoration #3 MOD amalgam.
11/30/2011	3	crack--	Cracked restoration #3 on mesial.
11/30/2011	3	crack--	A: Cracked restoration, no caries #3.

Date	Tooth	Key-No-Yes	phrase
12/1/2011	14	fract--	impacted tooth #32, fractured crown tooth #30, supraeruption tooth #15, PARL tooth #14,
12/1/2011	14	fract--	fractured crown teeth #14 and #30, generalized enamel hypoplasia, generalized tobacco staining
12/1/2011	2	broke--	broken 7,8, caries distal #5 mobile 17,#2
12/6/2011	14	broke--	#14 previously initiated RCT w/ broken temporary restoration, #15 caries, #18 temporary restoration, Generalized caries.
12/6/2011	14	fract--	Pt had tongue ring and bit down on #14 3 years ago fracturing part of the tooth.
12/6/2011	15	broke--	#14 previously initiated RCT w/ broken temporary restoration, #15 caries, #18 temporary restoration, Generalized caries.
12/6/2011	3	fract--	Pt had tongue ring and bit down on #14 3 years ago fracturing part of the tooth.
12/7/2011	12	fract-elevat-root	bridge removed from teeth #12-15, teeth #12, 13 elevated atraumatically, tooth #15 extracted with forcep with resultant fracture of palatal root, palatal root removed atraumatically with forcep.
12/7/2011	13	fract-elevat-root	bridge removed from teeth #12-15, teeth #12, 13 elevated atraumatically, tooth #15 extracted with forcep with resultant fracture of palatal root, palatal root removed atraumatically with forcep.
12/7/2011	15	fract-elevat-root	bridge removed from teeth #12-15, teeth #12, 13 elevated atraumatically, tooth #15 extracted with forcep with resultant fracture of palatal root, palatal root removed atraumatically with forcep.
12/7/2011	5	broke--	S: patient presents with wife for evaluation of broken tooth #25.

Date	Tooth	Key-No-Yes	phrase
12/7/2011	5	fract-elevat-root	bridge removed from teeth #12-15, teeth #12, 13 elevated atraumatically, tooth #15 extracted with forcep with resultant fracture of palatal root, palatal root removed atraumatically with forcep.
12/16/2011	13	fract--	RESTORATIVE EXAM: Dr, fractured #13
12/16/2011	18	broke--	#14 previously initiated RCT w/ broken temporary restoration, #15 caries, #18 temporary restoration, Generalized caries.
12/20/2011	30	fract--	#30 fractured a month ago, pt complains of pain upon eating
12/20/2011	4	fract--	tooth #4 endontically treated, tooth #4 is fractured to below the gingiva
1/3/2012	19	fract--	fractured #19 with large PAP
1/3/2012	21	fract--	Fractured crown #21
1/3/2012	21	fract--	fracture crown #21
1/3/2012	21	fract--	fractured #21
1/3/2012	29	fract--	#29 fractured lingually
1/3/2012	29	fract--	Fractured #29
1/3/2012	29	fract--	Lysenko HPI 1/3/2012: #29 fractured 3 days ago, pt had hydrocodone at home and says she took 1 per day and today the pain is 1/10, but she would like to get it out because is in less pain due to meds.
1/3/2012	29	fract--	#29 fracture and pulp necrosis
1/5/2012	13	fract--	#2-MO, 4-MOD, 9-D, 11-M, 13-non-restorable due to decay and fracture, 19-MOBL, 22-DL, ML, 23-M, 25-D, 26-M, 27-M, D decay.
1/6/2012	14	fract--	Fractured restoration on 29 and radiographic decay on 29 14 and 13.

Date	Tooth	Key-No-Yes	phrase
1/6/2012	19	fract--	#19 fractured restoration w/ recurrent decay-sensitive to percussion
1/6/2012	19	fract--	Fractured restoration and recurrent decay existing on #19.
1/9/2012	19	fract--	#19 ext, hopeless due to fracture/decay
1/9/2012	19	broke--	Significant dental findings: #12 and #19 severely broken down and decayed.
1/9/2012	19	broke--	#12 and #19 severely broken down and decayed.
1/9/2012	19	fract--	Fractured #19 years ago, most of crown gone.
1/9/2012	30	fract--	Facial abfraction lesions #5,6, 20, 22, 27,28,29,30.
1/10/2012	15	fract--	#15 M-D fracture with localized probing depths of 8mm on both mesial and distal extents of the fracture.
1/10/2012	29	fract--	consult for tooth 29, fractured crown, caries.
1/11/2012	30	broke--	#30 severely broken down.
1/11/2012	4	fract--	Pt has fractured #4 to the gumline and it is non-restorable.
1/11/2012	4	fract--	#4 - fractured to gumline w/decay, non-restorable - recommend EXT
1/12/2012	13	fract--	Fractured #13
1/12/2012	13	fract--	Fractured tooth #13.
1/12/2012	13	fract--	Fractured, symptomatic #13.
1/12/2012	13	fract--	Fractured tooth #13
1/12/2012	14	fract--vertical	Carious #19, Vertical fracture #14.
1/12/2012	14	fract--vertical	Vertical MD crown and root fracture on tooth #14.

Date	Tooth	Key-No-Yes	phrase
1/12/2012	14	fract--vertical	Vertical MD fracture on tooth #14 - TTP, + percussion sensitivity.
1/12/2012	14	fract--vertical	Patient informed that tooth #14 had a vertical MD fracture extending through the crown and that it was non-restorable.
1/12/2012	19	fract--vertical	Carious #19, Vertical fracture #14.
1/13/2012	13	fract--	#13 fractured occlusal surface.
1/17/2012	19	fract--	#19 Gross caries and fractured crown.
1/17/2012	19	fract--	#19 gross caries and fractured crown.
1/18/2012	12	broke--	orts of continuous pain 7/10, sensitivity to hot/cold, pain has very slightly decreased after RCT #12, there is difficulty in chewing, some relief with pain meds., has been taking Ibuprofen, Motrin &
1/18/2012	12	crack--	Composite restoration with #12 may need to be removed for evaluation of a crack/fracture when pts symptoms improve.
1/18/2012	12	crack--	NV: #12 - Remove composite, check for crack/fracture and restorability and Perio Consult for Crown Lengthening if required.
1/18/2012	12	fract--	Patient dentist restored #12 w/ composite after it fractured.
1/18/2012	12	fract--	Occlusal Assessment: #12 out of occlusion and fractured to the GM on the buccal and M/D .
1/18/2012	12	fract--	told him I spoke with Dr (endo) who reported to me that they (he and his faculty) felt that #12 would not benefit from retreatment and that the tooth is likely fractured).
1/18/2012	12	fract--	Fractured tooth #12, caries
1/18/2012	12	fract--	Fractured tooth #12

Date	Tooth	Key-No-Yes	phrase
1/18/2012	18	broke-amalgam-	O: #18 straight buccal 10mm PD with broken down amalgam margin.
1/19/2012	4	crack--	O: BP 140/85, HR 72 reg, #2 displays occlusal wear but does not show any signs of cavitation and there is no opposing tooth, #12 displays signs of cracking, but tooth is currently asymptomatic, #12F a
1/24/2012	14	crack--root	DE: Dr #14(DF)-either cracked or rooth canal failing.
1/24/2012	14	crack--root	#14- 14mm probing depth on DF - either cracked or root canal failing.
1/24/2012	21	fract--	#21- Non-restorable, crown fractured off
1/25/2012	3	fract--	Abfractions #2,3,14,15.
1/27/2012	12	broke--	When we took the impression out the the pts mouth, the core of #12 broke off.
1/27/2012	12	broke--	Smoothed rough edges of broken #12 to make comfortable for patient until we can ext the tooth.
1/31/2012	19	fract--	pain on percussion and palpation of #19, symptomatic periapical periodontitis secondary to tooth fracture
1/31/2012	20	fract--	Fractured lingual cusp #4 with caries, #20 recurrent caries B near crown margin, #30 recurrent caries B.
1/31/2012	20	fx--	Could visualize M-D fx line pulpal floor #20.
1/31/2012	20	fx--	4 - #20 with M-D fx line.
1/31/2012	20	fx--root	attempt RCT #20 and R/O root fx then P&C #20 plus core B/U #18 then FPD 18-20.
1/31/2012	20	fx--	Concerned with presence of M-D fx line #20.

Date	Tooth	Key-No-Yes	phrase
1/31/2012	20	fx--	Reviewed tx options - pt elects moving forward with implants in light of presence of M-D fx line #20.
1/31/2012	20	fx--	Did offer to institute endo therapy #20 to assess extent of fx.
1/31/2012	29	fract--root	#29 - fractured crown with retained root
2/6/2012	30	fx--	Defective Restorations: #14 M resin overhang removed with #12B blade; #30 hx of RCT w/ mesial marginal ridge fx line noted.
2/7/2012	14	fract--root	#14 fractured - only roots remain
2/7/2012	14	broke--root	Crown of #14 has broken apart with only the root remaining
2/9/2012	19	fract--	Significant findings: crown fracture of #19.
2/9/2012	19	fract--	TX: Assessment reveals tooth #19: fracture to gumline, asymptomatic, post exposed to oral cavity.
2/10/2012	12	fract--	Pt presents with fractured tooth #12
2/14/2012	30	fract--root	simple extraction #30, mesial root appears to be previously fractured from tooth.
2/15/2012	19	broke--	badly broken decayed #19 with PAP
2/16/2012	18	fract--	#1, #16, #17 and #18 crowns fractured
2/16/2012	20	broke--	Had operation on broken nose about 20 years ago to due to trauma.
2/16/2012	3	broke--	#3 gross decay, broken to gumline
2/16/2012	3	fract--vertical	Vertical fracture line on buccal #3 from occlusal to cervical aspect of crown.
2/16/2012	3	fract--	Tooth #3- no response to cold, EPT 80/80, sensitivity to percussion on the distal buccal

Date	Tooth	Key-No-Yes	phrase
			cusps, possible fracture between the MB and DB cusps, no sensitivity to palpation.
2/17/2012	4	fract--	gross caries, RCT, fractured teeth, fractured crown #20-non restorable, #4, 5, and 12 recommended for extraction, nonrestorable
2/17/2012	4	fract--	fractured crown #20-non restorable today, #4, 5, and 12 recommended for extraction, nonrestorable
2/17/2012	5	fract--	gross caries, RCT, fractured teeth, fractured crown #20-non restorable, #4, 5, and 12 recommended for extraction, nonrestorable
2/17/2012	5	fract--	fractured crown #20-non restorable today, #4, 5, and 12 recommended for extraction, nonrestorable
2/21/2012	2	broke--	pt has a broken buccal wall tooth #2,
2/21/2012	29	broke--	Caries, broken down teeth #29, #30
2/21/2012	30	broke--	Caries, broken down teeth #29, #30
2/24/2012	2	broke--	Broke before in May 2010.
2/24/2012	2	broke--	#2 - crown broken off, exposed prep
2/24/2012	2	broke--	Patient broke bridge #2-6 three weeks ago and wants to replace it.
2/24/2012	2	broke--	Since #2 will no longer be needed for a bridge, has no occluded tooth, and is broken down the Pt was instructed on the possibility of crowning, or extraction.
2/24/2012	29	fract--	IOE = localized plaque, PD's > 4mm noted in perio charting, caries #30D, #29 fractured.
2/24/2012	29	fract--root	Lost restoration sealing fractured root #29.

Date	Tooth	Key-No-Yes	phrase
2/24/2012	30	fract--	IOE = localized plaque, PD's > 4mm noted in perio charting, caries #30D, #29 fractured.
2/24/2012	5	broke--	A:Pt 5 unit bridge broke within 1 year.
2/28/2012	20	fract--	O: BP 120/80 EOE-WNL IOE-caries #20-B #25-DL (near gingiva) #27-ML (near gingiva), abfraction #28.
2/28/2012	20	fx--	Also discussed leaving 18 and 20 and doing a minimal repair to minimize caries transmission to remaining high risk teeth and leaving 18 and 20 until they finally fx off and treating with RPD or implan
2/28/2012	20	fract--	A: Crown fracture #20.
3/1/2012	14	broke--	Percussion sensitivity teeth #4, 5, and 14 , broken crown #19, large carious lesions #30
3/1/2012	14	broke--	Maxillary teeth show significant bone loss, periapical radiolucency #14, Broken crown #19, large carious lesions #30
3/1/2012	4	broke--	Percussion sensitivity teeth #4, 5, and 14 , broken crown #19, large carious lesions #30
3/1/2012	4	broke--	Maxillary teeth show significant bone loss, periapical radiolucency #14, Broken crown #19, large carious lesions #30
3/5/2012	14	fract--	A:Fractured cusp of 14
3/6/2012	19	fract--	crown fracture #19
3/6/2012	20	fx-amalgam-	Clinical: #3 open crown margin/caries under crown, #6I fx, #7L poor amalgam contour, #8I/9I fx, #10D caries, #13 caries under crown, #20 caries under crown, #28O fx, #28B caries, #30 caries under crow

Date	Tooth	Key-No-Yes	phrase
3/6/2012	20	fx-amalgam-	A: #3 open crown margin/caries under crown, #6I fx, #7L poor amalgam contour, #8I/9I fx, #10D primary caries, #13 caries under crown w/ PA RL + possible endo, #20 caries under crown extending below bo
3/6/2012	20	fx-amalgam-	Clinical: #3 open crown margin/caries under crown, #5 caries under crown, #6I fx, #7L poor amalgam contour, #8I/9I fx, #10D caries, #11D caries, #13 caries under crown, #15 caries under crown, #20 car
3/6/2012	20	fx-amalgam-	A: #3 open crown margin/caries under crown, #5 open crown margin/caries under crown, #6I fx, #7L poor amalgam contour, #8I/9I fx, #10D primary caries, #11D primary caries, #13 caries under crown w/ PA
3/8/2012	19	broke--	Pt took OTC tylenol and pain went away.Limited Examination reveals- #19- endo treated, grossly decayed, broken to gum level.
3/8/2012	30	fract--	Fractured 30.
3/8/2012	5	fract--	Fractured tooth #5
3/9/2012	19	fract--	Fractured #19
3/14/2012	2	crack-porcelain-	Metal occlusion of #14 open approximately 1mm, and crack in the porcelain on the facial #12 detected.
3/20/2012	29	fract--	Composite filling on #29 is fractured on the distal aspect.
3/20/2012	29	fract--	Patient advised to get a crown placed on #29, to increase the longevity of the tooth, as RCT is done on the tooth and filling has fractured ,patient given approximate estimates.
3/20/2012	29	fract--	Cervical abrasion on #5,9,12, Composite filling on #29 fracturedon the distal aspect .

Date	Tooth	Key-No-Yes	phrase
3/20/2012	29	fract--vertical	vertical root fracture #29
3/21/2012	3	broke--	tooth broken down for 3 years
3/21/2012	3	fract-amalgam-	Gross decay, coronal fracture #2, large amalgam restoration adjacent to surgical site #3
3/21/2012	3	fract--root	#18 crown fracture w luxation/ #13 root tip left - transferred to OMFS to EXT root tips #18 and #13.
3/21/2012	3	fract--	crown fracture #3
3/21/2012	3	fract--	endo treated #3 w/ crown fracture
3/21/2012	4	broke--	Broken crown #4
3/22/2012	20	fract--	Tooth #20 presents with fracture lingual cusp down to the gingival margin with caries extending subgingivally on the DL surface.
3/27/2012	18	fract--	Coronal fractures on teeth #12, 13, 14, 18, 19, 21
3/27/2012	18	broke--	ets healing well with no OA communication, periodontally involved teeth 5,21,22,23,24,25,26,27 with broken 18,19, FPD area of 5,6,7,8,11
3/27/2012	19	fract--	Coronal fractures on teeth #12, 13, 14, 18, 19, 21
3/27/2012	19	broke--	ets healing well with no OA communication, periodontally involved teeth 5,21,22,23,24,25,26,27 with broken 18,19, FPD area of 5,6,7,8,11
3/27/2012	21	fract--	Coronal fractures on teeth #12, 13, 14, 18, 19, 21
3/27/2012	21	broke--	FOM soft, nt,nr,sockets healing well with no OA communication, periodontally involved teeth 5,21,22,23,24,25,26,27 with broken 18,19, FPD area of 5,6,7,8,11

Date	Tooth	Key-No-Yes	phrase
4/2/2012	20	fract--	2mmx1mm ulcer on left lateral border of tongue-possibly due to irritation from fractured #20.
4/2/2012	20	fract--	#20: crown is fractured and mobile
4/3/2012	4	fract--	#4 is fractured and has IRM.
4/3/2012	5	broke--	A: #25 MILF broken/chipped, no caries.
4/3/2012	5	broke--	About a week ago, patient had finished eating and noticed #5 had broken off at the gumline.
4/3/2012	5	fract--	A: non restorable #5-- fracture off at the gingiva
4/4/2012	29	fract--	#29 is fractured and non-restorable
4/4/2012	29	fract--	#29 is fractured into the nerve with gross caries
4/5/2012	18	broke--	caries and broken restoration #18
4/5/2012	28	fract--	Fractured #28 with spontaneous pain
4/5/2012	28	fract--	gross caries and fractured #28
4/5/2012	28	fract--root	fractured #28, root tip #21
4/6/2012	15	crack--	Cracked tooth #15
4/9/2012	14	fx--	ng #3-MO decay, #5 DO temporary restoration intact, #7ML, and #8 DL, #12 DO alloy, #13 MOD alloy, #14 fx gumline carious, #15 - MO decay, #19 DO decay #20 fx gumline carious, #28 DOBL fx carious symp
4/9/2012	20	broke--	#20 broken crown
4/9/2012	20	fx--	#3-MO decay, #5 DO temporary restoration intact, #7ML, and #8 DL, #12 DO alloy, #13 MOD alloy, #14 fx gumline carious, #15 - MO decay, #19 DO decay #20 fx gumline carious, #28 DOBL fx carious symptom

Date	Tooth	Key-No-Yes	phrase
4/9/2012	28	fract-amalgam-	#28 Perc (+), Palp (-), cold(normal), EPT(80/80) Probing 3-4 mm, PA Radiograph reveals: coronal radiopacity consistent with fractured amalgam restoration, coronal radiolucency consistent with caries
4/9/2012	28	fx--	#3-MO decay, #5 DO temporary restoration intact, #7ML, and #8 DL, #12 DO alloy, #13 MOD alloy, #14 fx gumline carious, #15 - MO decay, #19 DO decay #20 fx gumline carious, #28 DOBL fx carious symptom
4/10/2012	18	fract--	irreversible pulpitis and fractured #18
4/10/2012	31	broke--root	Exisiting conditions: #4-O amal, #6-7 & 9-11 all ceramic crowns, #18 DOB amal and broken distal restoration (questionable prognosis), #19 root tip, #25 DF comp, #29#31 MODL amal, #32 broken down toot
4/12/2012	14	fract--	O: RHH, ASA Type II, #14 w/ Hx of RCT, cotton and cavit, fractured distal , gross caries, palpation +, Percussion +, Pus and fistula tract.
4/18/2012	18	broke--root	Exisiting conditions: #4-O amal, #6-7 & 9-11 all ceramic crowns, #18 DOB amal and broken distal restoration (questionable prognosis), #19 root tip, #25 DF comp, #29#31 MODL amal, #32 broken down toot
4/18/2012	31	fract--	#31 has DL fracture exposing pulp
4/20/2012	12	crack--	Discussed non-favorable prognosis #12, need for perio consult, discussion of possible flap procedure to evaluation for crack or perforation #12 or ext
4/20/2012	30	crack--	#30 cracked tooth
4/23/2012	19	fract--	Pt is missing #10, #7 fractured to gingiva, #19 CVC intact/ furcation involvement

Date	Tooth	Key-No-Yes	phrase
4/25/2012	2	fract--	#2 has existing composite with a fracture line running to the distal and below the gingival margin.
4/25/2012	2	fract--	ts to undergo examination under microscope in Grad Endo to determine the extent and location of the fracture and restorability and will complete NSRCT #2 if feasible.
4/25/2012	2	fract--	He understands his options better and plans to have Endo assess the restorability of #2 based on the extension of the fracture.
4/25/2012	2	fract--	pression of maxilla for processing of occlusal guard after Grad Endo has assessed the extent of the fracture on #2.
4/25/2012	2	fract--	#2 no visible fracture, no sensitivity to percussion.
4/25/2012	2	fract--	#2 fractured during NSRCT this AM
4/25/2012	2	fract--	#2 fractured to gingiva
4/25/2012	2	fract--	2) fractured #2
4/25/2012	2	fract--vertical	#2 vertical fracture non restorable
4/30/2012	18	fract--	#18 fractured crown
4/30/2012	19	fract--	Fractured #19
5/1/2012	18	fract--vertical	vertical root fracture #18
5/3/2012	13	fract--	A: Lingual cusp of #13 fractured off.
5/3/2012	13	broke--	During the procedure of extracting tooth #13 core build up and tooth structure broke off.
5/3/2012	13	fract--	#13 core build up was fractured off during previous extraction of #14

Date	Tooth	Key-No-Yes	phrase
5/3/2012	13	broke--	#13 broken down crown, recurrent decay, would need RCT and a crown, discussed treatment options with patient, patient opted for ext of #13
5/3/2012	13	broke--	broken down crown #13
5/3/2012	13	broke--	#13 recurrent decay broken down crown
5/3/2012	2	fract--	Fractured restoration #20, pt already is tx planned to have #20 restored.
5/3/2012	2	fract--	A: Fractured restoration #20 Composite DO.
5/7/2012	13	fract--	Fractured #13
5/7/2012	14	fract--	Fractured #14
5/8/2012	31	broke--	#31 broke about a month ago.
5/8/2012	31	fract--	Gross caries, fractured #31
5/9/2012	14	fx--	#14 fx DMR
5/9/2012	14	fx--	#14 with definitive fx line on DMR that can engage with explorer.
5/9/2012	14	fx--	RTC endo test #14 and tehn MOD and explore fx line.
5/9/2012	14	fx--	#14 with hxz of M-D fx line, endo involvement and endo tx in May 2010.
5/9/2012	14	fx--vertical	possible early signs of vertical root fx #14
5/9/2012	14	fx--	Explained my concern of PDH of fx line in #14.
5/9/2012	19	fract--	Fractured #19
5/14/2012	14	fract--	fractured tooth 14
5/17/2012	18	fract-amalgam-	Fracture present on D portion of DO amalgam #18.
5/17/2012	18	crack--	#18 transillumination shows dentinal crack on mesio-lingual cusp

Date	Tooth	Key-No-Yes	phrase
5/17/2012	18	crack--	Determined that 18 is probably the culprit due to the dentinal crack
5/17/2012	18	crack--	#18: Cracked tooth, asymptomatic irreversible pulpitis, normal periapex
5/17/2012	18	crack-amalgam-	Recommend removing amalgam #18-O, evaluate extent of crack, temporary crown and re-eval symptoms in 2-4 weeks
5/17/2012	21	fract-amalgam-	PAP #22 and fractured composite restoration, amalgam in gingiva distal to #21
5/18/2012	15	fract--	Fractured DL cusp #15, Palatal Tori
5/18/2012	4	fract--	#4 fractured
5/21/2012	4	fract--	A:Fractured cusp of 14
5/25/2012	14	fract--	#14 L 1mm, F 2mm (abfraction incorporates CEJ), class 1 furcation ML
5/29/2012	14	fract--	#14 has a fractured distal marginal ridge with recurrent decay
5/31/2012	3	crack--	Cracked tooth syndrome #3
6/4/2012	30	broke-amalgam-	A: #30 existing core build-up in amalgam, severely broken down and fractured.
6/4/2012	5	fract--	#5 is sensitive to percussion, there is a fracture on the lingual of the tooth, caries are present on the occlusal surface
6/5/2012	2	broke--	DE: completd by Dr: Discussed with Pt about EXT of tooth number 32 and rebuilding the broken cusp on tooth #4.
6/6/2012	18	fract--	Fractured crown on #18
6/6/2012	18	fract--	#18 DO restoration fractured
6/6/2012	18	broke--	The distal of #18 is broken off.

Date	Tooth	Key-No-Yes	phrase
6/6/2012	18	fract--	fractured #18
6/6/2012	18	fract--	Fractured #18
6/7/2012	2	fract--	A: #2 fractured on D and is unrestorable.
6/7/2012	2	broke--	Radiographs: most recent BW show broken/decay on #2
6/8/2012	18	fract--	#18 fractured lingual cusps, non restorable
6/8/2012	18	fract--	#18 fractured.
6/8/2012	2	fract--	TX: Intra-oral assessment reveals temporary restoration on the #2 and #12 DOL fracture.
6/8/2012	28	fract--	Filling fractured out of #28.
6/8/2012	28	fract--	Fractured #28 - nonrestorable -patient opts to extract tooth.
6/12/2012	4	fract--	#4D carious lesion, fractured cusp
6/13/2012	4	fract--	fractured tooth #4
6/13/2012	4	fract--	fracture tooth #4
6/14/2012	19	fx--root	#19: explained that there is likely a root fx.
6/14/2012	19	vrf--	Tooth #19 previously treated, symptomatic apical periodontitis with possible concomitant VRF
6/14/2012	19	vrf--	Cant not make definitive diagnosis of VRF #19 without re-accessing, removing restorative material/obturating material, and staining to evaluate for fracture.
6/14/2012	19	fract--vertical	Vertical root fracture #19B with fistulous tract.
6/15/2012	12	broke--	A: Broken restoration #12 DO.
6/15/2012	12	fract--	Separate #12 O enamel fracture on buccal cusp with caries.

Date	Tooth	Key-No-Yes	phrase
6/15/2012	12	fract--	Also removed a small carious lesion from a fractured portion of the buccal cusp of #12 O.
6/18/2012	5	fract--	O: BP 115/85, Clinical exam reveals #5 class III fracture of facial cusp (pulp visible).
6/18/2012	5	fract--	When you presented on 3-20-12, the tooth #5 was fractured, and found to be non-restorable as you were informed.
6/18/2012	5	fract--	After review, I do not find that Dentistry at VCU is responsible in any way of the fracturing of tooth #5.
6/18/2012	5	fract-amalgam-	A: 5 - B has fractured off but amalgam MODL is still present.
6/18/2012	5	broke--	#5 is broken down, but asymptomatic
6/19/2012	3	crack-amalgam-	clinical exam revealed crack in amalgam restoration on #13
6/20/2012	5	fract--	#5 - crown fracture and carious lesion
6/20/2012	5	fract--	#5 gross decay and crown fracture
6/20/2012	5	fract--	#5 fractured crown
6/21/2012	3	fract--	Repaired fractured ML cusp #2 with Z250 A3 after etching and OBSP.
6/26/2012	28	crack--root	Discussed with patient the tx options for both #28 (root resorption and RCT to keep tooth) and 29 (possible cracked tooth, temp crown, possible RCT and crown).
6/26/2012	28	fract--root	Suspected root fracture #29, and internal resorption #28
6/26/2012	28	fract--root	Internal resorption #28 root fracture 29
6/26/2012	29	crack--	#29 normal pulpal tissue with symptomatic apical periodontitis and possibility of a cracked tooth

Date	Tooth	Key-No-Yes	phrase
6/26/2012	29	crack--root	Discussed with patient the tx options for both #28 (root resorption and RCT to keep tooth) and 29 (possible cracked tooth, temp crown, possible RCT and crown).
6/26/2012	29	crack--	Dx: #29- Normal pulp, Symptomatic apical periodontitis possible due to the cracked tooth (large class 5 restoration, Pt mainly bites from Right side)
6/26/2012	29	fract--	Explained to Pt that #29 needs RCT and possibility is that tooth may be fractured.
6/26/2012	29	fract--root	Suspected root fracture #29, and internal resorption #28
6/26/2012	29	fract--root	Radiolucency #29, suspected root fracture
6/26/2012	29	fract--root	Internal resorption #28 root fracture 29
6/28/2012	20	fract--	#20 fractured at gumline
6/28/2012	20	fract--	#20 core and PFM fractured
7/2/2012	12	fract--root	#12 complete crown fracture with retained root.
7/2/2012	19	fract-amalgam-	- Intra oral exam: Occlusal amalgam filling tooth #19 with distal marginal fracture detected with the transilluminator.
7/12/2012	12	broke-amalgam-	ed hx, BP110/73 OCS , h and n wnl amalgam tattoo unde rtongue, rt floor of mouth pt took pre-med cc broken clasp ultrasonic, handscale, pro PPD < 4mm w localized BOP 12-13 Dr did ex decay posi
7/12/2012	12	fract--	- Has a long span FPD from #4-12, which fractured bewteen #4 and #5 units at the connector, leaving the remaining portion mobile.
7/12/2012	13	fract--	#13 crown fractured several years ago.

Date	Tooth	Key-No-Yes	phrase
7/12/2012	13	broke-amalgam-	ed hx, BP110/73 OCS , h and n wnl amalgam tattoo unde rtongue, rt floor of mouth pt took pre-med cc broken clasp ultrasonic, handscale, pro PPD < 4mm w localized BOP 12-13 Dr did ex decay posi
7/12/2012	31	crack--	#31- cracked tooth and PAP
7/12/2012	31	fract--	#31 - fractured tooth, PAP noted on radiograph.
7/12/2012	4	broke-amalgam-	ed hx, BP110/73 OCS , h and n wnl amalgam tattoo unde rtongue, rt floor of mouth pt took pre-med cc broken clasp ultrasonic, handscale, pro PPD < XXX w localized BOP 12-13 Dr did ex decay posi
7/12/2012	4	fract--	- Has a long span FPD from #4-12, which fractured bewteen #4 and #5 units at the connector, leaving the remaining portion mobile.
7/13/2012	14	fract--	#14 and #15 large fracture and caries
7/13/2012	15	fract--	#14 and #15 large fracture and caries
7/13/2012	19	fract--	Gross caries and crown fracture #19
7/20/2012	3	fract--	A: Tooth #3 presents with the coronal portion completely fractured at the level of the gingiva.
7/20/2012	3	fract--	A: Tooth #3 presents with a hx of non-traumatic fractures that caused extensive coronal destruction.
7/20/2012	3	fract--	fractured tooth #3 previously rct.
7/20/2012	3	fract--	tooth #3 fractured.
7/25/2012	14	fract--root	#14 crown fractured off and roots were sectioned using hand piece.
7/30/2012	13	fract--	Clinical evaluation: #13 PFM crown and prefabricated post came off, tooth structure

Date	Tooth	Key-No-Yes	phrase
			fractured to the bone level, no sinus tract or swelling present.
7/30/2012	13	fract--	#13 fractured to gingiva.
7/30/2012	13	fract--	caries and fractured #13.
7/30/2012	13	fract--	65 yo M who had tooth #13 fracture off, now would like an implant after extraction of tooth.
8/3/2012	15	fract--	1) Fractured crown and caries #15 ext
8/3/2012	15	fract--	Fractured crown and caries #8, 10, 15,
8/3/2012	15	fract--	1) Fractured crown and caries #15 - restorative, RCT/crown, pt elects for extraction
8/3/2012	15	fract--	#15 has gross caries and fractured off while pt was eating on Wednesday.
8/9/2012	15	broke--	#15 broke "QUOTE".
8/14/2012	21	fract-amalgam-	#21 fractured amalgam with caries and restore contact- MOD--> needs to be completed first
8/14/2012	21	fx-amalgam-root	malgam tattoo upper left edentulous ridge, #19D open amalgam margin, open contact between #19/#20, #21 fx off crown, #22 RCT/DI, #30 RCT/PA RL around distal root, #31 residual distal root tip.
8/14/2012	21	fx-amalgam-	, #10MLF/DLF open composite margins, #19 MILFD open amalgam margins, #20MODL open amalgam margins, #21 fx off crown, #22DILF open composite margins, #30 core buildup open restoration margins, #32MO op
8/14/2012	21	fx-amalgam-	caries, #10MLF/DLF secondary caries, #19 MILFD open amalgam margins, #20MODL open amalgam margins, #21 fx off crown/non-restorable, #22DILF secondary caries, #30 core buildup open restoration margins,

Date	Tooth	Key-No-Yes	phrase
8/16/2012	31	fract--	fractured mesial, caries to pulp...consider prognosis of extraction if 31 cannot receive RCT and crown and instead gets extracted...then consider prognosis for #2 lingual lesions
8/16/2012	31	broke--	Placed small temp IRM over open #31 broken restoration.
8/20/2012	12	fract--vertical	Vertical fracture #12
8/20/2012	12	fract--vertical	Vertical fracture unrestorable #12
8/20/2012	12	fract-forcep-root	Ext #12 with forceps (crown fractured off, roots taken out separately)
8/21/2012	4	fract--	RESTORATIVE EXAM: Dr.,#4 fracture in amal 1/2 way down crown on D
8/21/2012	4	fract--	New Caries: #4 restore, fractured on D, tooth may need crown
8/21/2012	4	crack-amalgam-	Eval: #4 - existing occlusal amalgam has crack in it, fractured mesial marginal ridge, craze line over distal marginal ridge
8/21/2012	4	fract-amalgam-	Present Illness: MO composite placed on #4 in 5-16-2012 in AEGD due to fractured occlusal amalgam.
8/21/2012	4	crack--	Pt was informed at appointment of a crack in the mesial marginal ridge of #4 and that the dentist had removed it while doing the filling.
8/21/2012	4	crack--	Pt is very concerned with mobility and crack on #4.
8/21/2012	4	crack--	Transillumination: #4 MO composite, no crack detected, composite precludes adequate testing
8/21/2012	4	fract--vertical	#4 non-restorable due to vertical root fracture
8/22/2012	12	fract--	fractured #12

Date	Tooth	Key-No-Yes	phrase
8/22/2012	5	fract--vertical	-Additional Pt communication or information: Regarding CC, I believe that #5 has a vertical root fracture.
8/22/2012	5	fract--vertical	#5 previously treated with chronic apical abscess, likely vertical fracture
8/22/2012	5	fract--	Recommended NSRCT for tooth #4 and extraction of #5 due to high likelihood of fracture, extent of lesion and furcation involvement.
8/22/2012	5	fract--vertical	#5 is nonrestorable with vertical root fracture.
8/22/2012	5	fract--vertical	A: Vertical root fracture #5 (non restorable)
8/22/2012	5	fract--vertical	Vertical root fracture present on #5 as diagnosed by grad endo.
8/22/2012	5	fract--	-Fractured tooth #5
8/23/2012	5	fract--	#6-F polish, #7-F slight cavitation, #8-F slight cavitation, #9-F watch, #12-DO replaced due to fracture line, #14-MODL-polish, #18-fractured DL and ML cusp so do core build up and crown w/possible el
8/27/2012	19	fract--	Fractured #19
8/29/2012	15	fract--	Tooth 15, tooth structure fractured distally.
8/29/2012	30	vrf--	A: Dx: #30: Pulpal Necrosis, Chronic Apical Abscess, possible VRF, Endo-Perio lesion
8/29/2012	30	fract--vertical	Periodontal diagnosis: Perio/endo lesion (accessory canal in furcation),periodontal abscess buccal #30,Vertical root fracture.localized severe chronic periodontitis with generalized mild chronic perio
8/29/2012	30	vrf--	A: Dx: #30: Pulpal Necrosis, Chronic Apical Abscess, possible VRF, Endo-Perio lesion

Date	Tooth	Key-No-Yes	phrase
8/29/2012	30	fract--	#30 was found top have tooth fracture during an endo appt and patient came back to discuss tx options for implant placement.
9/4/2012	3	broke--	Broken tooth #3.
9/4/2012	3	fract--	#3 is fractured to the gumline and is non-restorable - pt is interested in restoring with an implant.
9/4/2012	3	fract--	#3 - fractured to gumline, non-restorable - pt interested in replacing with an implant
9/4/2012	3	fract-amalgam-	Eval: #28-B decay, #29-B decay, fractured DO amalgam w/recurrent decay, #30-lost crown w/decay
9/10/2012	14	fx--	#14 - note lingual and DMR and B fx lines evident clinically.
9/10/2012	14	fx--	3 - #14 with clinically evident L, DMR and B fx lines but tests vital.
9/10/2012	14	fx--	Note very obvious ling fx line that extends sub ging mid palatal #14.
9/10/2012	14	fract--	Tooth #14 has noted lingual fracture (See Dr notes).
9/10/2012	14	crack--	Cracked tooth syndrome #14 with symptomatic apical periodontitis.
9/10/2012	14	fract--	to grad endo with chief complaint of "QUOTE" Pt referred to grad endo by Dr in FP for NSRCT #14 and evaluate fracture on palatal wall.
9/10/2012	14	fract-amalgam-	ntoraoral: Floor of mouth soft, tongue full range of motion, uvula midline, #13 without crown, tooth fractured on lingual, #14 with provisional crown, removed temp, amalgam occlusal restoration, palata

Date	Tooth	Key-No-Yes	phrase
9/10/2012	14	fract--	Tooth #14 Percussion (-) Palpation (-) Cold (++) Probing (2-3) Mobility (-) Bite (+ MB and ML cusps) Transillumination (+ light impeded along palatal fracture line)
9/10/2012	14	fract--	A: Diagnosis: #14 symptomatic irreversible pulpitis with symptomatic apical periodontitis likely due to fracture on palatal wall
9/10/2012	14	fract--	Discussed above findings with Pt Informed pt that palatal fracture will be visualized under microscope and that #14 may be deemed nonrestorable if fracture extends into orifice.
9/10/2012	14	fx--	See Endo note of July 31 - #14 deemed poor to guarded prognosis due to migration of fx line on palatel to palatal canal space.
9/10/2012	14	fx--	CO fx of temp crn #14.
9/10/2012	14	fract--	existing provisional #14 fractured beyond repair.
9/10/2012	19	fract--	Fractures restoration #19
9/10/2012	19	fract--root	Fractures restoration #19, Periapical radiolucency with distal root
9/10/2012	19	fract--	Fractured restoration #19, Tender on percussion and palpation, No mobility
9/10/2012	19	fract--	Fractured restoration #19: extraction
9/10/2012	19	fract--	Fractured restoration #19
9/10/2012	3	fract--	Fractured #3
9/11/2012	30	fract-amalgam-root	Performed COE: pt has large amalgam on #2, large composite restoration #5 that is fractured and leaking, recurrent caries #8, caries #28, carious root tips #30, large carious lesion that is temporaril

Date	Tooth	Key-No-Yes	phrase
9/11/2012	31	fract-amalgam-root	Performed COE: pt has large amalgam on #2, large composite restoration #5 that is fractured and leaking, recurrent caries #8, caries #28, carious root tips #30, large carious lesion that is temporaril
9/19/2012	20	fract--	Patient concerns include: #9 MLFI restoration (done when you were much younger:), #8 with fracture on facial surface but wants to clean it first and see what it look like and #20, crown came off abou
9/19/2012	20	broke--	consult for 20, broken down, caries, endo tooth.
9/24/2012	4	fract--	Fractured, non-restorable #4
9/26/2012	3	fract--	#3- fractured restoration (temporary in place).
9/27/2012	18	fract--	#18 is fractured and decayed.
10/2/2012	18	fx--	Widened pdl and furcation involvement #18 possible caries and fx.
10/2/2012	18	fx--root	#18 furcaton involvement fx distal root
10/3/2012	2	broke--	Was given percocet for pain, told that 2 UL teeth broken down
10/3/2012	4	fract--root	Referred to endodontics for evaluation of #4 for retreatment and to rule out a root fracture.
10/3/2012	4	crack--	Intraoral: Floor of mouth soft, tongue full range of motion, uvula midline, #4 coronal fracture with provisional restoration in place, no sign of crack or caries
10/3/2012	4	fract--root	Radiograph: #4 fractured to level of CEJ, little remaining root fill along walls, 3x2mm PARL
10/3/2012	4	fract--root	O: #4 must be extracted due to root fracture, no symptoms.

Date	Tooth	Key-No-Yes	phrase
10/3/2012	4	fract--	S: PPTC for PA of #4 and also buccal fracture of #29
10/3/2012	4	fract--	O: BP-128/78, HR-68-reg, Med Hx no changes, Ill(-), Hosp(-), All(-), Class 2 mobility on #4, 5, #29 buccal cusp fractured off, Widened PDL on #4,5 on PA.
10/3/2012	4	fract--	A: Very heavy occlusion on #4, 5, and 29 leading to fremitus and class II mobility of #4, 5 and the fracture of the buccal cusp on 29.
10/3/2012	4	fract--	Informed patient of 4 possibilities of the fracture.
10/4/2012	18	fract--vertical	#18 Vertical root fracture - ext tooth
10/4/2012	18	fract--vertical	#18 Vertical root fracture - non restorable
10/4/2012	18	fract--vertical	#18 vertical root fracture
10/5/2012	4	fract--	#14 - fractured tooth
10/9/2012	18	fx--	#18 crown fx restorable, negative to percussion
10/11/2012	20	broke--	pt ia a internal ref for ext of #6,20 which has been hurting for about a wk and is broken.
10/12/2012	4	fract--	Restored #4 MBDOL Z250 A1 temporarily to prevent remaining tooth structure from fracturing.
10/12/2012	4	fract--	A: #4 fracture to gingiva.
10/12/2012	4	fract-forcep-root	Tooth #4 extracted with forcep, crown fractured, root sectioned and purchase point placed.
10/15/2012	14	fract--root	#14 fractured- root canal treated, gross decay
10/15/2012	14	fract--	#14, #15 gross decay, fractured crown
10/15/2012	14	fract--root	#14 fractured - root canal treated, gross decay
10/15/2012	15	fract--	#14, #15 gross decay, fractured crown

Date	Tooth	Key-No-Yes	phrase
10/15/2012	3	fract--	O: extraoral exam: NSF; intraoral exam: #3 occlusal wear, O and DL amal, F abfraction.
10/16/2012	20	fract--	#20 sensitive to percussion, #12-M box fractured.
10/17/2012	13	fract--	Fractured/Decayed #13
10/17/2012	13	fract--	Fractured crown present on #13 - tooth is sensitive to percussion and palpation, no mobility
10/17/2012	13	fract--	Fractured crown present on #13
10/18/2012	14	fract--	A: Abfraction #24, facial divet #22, #14 asymptomatic- necrotic
10/18/2012	15	fract--	fractured DB cusp #30, Fractured lingual cusp #5, Fractured DL cusp #15.
10/18/2012	15	fract--	Fractured #5 and #15.
10/18/2012	15	fract-elevat-root	#15 had gross decay, PDL was retrated, elevators were used to elevate, the crown fractured upon using forceps, roots were resectioned with hand piece, three root tips were individually elevated out of
10/18/2012	30	fract--	#30 fractured distal buccal cusp.
10/22/2012	20	fract--	teeth 18-21 equally TTP and percussion, #9 with class 3 mobility, #20 with fractured crown and non-restorable
10/22/2012	20	fract--root	teeth 1 and 16 missing, #8 extruded with PAP at the apex, tooth #19 with mesial root caries, #20 previous RCT with fractured crown.
10/22/2012	20	fract--	fractured crown #20
10/22/2012	20	fract--root	fractured crown #20-plan to extarct under LA, explained that he may continue to have pain due to mesial root caries on #19 and therefore after extraction of #20 he needs to see his GP dentist.

Date	Tooth	Key-No-Yes	phrase
10/23/2012	29	fract--	#29 distal fractured
10/24/2012	28	fract--	#28 fractured crown w/caries/non-rest.
10/31/2012	4	fract--	Caries #1,4,5,17 and #12 fractured.
10/31/2012	4	crack--	My teeth cracked, pt points to #4, 5
10/31/2012	4	fract--	#4 & 5 present with gross caries, #4 fractured to the gingiva level
10/31/2012	4	fract--	#4 & 5 present with gross caries, #4 fractured to the gingiva level, deemed non-restorable
10/31/2012	5	fract--	Caries #1,4,5,17 and #12 fractured.
10/31/2012	5	crack--	My teeth cracked, pt points to #4, 5
10/31/2012	5	fract--	#4 & 5 present with gross caries, #4 fractured to the gingiva level
10/31/2012	5	fract--	#4 & 5 present with gross caries, #4 fractured to the gingiva level, deemed non-restorable
11/1/2012	3	fract--	A: #14 has been tx planned for ext due to decay under crown on RCT tooth, #13 has decay into pulp and fractured.
11/1/2012	4	fract--	IOE: diffuse papillary inflammation #13, lingual cusp fractured, 2-3 mm PD throughout with 4-5mm on #13
11/1/2012	4	fract--	#4, 5- Fractured restoration and crown
11/1/2012	5	broke--	Patient points to #5 and says her tooth broke off while eating an apple one week ago.
11/1/2012	5	fract--	#5 has fractured cusp and missing restoration with caries around the gingival floor of the prep.
11/1/2012	5	fract--	#4, 5- Fractured restoration and crown
11/7/2012	15	fract--	#15 D, Fracture #8 MI see Hard tissue notes for details on #15 and #8.

Date	Tooth	Key-No-Yes	phrase
11/7/2012	15	fract--	Restorations needed on #8 MI due to fracture (only esthetic concern - pts choice to fill or not), Decay on #4-D at crown margin (charted at last visit), Decay #15 D may not be restorable.
11/8/2012	2	broke--	#2 has abroke DO amalgam with recuurent decay very close to the pulp
11/8/2012	28	fract--	#28 have short filled RCT, questionable taper, post placed and fractured crown, no PARL.
11/8/2012	28	broke--	#28 broken extensive restoration
11/12/2012	13	fract-amalgam-	A: Fractured Lingual cusp on #13, Existing amalgam restoration aslo fractured
11/12/2012	29	broke-elevat-root	delivered #29 in two pieces: crown and part of root trunk broke after using elevator and forceps.
11/13/2012	18	broke--	caries #18 broken down to level of gingiva.
11/13/2012	19	fract--	Fractured #19
11/14/2012	29	broke--	remove broken temp crown on #29 , fabricate new temp crown with alike material A2
11/14/2012	29	fract--	Provisional of 29 is fractured and needs to be replaced.
11/14/2012	29	broke--	Pt reports his temporary crown broke a few days after it was placed on #29.
11/14/2012	29	broke--	broken temporary #29 and decay on #29
11/19/2012	2	fx--	ORIF bilateral mandibular fx in 2006
11/19/2012	29	broke--	S: PPTC for emergency appt (broken temp #29)
11/26/2012	14	fract--	Fractured #14
11/26/2012	18	fract--	#18 fractured DB w/ B caries, PARL #18
11/26/2012	18	fract-amalgam-	existing O amalgam restoration #18, #18 fractured DB w/ B caries

Date	Tooth	Key-No-Yes	phrase
11/26/2012	18	fract-elevat-root	elevated #18, clinical crown fractured during elevation, distal flap, surgical handpiece used to remove buccal bone, roots elevated.
11/26/2012	19	fract--	fractured #19 with caries extending into the pulp
11/26/2012	19	fract--	dental: fractured #19 with caries extending into the pulp
11/26/2012	19	fract--	Fractured #19 with gross caries
11/26/2012	19	fract--	Fractured #19, gross caries extending into the pulp
11/27/2012	13	fx--	Palatal #13 has fx plane extending 2 -3 mm subging to attachment level..
11/27/2012	13	fract--	Rest - #13 - had all ceramic crown that has fractured M-D and is missing significant lingual coronal structure.
11/27/2012	13	fx--	PA #13 shows fx plane extending almost to level of palatal bone.
11/27/2012	13	fx--	1 - #13 - MD coronal and crown fx extending subgingival on palatal.
11/27/2012	13	fract--vertical	- crown fragments came from #13 - the vertically fractured tooth.
11/27/2012	13	broke--	Broke #13 biting on a rib bone and it is scheduled for extraction.
11/27/2012	13	fract-amalgam-	Intraoral: Floor of mouth soft, tongue full range of motion, uvula midline, #13 without crown, tooth fractured on lingual, #14 with provisional crown, removed temp, amalgam occlusal restoration, palat
11/27/2012	4	fract--	Fractured tooth #4

Date	Tooth	Key-No-Yes	phrase
11/30/2012	21	crack--	Percussion test was done #21 was normal while 20 showed some discomfort,the same results were obtained on biting and probing depths on both teeth were on the average of 2,3.#21 shows grade 2 mobility,
12/5/2012	21	fract--	Restoration #21 - DOBL fractured "QUOTE" according to Pt Pt has had no sensitivity with this tooth.
12/6/2012	19	fract-amalgam-	Fractured amalgam restoration present on #19, possibly the cause of the patient's sensitivity and he is experiencing referred pain.
12/6/2012	3	broke-amalgam-	Intaoral evaluation: Broken down amalgam margins #2,3.
12/7/2012	13	broke--	Tooth #13 broken mesiodistally and extremely sensitive to probing with explorer.
12/7/2012	13	broke--	#13 broken and #31 PAP.
12/7/2012	13	crack--	RTC: Operative #15, evaluate crack #13 and proably needs ext.
12/7/2012	13	fract--	Patient had a fractured #13 and it hurts when she eats.
12/7/2012	13	split--	#13- fractured, split mesiodistally through the pulp chmaber and fracture line extends beyond restorability.
12/10/2012	29	broke--	S: PPTC for emergency appointment with chief complaint: my tooth broke off (pt pointed to #29).
12/11/2012	2	fract--	#32 with DOBL filling absent, D tooth structure fractured below level of gingiva, extensive caries.
12/12/2012	18	split--root	Extraction of #18, 19 - DB Hockey stick incision, FTMPF raised from mesial of #19 to 18, simple extraction of #19, Buccal trough with fissure bur,

Date	Tooth	Key-No-Yes	phrase
			split roots from buccal to lingual 2/3 though roots.
12/12/2012	19	split--root	Extraction of #18, 19 - DB Hockey stick incision, FTMPF raised from mesial of #19 to 18, simple extraction of #19, Buccal trough with fissure bur, split roots from buccal to lingual 2/3 though roots.
12/12/2012	3	broke--	#3 broken down with no crown.
12/13/2012	31	fract--	fractured #31
12/13/2012	5	fract--	Repaired fractured ML cusp #2 with Z250 A3 after etching and OBSP.
12/17/2012	19	broke--	Tooth #19 is hurting the tissue around it because the broken tooth is sharp.
12/17/2012	19	fract--	#19-Fractured crown.
12/19/2012	18	broke--	#18 broke off about 1 year ago.
1/2/2013	31	fract--	Fractured crown #31
1/3/2013	2	broke--	#2 needs to be ext due to tooth being broken down per request of Dr
1/4/2013	31	broke--	#31 broke 4 months ago.
1/8/2013	3	fx-amalgam-	Clinical: #3 open crown margin/caries under crown, #6I fx, #7L poor amalgam contour, #8I/9I fx, #10D caries, #13 caries under crown, #20 caries under crown, #28O fx, #28B caries, #30 caries under crow
1/8/2013	3	fx-amalgam-	A: #3 open crown margin/caries under crown, #6I fx, #7L poor amalgam contour, #8I/9I fx, #10D primary caries, #13 caries under crown w/ PA RL + possible endo, #20 caries under crown extending below bo

Date	Tooth	Key-No-Yes	phrase
1/8/2013	3	fx-amalgam-	Clinical: #3 open crown margin/caries under crown, #5 caries under crown, #6I fx, #7L poor amalgam contour, #8I/9I fx, #10D caries, #11D caries, #13 caries under crown, #15 caries under crown, #20 car
1/8/2013	3	fx-amalgam-	A: #3 open crown margin/caries under crown, #5 open crown margin/caries under crown, #6I fx, #7L poor amalgam contour, #8I/9I fx, #10D primary caries, #11D primary caries, #13 caries under crown w/ PA
1/9/2013	31	broke--	Clinical exam shows decay on #31, with both 28 and 31 broken down to the gumline.
1/9/2013	4	fract--vertical	After endo consult, #4 determined to have vertical root fracture.
1/9/2013	4	fract--vertical	After grad endo evaluation - tooth determined to have a vertical root fracture (pain with tooth sleuth on #4, pt was numbed and there is a PD of 7mm on facial), and Dr said the trabecular patte
1/9/2013	4	fract--vertical	Diagnosis: vertical root fracture tooth #4
1/11/2013	12	fract--	Cervical abrasion on #5,9,12, Composite filling on #29 fracturedon the distal aspect .
1/11/2013	12	crack--	"cracked upper left tooth eating food, #12 has been hurting for a week now, denies pain keeps him up at night, more pain when drinks something sweets, hurts patient when he eats, denies headache, deni
1/11/2013	12	fract--root	#12 possibly restorable with crown lengthening, root canal, and full coverage restoration, gross caries fractured cusp.
1/11/2013	12	fract--	#12 Gross caries, fractured crown
1/11/2013	12	fract--	#12 fractured Buccal cusp down to the bone level gross.

Date	Tooth	Key-No-Yes	phrase
1/11/2013	18	fract--	#18 fractured crown
1/16/2013	31	crack-amalgam-	Existing #31-O amalgam and crack visible running along distal marginal ridge causing pt extreme sensitivity.
1/16/2013	31	crack--	P: Endo testing with dx of cracked tooth #31 along distal marginal ridge.
1/16/2013	31	crack--	S:pptc for eval #31 cracked tooth
1/16/2013	31	crack--	A: #31 cracked tooth along distal marginal ridge causing patient extreme sensitivity particularly with tooth slueht on DL cusp.
1/16/2013	31	crack--	If no sensitivity, will restore #31 crack with a DO restoration.
1/16/2013	31	crack--	A: Remake provisional on #13 and address supposed crack on #31.
1/16/2013	31	crack--	A: cracked tooth #31 along distal marginal ridge (as diagnosed from previous endo testing and clinically visible)
1/22/2013	13	fract--	#13 gross caries, coronal fracture
1/22/2013	15	fract--	A: Pt reported with implant healing abutment on #14 and non-restorable #15 fractured at gum line
1/22/2013	31	fract--	2 -1cm x2 cm ulceration on the ventral/lateral border of the tongue adjacent to #31 which has a fracture sharp cusp edge.
1/25/2013	13	fract--	Fractured CVC FPD #11-13
1/25/2013	13	fract--	A: Crown fracture/gross decay #13.
1/25/2013	13	fract--	Crown fracture #13
1/29/2013	19	broke--	#19 broke yesterday while pt was eating, pain upon chewing at times.
1/31/2013	31	fract--root	Root fracture tooth 31

Date	Tooth	Key-No-Yes	phrase
1/31/2013	31	fx--vertical	Vertical root fx tooth 31-RBA discussed.
1/31/2013	31	fx--vertical	vertical root fx 31
2/1/2013	15	fract-amalgam-	ntraoral: Floor of mouth soft, tongue full range of motion, uvula midline, #13 without crown, tooth fractured on lingual, #14 with provisional crown, removed temp, amalgam occlusal restoration, palata
2/1/2013	15	fx--root	possible root fx of #15
2/5/2013	21	fract--	Fractured #21
2/5/2013	31	fract--	#31 amalagam fractured over a month ago, began to become symptomatic last week.
2/7/2013	15	fract--	Fractured #15, caries
2/7/2013	30	fract--vertical	and #30 EXT - failed RCT or vertical root fracture
2/8/2013	13	broke--	#13 is broken off to the gumline.
2/11/2013	5	broke--	#5 Gross Decay Broken down at gum line
2/15/2013	31	fract--	#31 fractured and carious-percussion sensitive
2/15/2013	31	broke--	#31 broke 2 weeks ago, irritating the inside of her cheek.
2/18/2013	12	broke--	#12- previous NSRCT(poor fill) with a post, clinically the tooth is broken at the level of the gingiva, asymptomatic
2/18/2013	4	fract--	fractured lingula aspect of tooth #4 to ginigval level.
2/18/2013	4	fract--	Previously RCT #4 with crown fracture.
2/18/2013	4	fract-forcep-	attempted siple forceps ext #4 but crown fractured below bone level.
2/19/2013	18	fract--	Fractured #18

Date	Tooth	Key-No-Yes	phrase
2/19/2013	19	broke--	#19 Broken down
2/19/2013	4	fract--	#4 has large DO caries that has fractured out D portion
2/25/2013	29	fract-forcep-	FPD #27-29 was grossly mobile before procedure, bridge was located and removed with digital forceps, and realized that #27 crown was already fractured to begin with and it was inside the retainer, so
2/26/2013	31	broke--	Hard tissue exam (Findings) DE: Completed by Dr Broken DL cusp #31
2/26/2013	31	fx--	#31 Fx DL cusp, Type II diabetes, HTN, atrial fibrillation 2011, stents placed 2002
2/26/2013	31	fx--	Fx DL Cusp #31 communication w/ nerve
2/26/2013	31	fx--	#31 irreversible pulpitis, fx DL cusp
2/26/2013	31	fx--	#31 DL cusp fx off early February 2013 while eating something hard.
2/26/2013	5	broke--	#15 broke "QUOTE".
2/28/2013	30	fract-amalgam-	Trans with microscope revealed #30 amalgam fracture
3/1/2013	15	crack--	A: Differential diagnosis: Cracked tooth #15.
3/4/2013	30	crack--	Cracked tooth #30
3/4/2013	5	fract-amalgam-	#5 presents with a large amalgam fracture
3/4/2013	5	fract--	#5 presents w/ large fracture
3/4/2013	5	fract--	#5 fractured off 4 days ago while the patient was chewing gum.
3/4/2013	5	fract--	Large crown fracture of #5

Date	Tooth	Key-No-Yes	phrase
3/5/2013	15	fx--	#3-MO decay, #5 DO temporary restoration intact, #7ML, and #8 DL, #12 DO alloy, #13 MOD alloy, #14 fx gumline carious, #15 - MO decay, #19 DO decay #20 fx gumline carious, #28 DOBL fx carious symptom
3/5/2013	3	fract-amalgam-	#28 Perc (+), Palp (-), cold(normal), EPT(80/80) Probing 3-4 mm, PA Radiograph reveals: coronal radiopacity consistent with fractured amalgam restoration, coronal radiolucency consistent with caries
3/6/2013	13	fx--	#13 - carious fx of coronal structure with significant caries extending subgingival remaining, crowding lower anterior caries B crn margin #18 - not clinically visible.
3/7/2013	30	crack--	Tooth #30 has been cracked for awhile but hasn't bothered pt until now.
3/11/2013	31	fract--	DE: redo restoration on #31 (possibly a fracture line on the distal of the tooth) discussed possibility of #31 needing crown due to large restoration- pt understands pain scale 2/10 dull ache not cur
3/11/2013	31	fract--	O: Bp:128/78 Hr:66r Fracture line running over the distal marginal ridge of #31.
3/11/2013	31	fract-amalgam-	MOL amalgam #31 is fractured.
3/11/2013	31	fract--	#31 D has a fracture with staining at the margin and suggested replacement of the DO composite.
3/11/2013	31	fract--	A: Fractured on the distal of MODL composite restoration #31.
3/11/2013	4	fract--	fractured and carious 4 and 16.
3/12/2013	3	crack--	PPD < 6mm Dr did exam findings 2 cracked this tooth is guarded with questionable prognosis , 3 needs occ patch, 5 needs occ patch and poss.

Date	Tooth	Key-No-Yes	phrase
3/12/2013	3	fract--	Fractured #3
3/12/2013	5	crack--	PPD < 6mm Dr did exam findings 2 cracked this tooth is guarded with questionable prognosis , 3 needs occ patch, 5 needs occ patch and poss.
3/12/2013	5	fx--	PA taken #5 - patient fx off - asymptomatic.
3/13/2013	18	fract-retainer-	A: Fractured facial porcelain on retainer #20 and gingivitis #18.
3/13/2013	18	fract--	Bridge btw 18-20, the porcelain fractured off a year ago and 2 weeks ago a piece of the pontic fractured off--Needs to be reconstructed
3/13/2013	18	broke--	15: Buccal, #31:B and defect on mesial of restoration-smooth/polish, #20: porcelain of 3 unit bridge broke off 2 months ago, Once in a while patient is Sensitive to cold, #31 is supererupted, #18 small
3/14/2013	4	fract--	#4 fractured about 3 years ago, the pain started happening about 3 weeks ago and when the pain began the patient rated it as a 10 on a pain scale of 1-10.
3/15/2013	2	fract--	#2 caries/fractured lingual part of crown
3/15/2013	2	fract--	#2 caries/fractured crown
3/15/2013	2	fract--	#2 caries/Fractured crown
3/19/2013	3	fract--root	Possible root fracture #3 Lingual surface
3/19/2013	3	fract--	Hard tissue exam (Findings) watche lingual of #3, Restore fracture on #29 and take PA's of #3 and #6 for evals
3/19/2013	3	fract--root	PA #3 tp check for root fracture
3/19/2013	3	fract--	Next Appointment Restore fracture on #29 and take PA #3 for eval and #6 for eval of recurrent caries

Date	Tooth	Key-No-Yes	phrase
3/20/2013	29	fract--	#29 gross decay/crown fracture
3/21/2013	28	fract--	#28- PAP and fractured crown
3/25/2013	12	broke--root	Broken down teeth, with remaining root tips (#2, 12, 15)
3/29/2013	2	fract--	#2 - caries, fractured tooth, PAP
3/29/2013	2	fract--	#2 - caries, fractured tooth, PAP, sensitive to percussion and palpation -- acute apical abscess
3/29/2013	2	fract--	Tooth #2 fractured about 8 months ago.
4/1/2013	19	fx--	#19 - caries, fxed tooth, PAP, mild condensing osteitis
4/1/2013	19	fx--	#19 - caries, fxed tooth, PAP, mild condensing osteitis, percussion sensitive
4/3/2013	3	crack--	Cracked tooth syndrome #3
4/3/2013	3	crack--	#3 pain on pressure release -- crack tooth syndrome
4/3/2013	3	crack--	Crack tooth #3
4/3/2013	31	fract--	Fractured at gingival margin #19 and #31
4/4/2013	29	fract--	#29 - fracture, non-restorable
4/4/2013	29	fract--	Fracture OL on #29
4/5/2013	12	fract--	#12- fractured at gumline
4/5/2013	31	broke--	A- Buccal face of #31 broken down to gingival margin with some evidence of demineralization beneath MB, ML and DB cusps.
4/5/2013	31	fract--	S: PPTC for evaluation of open contact on #19 comp rest and fractured comp rest on #31 CC: "QUOTE"

Date	Tooth	Key-No-Yes	phrase
4/5/2013	31	fract--	A: Strong contact on #19 D, fractured ML cusp on #31 comp rest
4/8/2013	29	broke--	Broken down #29
4/9/2013	30	fract--	#30 fracture through central groove to B and L pieces.
4/9/2013	30	fract--	fractured #30-plan to extract under light IV sedation
4/9/2013	30	fract--	fractured #30
4/9/2013	30	fract--	Fractured #30
4/11/2013	3	fract--	crown fracture #3
4/19/2013	12	fract--horizontal	12 has horizontal RL consistent with root fracture.
4/19/2013	12	crack--	after tooth sluth testing #12 appears to be cracked and the crack was demonstrated when an instrument was placed on mesial marginal ridge and engaged the crack.
4/19/2013	12	crack--	after tooth sluth testing #12 appears to be cracked and the crack was demonstrated when an instrument was placed on mesial marginal ridge and engaged the crack.
4/22/2013	28	fract--	Fractured #20,21,28
4/23/2013	31	broke--	MO portion broke following removal of #31 crown.
4/24/2013	18	fract--	Missing teeth, #18 fractured, #19 non-restorable.
4/24/2013	18	fract--	Rampant decay, 18 fractured, 19 non-restorable
4/24/2013	19	fract--	Missing teeth, #18 fractured, #19 non-restorable.
4/24/2013	19	fract--	Rampant decay, 18 fractured, 19 non-restorable

Date	Tooth	Key-No-Yes	phrase
4/25/2013	5	fx--	A: FX #26 #19 EDENTULOUS AREA (suggest implant) #13 mod/ct (requires margination); #5 REMAKE FGC
4/25/2013	5	broke--	#5 has broken at the gingival line and is unrestorable.
4/25/2013	5	fract--	Periodontal diagnosis: Fractured non-restorable tooth #5
5/1/2013	4	fract--	Fractured tooth #4
5/6/2013	3	fract--	Large fracture/hole in #3 filled by patient with OTC Dental Temp material.
5/8/2013	20	fract--	fracture with large caries #1 and #20
5/8/2013	20	fract--	Ext - Large caries and fractured on #1 and #20
5/8/2013	20	fract--	Large caries and fractured on #1 and #20
5/10/2013	30	fract--	Fractured #30
5/10/2013	30	fract--	Non-restorable, fractured #30.
5/10/2013	30	fract--	fractured tooth #30
5/10/2013	30	fract--root	Pt diagnosed with root fracture, non-restorable tooth #30.
5/15/2013	14	fract--	fractured, carious #14
5/15/2013	14	fract--	fractured, carious #14 with periapical radiolucency
5/15/2013	14	fract--	gross caries, fractured, non-restorable #14
5/16/2013	20	fract--	Eval: #20 - crown fractured to gumline, previous RCT- fractured post, pt is asymptomatic.
5/16/2013	20	fract--	In 10/11 she fractured #20- see AEGD note.
5/16/2013	20	fract--	#20 - fractured to gumline, non-restorable, recommend EXT

Date	Tooth	Key-No-Yes	phrase
5/16/2013	20	broke--	Pt is a internal ref frm Perio for eval and ext of #20 which is broken and is hurting.
5/17/2013	13	fract--	Fractured #13
5/20/2013	15	fract--	15 is fractured and grossly carious, nonrestorable, needs EXT.
5/20/2013	15	fract--	Diagnoses #4 MOD, #12 DO, #13 MOD, #15 fractured and carious EXT, #16 and #17 bother pt sometimes (wisdom teeth) EXT.
5/20/2013	15	broke--	#15 is severely broken down and grossly carious
5/20/2013	15	fract--	#15 fractured and grossly carious
5/20/2013	15	fract--	#15 is fractured and grossly carious
5/20/2013	4	fract--	Significant dental findings: #4 - crown fractured off at gumline
5/20/2013	4	fract--	-Caries: none, fractured #4
5/20/2013	5	fract--	Fractured #5
5/23/2013	12	fract--root	Sinus tract above #12 (severely decayed), #6 root tip (crown fractured off 1 month ago).
5/24/2013	2	fract--	All within normal limites except MB fracture #30 and DL fracture #32.
5/24/2013	2	fract--	#2 D and #4 L cusps are also fractured.
5/24/2013	2	fract--	Fractured #2 with pulpal hyperplasia
5/24/2013	20	broke--	Patient placed temporary restoration bought from drugstore into his broken restoration on #20
5/28/2013	18	fract--	Fractured #18
5/29/2013	4	broke--	Hard tissue exam (Findings) #18 crown marginal failure (B), 22-25 is loose, and #4 (B) cusp is broken off

Date	Tooth	Key-No-Yes	phrase
5/29/2013	4	broke--	Procedures added to treatment plans #18 crown marginal failure (B), 22-25 is loose, and #4 (B) cusp is broken off
5/29/2013	4	broke--	Next Appointment restore #4 (B) cusp is broken, follow-up apPt for pocket depth reduction on
5/29/2013	4	broke-amalgam-	A:Patient has an amalgam build up on #4, the facial is broken.
6/3/2013	13	fract--root	#8 has poor crown/root ratio and #13 is hopeless with a probable root fracture.
6/3/2013	28	fract--	It was also noted that #28 has evidence of a potential fracture on the distal marginal ridge, no tx needed at this time, keep watch.
6/3/2013	28	fract--	29 fracture, 28 PARL
6/3/2013	29	fract--	A: Clinically can see fracture #29.
6/3/2013	29	fract--	29 fracture, 28 PARL
6/3/2013	29	fract--	29, 20 fractured crowns
6/3/2013	29	broke--	#29 fractured crown, pt reports tooth broke in November, pain and swelling managed with Percocet, occasionally wakes him up at night and hasn't been able to chew on that side for 3-4 days
6/10/2013	14	fract--	Pt has large span mobile FPD 6-11 with fracture on #11 and 12-14.
6/10/2013	19	fract--	Small ulceration on lateral border of tongue adjacent to #19 by fractured cusp.
6/10/2013	3	fract--	Pt has fractured nonrestorable mand posterior teeth and perio involved 23-26 remaining.
6/10/2013	4	fract--	Pt has large span mobile FPD 6-11 with fracture on #11 and 12-14.

Date	Tooth	Key-No-Yes	phrase
6/10/2013	4	fract--	Pt presents today with FPD fractured and missing pontics/abutments #4-10.
6/10/2013	4	fract--	#4 has fractured to gingival but not causing pt pain.
6/11/2013	12	fract--	#12 DO recurrent caries with fractured restoration.Endo consult should be done on #13.
6/11/2013	12	fract--	#13 has fractured crown (palatal cusp) with leaking temporary restoration, #12 has leaking composite restoration.
6/11/2013	12	fract--	Intraoral: Floor of mouth soft, tongue full range of motion, uvula midline, #12 with DO resin with secondary caries on occlusal and cervical aspects, groove or fracture on MMR.
6/11/2013	12	crack--	Discussed above findings with Pt Informed pt that #12 secondary caries appears extensive around DO restoration and there may be a crack associated with MMR.
6/11/2013	12	fract--	#12- More visible due to #13 fracture.
6/11/2013	13	fract--	IOE: diffuse papillary inflammation #13, lingual cusp fractured, 2-3 mm PD throughout with 4-5mm on #13
6/11/2013	13	fract--	#12 DO recurrent caries with fractured restoration.Endo consult should be done on #13.
6/11/2013	13	fract--	#13 has fractured crown (palatal cusp) with leaking temporary restoration, #12 has leaking composite restoration.
6/11/2013	13	broke--	Pt has recently broken L cusp of #13 and is asymptomatic.
6/11/2013	13	fract--	#13 with MOD provisional restoration, L cusp fractured off

Date	Tooth	Key-No-Yes	phrase
6/11/2013	13	fract--	#13- previous endo treated with Fractured LIngual portion of crown.
6/11/2013	13	fract--	#13- Fractured lingual portion of crown with temporary restoration.
6/11/2013	13	fract--	#12- More visible due to #13 fracture.
6/11/2013	31	fract--	#31 gross decay, fractured tooth - non restorable
6/11/2013	31	fract--	#31 gross decay, fractured tooth
6/12/2013	12	fract--	#12 complete M-D fracture, L segment is mobile.
6/12/2013	12	fract--	#12 mobile fracture crown
6/12/2013	12	fract--	#12 mobile fracture crown - non restorable
6/12/2013	12	fract--	#12 mobile fracture crown -ext
6/12/2013	12	fract--	#12 fractured crown
6/12/2013	2	fract--	#2 - gross caries, fractured DB cusp - patient denies sensitivity to percussion
6/18/2013	18	broke-clasp-	RPD with broken retentive clasp #18, framework rests on #18 with bracing clasp on L.
6/18/2013	2	fract--	#2 fractured tooth.
6/20/2013	19	fract--	Discussed that #19 most likely has a fractured with patient.
6/20/2013	19	fract--	NV- Refer back to UG for extraction #19 due to non-restorability of fracture
6/21/2013	20	fract--	#20 fractured crown.
6/24/2013	12	fract-porcelain-	distal decay under cantilever bridge (#12-13), occlusal portion has been worn through, and #12 porcelain has fractured on facial of B cusp.
6/25/2013	12	fract--	#12 - gross caries and fracture

Date	Tooth	Key-No-Yes	phrase
6/25/2013	3	fract-partial-	Pt diagnosed with:Generalized severe chronic periodontitis (Refractory), secondary OT (#4,5,28,29,12,13,20,21), partial edentulism, nicotine stomatitis.
6/25/2013	30	fract--	recon plate R angle of mandible with fracture through bone at the R angle sign on non-union, caries #30, FBI 1,16,17, ? remaining of #32
6/25/2013	30	broke--	almost full dentition, Broken #30 with large caries
6/26/2013	19	broke--	Crown of #19 broken down.
6/26/2013	19	broke--	#19 crown broke off about a month ago.
6/26/2013	19	broke--	#19 Crown broken down non restorable
6/27/2013	19	fract--	Hard tissue exam (Findings) #19 fractured MOD
6/27/2013	19	fract--	S: PPTC for #19MOD fractured restoration
6/28/2013	5	fract-amalgam-	Prob: #2 MOD amalgam fractured, recurrent caries crown #30 B (patient 15 minutes late).
6/28/2013	5	fract--	Oral exam reveals fractured tooth #5.
7/2/2013	2	broke--	#2 is broken in the DL surface and its been sensitive to pt for a month.
7/3/2013	19	fract--	Periodontal diagnosis: generalzed severe chronic periodontitis, Crown fracture 13, Failed endo 19
7/3/2013	3	fract--	Abfraction on #3 noted.
7/3/2013	30	fract--	Fractured #30
7/11/2013	13	fract--	#13 fractured L cusp/non-restorable
7/11/2013	14	broke-amalgam-	D #14 broken amalgam filling/tooth structure
7/11/2013	14	crack--	Transillumination: #14 crack running over mesial marginal ridge (documented with medicapture images_

Date	Tooth	Key-No-Yes	phrase
7/11/2013	14	crack--	Discussed tx options, risks/benefits, questionable prognosis due to crack, and pricing (RCT, core, crown, crown lengthening) with Pt Patient elects to extract #14 due to finances and questionable prog
7/11/2013	14	fract-amalgam-	#14-DO fractured amalgam restoration
7/12/2013	2	fract--	#2 is fractured, has spontaneous pain.
7/12/2013	21	fract--	21 Fractured- DL
7/12/2013	21	fract--	1) PAP associated with #21- Not sensitive to percussion: Patients states pain is due to soft tissue trauma due to sharp edge of tooth after restoration fracture.
7/12/2013	21	fract--	Grossly carious previously fractured #21
7/16/2013	30	fract--	fractured #30
7/22/2013	14	fract--	fracture #14
7/22/2013	18	fract--	#18 , 5, 13 crown fracture
7/22/2013	18	fract--	#18 fractured/decay
7/22/2013	18	fract--	#18 fractured, decay non restorable
7/22/2013	18	broke--	#18, Tooth broke on Saturday
7/22/2013	18	fract--	Fractured #18
7/23/2013	14	fract-amalgam-	Previous lingual portion of an amalgam OL restoration on #14 has fractured out.
7/23/2013	29	fract--	Previous distal restoration on #29 has fractured out.
7/23/2013	31	fract--	Fractured crowns #2, 15,18, 19, 20, 31.
7/23/2013	31	fract--	#31 fractured crown

Date	Tooth	Key-No-Yes	phrase
7/23/2013	31	fract--	#1 and #2 missing, #3 fractured crown, #7 and #8 missing, #10 fractured crown, #15 and #16 missing, 17, 18 and 19 missing, #20 fractured crown, #30 missing, #31 missing
7/23/2013	31	fract--	#31 fractured crown - ext
7/24/2013	14	fract--	Fractured #14
8/1/2013	12	fract--root	Hard tissue exam (Findings) Generalized abfraction, root surface decay on 9 D, 12 M, watch 29 D and 30 B
8/2/2013	18	crack--	Possible crack on buccal/lingual of #18.
8/5/2013	14	fract--	#14- Fractured crown
8/5/2013	14	fract--	#14- fractured crown- unrestorable
8/5/2013	14	fract--	#14- Fractured crown
8/5/2013	4	broke--	Carious tooth #4- Crown is broken down
8/5/2013	4	broke--	#4-gross caries and broken crown
8/8/2013	3	fract--	Indicates tooth #3, says fractured 'long time ago"QUOTE"bonded it" but it came off around 6 months ago.
8/12/2013	30	fract--	Fractured #30
8/13/2013	12	fract--	Fractured and carious teeth 4, 11, 12.
8/13/2013	12	fract--	Fractured teeth 4, 11, 12.
8/13/2013	12	fract--	fractured teeth 4, 11, 12
8/13/2013	12	fract--	fractured teeth 4, 11, 12-RBA discussed, recommend ext 4, 11, 12.
8/13/2013	20	broke--	Pt reports tooth (Pt points to #20) broke about two weeks ago.
8/13/2013	4	fract--	Fractured and carious teeth 4, 11, 12.

Date	Tooth	Key-No-Yes	phrase
8/13/2013	4	fract--	Fractured teeth 4, 11, 12.
8/13/2013	4	fract--	fractured teeth 4, 11, 12
8/13/2013	4	fract--	fractured teeth 4, 11, 12-RBA discussed, recommend ext 4, 11, 12.
8/19/2013	31	fract--	#3 crown missing, #20 distal crown fracture, #31 buccal crwn fracture, #17 missing crwn
8/20/2013	18	fract--	#18 gross caries and distal crown fractured
8/20/2013	18	fract--	#18 fractured distal with gross caries.
8/20/2013	18	fract--	#18 fractured distal with gross caries
8/20/2013	21	broke--	#21-DO broken filling and secondary decay
8/20/2013	21	fract--	#21-MOD- removed old fractured composite- old pulp exposure, no bleeding.Pt was asymptomatic.Tooth is very short.Explained to pt that if wants to save this tooth it will need endo, post and core, CLP,
8/21/2013	18	fract--	Fractured #18
8/22/2013	14	crack-amalgam-	DE: Dr, referral to grad endo for #14,15 evaluation, return for crown on #5-due to large amalgam and cracks on tooth
8/26/2013	12	fract--	#12 - fractured
8/26/2013	12	fract--	1- #12 fracture and decay with mobility
8/26/2013	4	broke--	#4 Broken crown
8/26/2013	4	fract--	#4 - Fractured cusp, PA/RL
8/26/2013	4	fract--	#4 - Fractured cusp - non restorable
8/26/2013	4	fract--	#4 -fractured crown
8/27/2013	19	fx-partial-	#19 gross mesial caries, partial fx of crown, sensitive to hot/cold/pressure, at worst 10/10 pain

Date	Tooth	Key-No-Yes	phrase
8/28/2013	14	broke--	decayed and broken down #3 , Decayed margin around tooth #14
8/28/2013	3	broke--	decayed and broken down #3 , Decayed margin around tooth #14
8/28/2013	5	fract--	Additonal Narrative #5 was determined to be non-restorable once the crown and cast post and core was removed and a continous BL fractured was seen
8/29/2013	15	fx--root	O: BP: 112/71, HR:75 , H&N exam (WNL), Intraoral Fx: , Radiology Fx: Gross caries #3, 4, 19, Root Caries #15 D, Generalized radiographic calculus, Possible caries #22 M, D & root, Generalized moderate
8/29/2013	19	fx--root	O: BP: 112/71, HR:75 , H&N exam (WNL), Intraoral Fx: , Radiology Fx: Gross caries #3, 4, 19, Root Caries #15 D, Generalized radiographic calculus, Possible caries #22 M, D & root, Generalized moderate
8/30/2013	18	crack--	Determined #18 has cracked tooth syndrome.
8/30/2013	18	crack--root	If not, would have endo make access opening #18 to evaluate if crack goes down the root.
8/30/2013	18	crack--root	Explained to patient that this may be referred pain for her cracked tooth#18 and that it would not be right to pull #19 without figuring out the root of the problem.
8/30/2013	18	crack--	#18 - temporary crown, referred from AEGD for ext b/c of cracked tooth
8/30/2013	18	crack--	#18 - Cracked tooth
9/3/2013	12	fract--	Carious, fractured, non restorable teeth 4, 5, 6, 7, 8, 9, 10, 11, 12, 20, 21, 22, 23,24, 25, 26, 27, 28.

Date	Tooth	Key-No-Yes	phrase
9/3/2013	4	fract--	Cariious, fractured, non restorable teeth 4, 5, 6, 7, 8, 9, 10, 11, 12, 20, 21, 22, 23,24, 25, 26, 27, 28.
9/3/2013	5	fract--	Cariious, fractured, non restorable teeth 4, 5, 6, 7, 8, 9, 10, 11, 12, 20, 21, 22, 23,24, 25, 26, 27, 28.
9/4/2013	18	fract--	P: took PA of #18, endo testing #20-18 and #13-15, Dr for endo consult, agreed with endo diagnosis, refer to grad endo for RCT of #18, went over possible treatment options with pt including adva
9/4/2013	18	crack--	Dr completed H&N exam (all WNL except: #18 have 10 X 12 mm large fistula adjacent to #18, color white and red - was diagnosed at last exam but has not been treated also, has 7 mm pocket on dist
9/5/2013	28	crack--vertical	#28 has a vertical crack from buccal cusp through the mesial to distal
9/5/2013	28	crack--	#28 has a crack from facial through the lingual.
9/5/2013	28	crack--	#28 cracked on B cusp through M and D
9/9/2013	18	fract--	DO restoration in #18 satisfactory, no caries found, no apparent fracture seen with transillumination.
9/9/2013	18	fract--	Fractured with Gross Caries #18,19
9/9/2013	18	fract--	Fractured #: 8,9, 16, 18, 19
9/9/2013	18	fract--	Fractured #18, 19
9/9/2013	18	fract--	Fractured with Gross Caries #18, 19
9/9/2013	18	fract--	Fractured #18 with carious lesion
9/10/2013	12	fract--	Fractured teeth 6,7, 11, and 12.
9/10/2013	12	fract--	Fractured non restorable teeth 6, 7, 11, 12
9/10/2013	12	fract--	Fractured teeth 6, 7, 11, and 12.

Date	Tooth	Key-No-Yes	phrase
9/10/2013	30	fract--	fractured and caries on 14 and 30
9/11/2013	2	fract-porcelain-	#20 - distal rest (Note: pt informed before procedure the risk in porcelain fracture and the possible need for survey crown.
9/11/2013	21	fract--root	DD: Root fracture, Tooth #21.
9/11/2013	30	fract--	Fractured #30
9/12/2013	19	broke--	A: broken #11DF due to no retention, #12 B abfraction with decay, #19B abfraction with decay.
9/13/2013	15	broke--	sinus pain for 1-2 weeks, both #11 and #15 have broken off at gumline
9/17/2013	18	crack--	#18: palpation (-) percussion (++) probing (2-3mm) cold (+++) mobility (0) transillumination (crack on distal marginal ridge) tooth sleuth (+ all cusps)
9/17/2013	18	crack--root	nefits, questionable prognosis, and pricing (RCT, core and crown) with Pt Patient understands that #18 may need to be extracted if the crack extends into the root.
9/17/2013	18	fract--	has been having pain lower left, AEGD placed filling but pain persisted, Perio evaluated and said #18 fractured and they would try to fill but patient still in pain
9/17/2013	29	fract--	Fractured #29, 5,
9/20/2013	31	fract--	#31 crown fracture
9/23/2013	2	fract-partial-	did exam today recc pt come in to have teeth equilibrated on rt side and recc occ guard , abfraction UL, partial perio charting of deep areas today, pt also needs to return for RPSC , 2,3 18 R

Date	Tooth	Key-No-Yes	phrase
9/23/2013	4	fract-partial-	did exam today recc pt come in to have teeth equilibrated on rt side and recc occ guard , abfraction UL, partial perio charting of deep areas today, pt also needs to return for RPSC , 2,3 18 R
9/25/2013	12	crack--	12 needs evl filling cracked and poss cracked tooth,18 ml decay, 30 needs final occ restoration
9/25/2013	12	crack-amalgam-	The fractured amalgam will need to be removed to eval remaining tooth structure #12 - depending on extend of crack, it may be possible to restore the tooth with a bonded MOD amalgam if the crack/fx is
9/25/2013	12	fract--	Tx: IOE reveals that #12 had an MOD Ag, Lingual cusp is completely mobile - fracture occurred along the lingual margin of MOD restoration.
9/25/2013	5	fract--	Fractured #5
9/26/2013	12	fract--	#12 previous endo treatment,fractured coronal tooth structure,lateral radiolucency on the distal aspect might be periodontal cyst,recommended extraction because of poor prognosis
9/26/2013	12	broke--	Patient has broken coronal tooth structure on #5,12 which have NSRCT done long time ago and they exhibit periapical radiolucencies on x-ray.Endo testing was done and both showed negative responses to
9/26/2013	12	fract--	#12 is nonrestorable and recommended extraction which was also recommended for #13 since the patient will get an RPD and it would be more economic to add an extra tooth to it.Also recommended ext #10

Date	Tooth	Key-No-Yes	phrase
9/26/2013	13	fract--	#12 is nonrestorable and recommended extraction which was also recommended for #13 since the patient will get an RPD and it would be more economic to add an extra tooth to it. Also recommended ext #10
10/1/2013	20	fract--	Both of my teeth have been fractured (#10, #20) for about 3-4 years now.
10/1/2013	4	broke--	S: PPTC from hygiene for broken tooth on #4
10/1/2013	4	broke--	Clinical exam of #4 shows broken mesial marginal ridge that possible contained a previous restoration
10/1/2013	4	fract--	S- PPTC with fractured #4
10/1/2013	4	fract-amalgam-	A- #4 lingual wall fractured off as well as part of MO amalgam, caries under amalgam restoration
10/1/2013	4	broke--	A: Broken temporary crown on #4
10/1/2013	4	broke--	Integrity temporary crown and bridge material and A2 shade flowable composite were used to fix the broken temporary crown #4.
10/1/2013	4	fract--	A: Tooth #4 fractured at gumline, perio probings 2-3mm around tooth
10/1/2013	4	fract--	P: discussed with patient that tooth #4 is non-restorable due to fracture at gum line.
10/1/2013	4	fract--	Fractured, non-restorable #4
10/3/2013	18	fract-amalgam-	A: #18 existing amalgam restoration MOL portion fractured and #28-D fracturedw/recurrent car
10/3/2013	18	fract--	A: Fractured restoration #18 - MOL
10/3/2013	18	fract--	Fractured #18 - possible restorable - patient elects to EXT

Date	Tooth	Key-No-Yes	phrase
10/3/2013	18	fract--	Fractured #18
10/3/2013	18	fract--	Fractured #18 while eating a few days ago.
10/3/2013	18	fract--	Fractured crown #18
10/4/2013	12	fract--	fractured #12
10/4/2013	3	fract--	Tx: Pt presented in a very anxious manner about her fractured tooth (#3).
10/4/2013	3	fract--	IOE revealed a large fracture of the core buildup on #3 with exposed endo treated canals.
10/7/2013	21	broke--	Broken existing restoration DO of tooth #20, abrasion and erosion buccal of teeth #20 and 21
10/7/2013	21	fract--	#21 Fractured facial cusp with gross caries extending sub-gingival
10/7/2013	21	fract--	Evaluated #21 - caries approaching the pulp, fractured facial cusp, sensitive to percussion, previously determined non-restorable
10/7/2013	31	fract--	PAP and fractured tooth #31
10/7/2013	31	fract--	PAP #31, fractured tooth #31, gross decay #31
10/7/2013	5	fract--	number 5 buccal deep abfraction, 9 10 and 11
10/7/2013	5	fract--	Noted that the buccal of number 5 had a deep abfraction and recommended a restoration on number 5 to prevent the lesion from getting deeper
10/7/2013	5	broke--	Intraoral: Floor of mouth WNL, Oral Hygiene fair, multiple restorations, tooth #5 buccal cuspid broken and recurrent decay under MOD composite filling.
10/7/2013	5	fract--	A: Tooth #5 with RCT therapy performed, patient told that generalized plaque and calculus, with multiple decayed and fractured teeth

Date	Tooth	Key-No-Yes	phrase
10/7/2013	5	fract--	A: Fractured mesial facial wall #5, probing depths 3-4mm around the tooth with a 6mm pocket along the mesial wall and a visible occlusal fracture line on the mesial marginal ridge.
10/7/2013	5	fract--root	PAX #5, noticed the fracture line at that time, decided to eval fracture with methylene blue stain, Dr from Grad Endo evaluated in GP5 and noticed a horizaontal intra-pulpal root fracture and p
10/7/2013	5	crack--	P: Tooth #5 intrapulpal crack inspected: 1 carpule of 2% Lidocaine with epi 1:100,000 given as buccal and palatal infiltration.
10/7/2013	5	crack--root	NSRCT tooth #5 was evaluated and unfortunate due to Crack needs to be extracted, discussed with Dr the possibility of reimbursing of root canal tooth #5 and use money towards NSRCT Tooth #17.
10/8/2013	15	fract--	#15 fractured
10/8/2013	15	fract--	#15 fractured, EXT
10/9/2013	12	fract--	Tooth #12 has been fractured below the gum line.
10/9/2013	13	fract--	and palpation sensitive, however, it is impossible to tell if her symptoms are coming from adjacent fractured and non-restorable #11 and #13, therefore, will evaluate #12 after 11 and 13 are extracted
10/9/2013	15	fract--	Fractured #15, EXT
10/9/2013	15	fract--	Impacted #1, caries #2, 3, 5, 12, 13, 29 , fractured #15, 19, 30
10/9/2013	15	fract--	Fractured #15, 19, 30
10/9/2013	20	fract--	#20 - fractured - non-restorable

Date	Tooth	Key-No-Yes	phrase
10/9/2013	3	fract--	Additonal Narrative fasting blood glucose this morning was 130 mg/dL, patient has lingual fracture lines on #20 and 21 - keep watch
10/9/2013	31	fract--	After removing the bridge, #29 prep was intact but #31 prep was fractured and most of the coronal tooth structure was retained in the bridge.
10/10/2013	18	fract--	#18 fractured crown with caries
10/10/2013	18	fract--	Fractured crown #18
10/15/2013	13	fract--	Crown fracture #13
10/15/2013	18	fract--	#18: Fractured/decayed
10/15/2013	18	fract--	#18 Heavily decayed, ML cusp fracture
10/16/2013	20	fract--	fractured L cusp of #20
10/16/2013	20	fract--	A: fractured lingual cusp #20.
10/16/2013	20	broke--	pt reports piece of tooth on lower left (#20) has broken off
10/16/2013	20	fract--	A: mesial portion of #20 fractured.
10/16/2013	20	fract--	A: fractured mesial marginal ridge on #20 with decay present
10/16/2013	20	fract--	A: Fractured #20-MO
10/16/2013	20	fract--	A few days ago #20 MO portion of restoration fractured
10/16/2013	20	fract--	A: fractured crown and restoration on #20 with recurrent decay present.
10/16/2013	20	fract--	#20 fractured crown to bone level, no radiographoc or clinical evidence of infection patient is not currently experiencing pain in this tooth.

Date	Tooth	Key-No-Yes	phrase
10/21/2013	18	fract--	Exam reveals a missing occlusal restoration in #18 that is now deeply carious; there is a risk that the distal portion of the tooth has a fracture from being undermined by caries.
10/22/2013	12	fract--	Talked to patient about treatment options for #12 due to buccal cusp fracturing off.
10/22/2013	28	fract--	fractured #28
10/24/2013	30	broke-amalgam-	#30 broken tooth near existing amalgam restoration.
10/28/2013	13	fract--	#13 fractured crown at gumline
10/28/2013	13	fract--	#13 fractured crown at gum line
10/28/2013	18	split-elevat-root	#18 extracted surgically using 702 to split the roots and removed with elevator, no complications, irrigated with ns
10/29/2013	12	fract--	A: Patient presents with large fracture across central groove of #12.
11/1/2013	14	fract--	Fractured #14
11/5/2013	13	crack--	NV- NSRCT #13 (evaluate for crack under scope)
11/5/2013	13	fract--	Fractured tooth 13 w/ draining intraoral sinus tract
11/5/2013	13	fract--	Fractured tooth 13.
11/5/2013	13	fract--	Fractured tooth 13 w/ draining intraoral sinus tract-RBA discussed, rec ext under LA.
11/5/2013	13	broke--	#13 broke about 1yr ago with no associated pain, abscess, or swelling noted.
11/5/2013	18	fract--	#18 fractured and decay
11/5/2013	18	fract--	#18 fracture, caries

Date	Tooth	Key-No-Yes	phrase
11/5/2013	30	fract--	#30 fractured
11/5/2013	31	fract--	Additonal Narrative #31 O removed caries with Carbide burs, noted fractured in base of prep.
11/6/2013	18	broke--	PP to AEGD clinic for repair of broken provisional bridge from #18-20.
11/6/2013	18	fract--	Tx: Bridge fractured between #18 and 19 - pt brought #18 in a bag.
11/6/2013	5	fract--	fractured DB cusp #30, Fractured lingual cusp #5, Fractured DL cusp #15.
11/6/2013	5	fract--	Fractured #5 and #15.
11/6/2013	5	fract-elevat-root	#15 had gross decay, PDL was retrated, elevators were used to elevate, the crown fractured upon using forceps, roots were resectioned with hand piece, three root tips were individually elevated out of
11/8/2013	12	fract--	Fractured restoration on #4, 12
11/8/2013	19	fract--	#19 fractured/non-restorable
11/11/2013	30	fract--	Distal half of #30 completely fractured to gumline.
11/11/2013	31	fract--	Hard tissue exam fractured #3, fractured IRM restoration #31
11/13/2013	20	fract--	#20 fractured crown.
11/15/2013	20	broke--	Distal Caries/Broken Tooth #20
11/15/2013	20	broke--root	Retained Roots/Broken Teeth - 2/15/20/32
11/18/2013	2	fract--	A: Generalized plaque, calculus, staining, Large fracture on 2O and missing cusp 20L
11/19/2013	18	fx--	#:18 FX emerg

Date	Tooth	Key-No-Yes	phrase
11/19/2013	18	fx--	O: ProbFocExam / MedDentHx reviewed/ + IPA / Impressions lingual aspect #18 previously treated by endo and now presents as clinically Fx to the lingual furcation /gag reflex and limited opening less t
11/20/2013	19	fract--	Clinically there is decay in the fractured regions of #19.
11/21/2013	2	fract--	Re: ext fractured, non-restorable #20 - review med Hx and informed consent.
11/25/2013	3	fx--root	O: BP: 112/71, HR:75 , H&N exam (WNL), Intraoral Fx: , Radiology Fx: Gross caries #3, 4, 19, Root Caries #15 D, Generalized radiographic calculus, Possible caries #22 M, D & root, Generalized moderate
11/25/2013	3	fx--	O: BP: 127/82, HR: 81, H&N exam (WNL), Intraoral Fx: Gross caries #3, 4, 15, 19, Radiology Fx: large radiolucencies #3, 4, 15, 19
11/25/2013	4	fx--root	O: BP: 112/71, HR:75 , H&N exam (WNL), Intraoral Fx: , Radiology Fx: Gross caries #3, 4, 19, Root Caries #15 D, Generalized radiographic calculus, Possible caries #22 M, D & root, Generalized moderate
11/25/2013	4	fx--	O: BP: 127/82, HR: 81, H&N exam (WNL), Intraoral Fx: Gross caries #3, 4, 15, 19, Radiology Fx: large radiolucencies #3, 4, 15, 19
11/26/2013	30	fract--	O: #30 extensive caries and fractured ML cusp that is sharp.
11/27/2013	29	fract--	Fractured and gross caries #29.
12/2/2013	30	fract--	#30 fracture, sensitive to percussion
12/5/2013	21	fract--	Reveals fractured 20, distal shadow on 21 suggestive of caries, and inadequate fill for the RCT #19.

Date	Tooth	Key-No-Yes	phrase
12/5/2013	31	fract-amalgam-	PPTC for restoration of fractured amalgam in #31.
12/5/2013	31	fract-amalgam-	Patient requires replacement of existing fractured amalgam in tooth #31.
12/5/2013	31	fract--	DE: examined by Dr he recommends core build up on #12 MODL due to overhang and filling #31 B due to abfraction
12/5/2013	31	fract--	Buccal #31 due to abfraction
12/5/2013	31	fract--	#31 has large abfraction on Buccal surface.
12/5/2013	31	fract--	Deep abfractions linguals of 6, 7, 8, 9, 10, 11, 14, 29, 31.
12/5/2013	31	fract--	Dr examined #31B and stated that restoration is stable and appears to have severe abfraction, continue to monitor.
12/5/2013	31	fract--	Dr examined #31B and stated that coronal restoration is stable and appears to have severe abfraction, continue to monitor.
12/5/2013	31	fract--	Suspicious area noted on #31, deep abfraction with staining and soft upon exploration, #29 marginal staining on restoration.
12/9/2013	12	fx--	Carious #s 4,5,6,8,9,11,12,13 (#s 4, 8 fx'ed crowns)
12/9/2013	13	fx--	Carious #s 4,5,6,8,9,11,12,13 (#s 4, 8 fx'ed crowns)
12/9/2013	4	fx--	Carious #s 4,5,6,8,9,11,12,13 (#s 4, 8 fx'ed crowns)
12/9/2013	5	fx--	Carious #s 4,5,6,8,9,11,12,13 (#s 4, 8 fx'ed crowns)

Date	Tooth	Key-No-Yes	phrase
12/10/2013	29	fract--	DE: Perio consult: Dr discussed with the Pt the severe bone loss on tooth #29 and the possibility of it being fractured.
12/10/2013	29	fract--	If tooth is fractured, it was explained that #29 will be extracted and bridge sectioned mesial to #31.
12/10/2013	29	fract--	If the tooth is fractured the bridge will be sectioned and #29 + pontic will be removed.
12/11/2013	20	crack--	Percussion test was done #21 was normal while 20 showed some discomfort,the same results were obtained on biting and probing depths on both teeth were on the average of 2,3.#21 shows grade 2 mobility,
12/11/2013	20	fract--	Carious, fractured, non restorable teeth 4, 5, 6, 7, 8, 9, 10, 11, 12, 20, 21, 22, 23,24, 25, 26, 27, 28.
12/11/2013	21	fract--	Carious, fractured, non restorable teeth 4, 5, 6, 7, 8, 9, 10, 11, 12, 20, 21, 22, 23,24, 25, 26, 27, 28.
12/11/2013	28	fract--	Carious, fractured, non restorable teeth 4, 5, 6, 7, 8, 9, 10, 11, 12, 20, 21, 22, 23,24, 25, 26, 27, 28.
12/11/2013	28	fract--root	Current Periodontal concerns Likely root fracture 28
12/11/2013	28	fx--root	Pt has vert root fx on 28, an FPD abutment.
12/11/2013	30	fract--	#30 MB abfractive lesion present.
12/12/2013	15	broke--	Broken Teeth - #2/15/32
12/12/2013	15	broke--root	Retained Roots/Broken Teeth - 2/15/20/32
12/12/2013	2	broke--	Broken Teeth - #2/15/32
12/12/2013	2	broke--	Distal Caries/Broken Tooth #20
12/12/2013	2	broke--root	Retained Roots/Broken Teeth - 2/15/20/32
12/12/2013	30	fract--	Fractured #30

Date	Tooth	Key-No-Yes	phrase
12/13/2013	30	fract-porcelain-	The Pt also asked "QUOTE" Informed Pt that the porcelain had fractured from the metal substructure on #30, but that since the margins of the crown were intact, unless the previous RCT was failing or
12/13/2013	30	fract-porcelain-	#30 - PFM crown with fractured porcelain (margins intact)
12/13/2013	30	fract--vertical	#30: vertical root fracture.
12/13/2013	30	fract--vertical	A: #30 vertical root fracture on distal root.
12/13/2013	31	fract--	#31--severe decay and fractured crown
12/17/2013	2	broke--	Dental History Patient has had 2 reported endodontic retreats on #14 at VCU since the original treatment in Greece in 1999 and reports a file was broken in this tooth and left.
12/17/2013	2	fract-elevat-vertical	#20 extracted using elevator and it was found to be vertically fractured.
1/3/2014	5	fx--	#5 fx'ed to gumline.
1/3/2014	5	fx--	- #5 fx'ed to gumline.
1/8/2014	12	fract--	Fractured #12 w/ caries, non-restorable
1/8/2014	12	fract--	Pt reports #12 has been hurting for a couple of weeks, and the crown has fractured off.
1/8/2014	18	fx--	3 - FPD 18-20 - has advantage of cuspal covering #18 that has evidence of fx line.
1/8/2014	18	fx--root	Guarded prognosis given hx of CTS, fx line and external resorption #18 plus short root/bone support #20 as ant abut.
1/13/2014	31	fract--	#31 Previous RCT and core build up, chronic apical periodontitis and D fractured.
1/14/2014	30	fract--	fractured #30

Date	Tooth	Key-No-Yes	phrase
1/16/2014	15	fract--	Grossly decayed, fractured tooth #15.
1/16/2014	15	fract--	Grossly decayed/fractured tooth #15.
1/16/2014	2	fract--	#2 Deistal decay, Buccal fracture - non restorable
1/16/2014	2	fract--	#2 Mesial Decay, buccal surface fractured
1/17/2014	15	fract--	#15 fractured crown
1/17/2014	15	fract--	Dental: #15 crown fractured
1/17/2014	15	fract--	#15 DL crown has fractured off
1/17/2014	15	fract--	#15 decay, crown fractured
1/24/2014	15	fract--vertical	#15 was determined to have a vertical root fracture on the ML12mm and MB 10mm.
1/28/2014	29	fract--	S: PPTC for fractured 29
1/28/2014	29	fract--	Diagnosis fractured lingual cusp #29, #28 with recurrent decay
1/28/2014	29	fract--	pt presented with fracture of #29 lingual cusp to gingiva, determined remaining tooth structure non-restorable.
1/28/2014	29	fract--	Decayed, fractured #29
1/28/2014	3	fract-amalgam-	#3 Large DOL amalgam restoration, fractured DB cusp
1/28/2014	3	fract--	Fractured DB cusp #3
1/31/2014	18	fract--	fractured #18
1/31/2014	29	broke--	Hard tissue exam (Findings) 8 difl, 9 f, broken bridge 29-31
1/31/2014	29	crack--	re doing RCT and crown lengthening,pt prefer to EXT and have an implant , PFM crown of #8,9 due to crack line #8 and multiple different shades

Date	Tooth	Key-No-Yes	phrase
			of existing composites,D decay #20 which is abutment of
1/31/2014	31	fract-porcelain-	Hard tissue exam revealed caries 13M, access hole that is not covered/sealed #12, nonrestorable #31, porcelain fractured off PFM pontic #4.
2/3/2014	30	fract--	Fractured #30
2/5/2014	3	fract--	#3 Fractured restoration - extraction
2/5/2014	3	fract--	#3 Fractured restoration
2/5/2014	3	fract--	#3 Fractured restoration - to gingival margin
2/7/2014	18	split--root	extracted #18 surgically removed bone and split roots removed mesial and distal root with east west
2/11/2014	13	fract-amalgam-	fractured L cusp #13 (MOD amalgam present), only thin facial cusp remaining, vitality testing EPT #12 - 32/80, #13 - 22/80, #14 - 32/80, #4-33/80, neg to percussion or palpation, cold test with Endo
2/11/2014	13	fract--	Dx: fractured restoration #13, gen gingivitis, caries #31F (non cavitated).
2/11/2014	30	fract--	fractured #30
2/12/2014	31	crack--	31 has a defective filling and crack 31 d marg ridge
2/12/2014	31	fract--	Patient had a fracture on the lingual of #31, prepped fracture and occlusal retention in occlusal composite.
2/12/2014	31	crack--	Both 30 and 31 have large composites in them and appear to have small cracks.
2/12/2014	31	fract--	Fractured tooth 31.

Date	Tooth	Key-No-Yes	phrase
2/12/2014	31	fract--	fractured tooth 31.
2/14/2014	31	fract--	fractured #31
2/18/2014	12	broke--	Patient also presents with broken crowns on #6, 12.
2/18/2014	12	fract--root	presented option of NSRCT and crown for this tooth, but she opted for EXT for time and finances), #12 has crown fracture (nonrestorable), #21 remaining root tip (non restorable) - patient opts for EX
2/18/2014	2	broke--	Patient also presents with broken crowns on #6, 12.
2/18/2014	21	fract--root	tion of NSRCT and crown for this tooth, but she opted for EXT for time and finances), #12 has crown fracture (nonrestorable), #21 remaining root tip (non restorable) - patient opts for EXT of all thes
2/20/2014	12	fract--	A: #12- subgingival fracture on buccal cusp
2/20/2014	13	fx--	O: BP: 135/87, HR: 114, H&N exam (WNL), Intraoral Fx: caries, generalized plaque/calculus, Radiology Fx: caries, severe bone loss
2/20/2014	3	fract--	Fractured MB cusp on 3.
2/20/2014	3	fract--	Large fracture #3 w/ exposed pulp
2/21/2014	15	fract--	#15- ASX fracture on the distal and mesomarginal ridge.
2/21/2014	15	fract--	#15- ASX fracture on the distal and mesomarginal ridge.
2/21/2014	15	fract--	- small enamel crazinf on MMR and DMR of 15, patient asked about crown due to similar fracture on #2 - no opposing dentition to put additional strain on tooth, so advise to monitor existing restoratio

Date	Tooth	Key-No-Yes	phrase
2/24/2014	12	fract--	#12 fractured crown
2/25/2014	18	fract--	Grossly carious and fractured #s 2, 18.
2/25/2014	18	fract--	Grossly carious/fractured #s 2 and 18.
2/25/2014	18	fract--	#18 - grossly decayed and fractured (mesial half of crown gone), no ttp, no associated vestibular swelling.
2/25/2014	20	fract--	#20 fractured and decayed.
2/25/2014	20	fract--	#20 fractured and decayed
2/25/2014	20	fract--	#20 fractured crown and decay
2/26/2014	19	fract--	#19 fractured
2/28/2014	30	fract--	Fractured cusp #30
2/28/2014	30	fract--	also with caries 32, fractured but non-carious 30.
2/28/2014	30	fract--	fractured distolingual cusp #30 but above level of gingiva and non-carious.
3/4/2014	20	fract--	#20 fractured/decayed, Perc +, palp -
3/4/2014	20	fract--	#20 fractured positive to percussion.
3/4/2014	20	fract--	#20 fracture.
3/4/2014	3	fx--	O: BP: 135/87, HR: 114, H&N exam (WNL), Intraoral Fx: caries, generalized plaque/calculus, Radiology Fx: caries, severe bone loss
3/4/2014	4	fx--	O: BP: 135/87, HR: 114, H&N exam (WNL), Intraoral Fx: caries, generalized plaque/calculus, Radiology Fx: caries, severe bone loss
3/4/2014	4	fx--	O: BP: 131/74, HR: 90, H&N exam (WNL), Intraoral Fx: caries, Radiology Fx: PARLs 18, 19
3/5/2014	3	fract--	fractured cusp on #3
3/10/2014	2	fract--	Grossly carious and fractured #s 2, 18.

Date	Tooth	Key-No-Yes	phrase
3/10/2014	2	fract--	Grossly carious/fractured #s 2 and 18.
3/10/2014	2	fract--	#2 - grossly decayed with fractured crown to gumline
3/11/2014	5	fract--	#5 fractured to gumline - EXT
3/11/2014	5	fract--	#5 fractured to gumline
3/11/2014	5	fract--	#5 fractured to gumline- Buccal cusp is mobile and painful when moved
3/11/2014	5	broke--	#5 broke last night when eating a pork chop.
3/14/2014	18	fract--root	Root fracture #18
3/14/2014	29	fract--	A: Fractured abutment crowns #29, #27
3/19/2014	19	broke--	Tooth #19 broke a week ago, pain started 3 days ago.
3/19/2014	5	fract--	PPTC recall , pt 15 min late, update med hx, BP 138/84, ocs, H and N ex, cc none ultrasonic, handscale, pro , explained resident will want FMX and periochart , pt has severe abfractions , recession.
3/19/2014	5	fract--	PPTC recall , pt 15 min late, update med hx, BP 138/84, ocs, H and N ex, cc none ultrasonic, handscale, pro , explained resident will want FMX and periochart , pt has severe abfractions , recession.
3/19/2014	5	fract--	FMX taken - recurrent decay noted around crowns UL and UR, abfraction lesions LL; #25 has been extracted and the crown is bonded to #24 and 26 with moderate to severe recession and mobility of #24 and
3/19/2014	5	fract--	Restorative tx plan completed for extraction of #23, 25, and 26 and insertion of an essix temporary, as well as restoration of cervical

Date	Tooth	Key-No-Yes	phrase
			abfraction lesions and recurrent decay #18 and 31 and fabricatio
3/20/2014	29	fract--root	post/crown was mobile and the tooth may be moving with it, and it was possible that there may be a fracture in the root of #29.
3/20/2014	29	fract--	Explained to patient that the bridge should be sectioned to eliminate the possibility of bridge fracture and thus, the fracture of the intact crown of #29.
3/20/2014	29	fract--root	Probed #29 and found an 8mm pocket on distolingual signifying possible root fracture.
3/20/2014	3	fract--	fractured crown and core #3.
3/20/2014	4	fract--	O: Extraoral exam: WNL, Intraoral exam: Tooth #4 is fractured to gumline.
3/20/2014	4	fract--	#4-Tooth fractured at gingival margin and non-carious.
3/21/2014	14	fract--	A: caries and fractured tooth #19-DO, recurrent decay #14-DO
3/24/2014	19	fract--	Fractured with Gross Caries #18,19
3/24/2014	19	fract--	Fractured #: 8,9, 16, 18, 19
3/24/2014	19	fract--	Fractured #18, 19
3/24/2014	19	fract--	Fractured with Gross Caries #18, 19
3/24/2014	19	fract--	Fractured w/gross caries: #19.
3/24/2014	19	fract--	Fractured 8, 9, 16, 19.
3/24/2014	19	fract--	#19 fractured, gross caries.
3/26/2014	2	crack--	Discussed possible cracked tooth as etiology, tx options, risks/benefits, questionable prognosis,

Date	Tooth	Key-No-Yes	phrase
			and pricing (RETX, core) with Pt Patient elects #2 RETX.
3/26/2014	2	fract--root	#2 fractured root
3/27/2014	19	fract--	Fractured #19
3/28/2014	19	fract--	Caries diagnosed {as recorded with grossly decayed fractured tooth #19 on DOBL}.
3/28/2014	19	fract--	{-} significant overjet/Flared incisors, {+} fractured teeth #19
4/3/2014	30	fract--	#30 fractured crown
4/4/2014	14	fract--	Fractured crown #14
4/4/2014	18	crack--	#18 O composite, recurrent decay; MMR, DMR cracks, stained
4/4/2014	18	crack--	NV: Stage 2 #18, crack protocol
4/4/2014	18	crack--	Pt needs b/u and crown #18 which is cracked and required Endo tx which is now completed.
4/4/2014	18	crack--	#18 - Previously Treated Pulp, Chronic Apical Abscess, cracked tooth
4/4/2014	18	crack--	Discussed with patient that this tooth would require extrtaction at this time and our clinical cracked tooth protocol would allow for his charges for the NSRCT #18 to be refunded as it has not been a
4/4/2014	18	fract--root	Root fracture #18
4/4/2014	18	fx--vertical	#18- vertical root fx, non restorable
4/8/2014	5	fract--	Patient states that #4 fractured 1.5 weeks ago and #14 fractured 1.5 months ago.
4/8/2014	5	fract--	While excavating caries from tooth #5, the buccal wall fractured and there was a pulp exposure.

Date	Tooth	Key-No-Yes	phrase
4/8/2014	5	fract--	Dental History #5-Pulp exposed after buccal cusp fracture during restorative procedure.
4/8/2014	5	fract--	Clinical Exam: #5-all but the lingual cusp has fractured off at the gumline.IRM placed from last appointment has dislodged (reason for Pt appointment today).No swelling buccal or lingual.
4/8/2014	5	fract--root	Radiograph Findings #5- Fractured crown, 1:2 crown to root ratio,t, PDL in tact, no PAP present.
4/8/2014	5	fract--	A: #5 presents with fractured crown, only lingual cusp remaining and minimal IRM left from last appointment.
4/9/2014	12	crack-amalgam-	Recommended PFM crown for #12 because of present large core build-up, and for #30 because of current mesial crack and large amalgam restoration.
4/9/2014	12	fract--	#12 fractured, RCT, non restorable
4/9/2014	12	fract--	#12 Fractured
4/9/2014	12	broke--	The facial part of #12 has broken off.
4/11/2014	12	fract--root	Fractured #12, root tips present
4/16/2014	30	fract--root	endo consult #30 : moderate bone loss, furca involvement, pap on mesial of previously treated #30; positive to palpation, negative to percussion; short fill , missed canal ? or possible fractured root
4/16/2014	30	vrf--	Discussed that #30 likely had VRF based on testing today.
4/18/2014	14	fract-amalgam-	A: #14 with existing MOD amalgam and fractured M-L cusp
4/18/2014	14	crack--	#14 Cracked ML

Date	Tooth	Key-No-Yes	phrase
4/18/2014	14	broke-amalgam-	Clinical Exam: Broken M marginal ridge broken on#14 with large MOD amalgam
4/21/2014	29	fract-porcelain-	Complete fracture #30 porcelain facing, FPD #29-31 margins sealed and acceptable, occlusion verified.
4/21/2014	29	fract--	O: #29 crown fractured at gingiva, GP visible, B caries subgingival evident
4/23/2014	18	broke--	missing teeth , generalized carious broken down #2,3,15,18
4/25/2014	20	fract--	Fractured #20
5/1/2014	20	fract--	#20 - Fractured, non-restorable
5/1/2014	20	fract--	1) Fractured non-restorable #20
5/1/2014	20	fract--	1) Fractured, symptomatic, non-restorable #20
5/1/2014	20	fract--	1) Fractured, symptomatic, non-restorable #20-extract
5/1/2014	31	fract--	fractured tooth #20 (previously RCT), restoration fracture tooth #31, no other signs of gross caries.
5/1/2014	31	fract--	fractured tooth #20, carious tooth #31, impacted tooth #1, 16, 32.
5/1/2014	31	fract--	Fractured restoration tooth #31.
5/1/2014	4	fract--	#24 F and #25 F abfractions.
5/1/2014	4	fract--	Roughened the surface of the abfractions on #24 and #25.
5/1/2014	5	broke--	gross caries on #15 and broken crown.
5/5/2014	29	fract--	Fractured #29
5/6/2014	29	fract--	Fractured #29
5/6/2014	29	fract--	Fracture #29

Date	Tooth	Key-No-Yes	phrase
5/6/2014	29	fract--	Fracture on #29
5/6/2014	29	fract--	Fracture #29 with gross caries.
5/7/2014	14	fract--	#14 - fractured
5/7/2014	14	fract--	fractured #14 referred from dentist
5/7/2014	15	broke--	#1,15,16 severely decayed and broken down
5/7/2014	15	broke--	#1,15,16 broken off and sensitive for more than a year.
5/7/2014	2	split--	Pt reports pain beginning 2 days ago and thinks he may of bitten down on something that caused the tooth to split.
5/7/2014	2	fract--root	Fractured root tip #2- ext
5/7/2014	2	fract--root	#2 fractured root tip
5/7/2014	30	fract-porcelain-	Pt presents with PFM crown #30 fractured porcelain all along mesial
5/7/2014	30	fract--	Findings: Tooth #18-M recurrent caries, Tooth #30-F 7mm probing depth, suspect possible fracture, recurrent decay.
5/7/2014	30	fract--	Internal referral to PG Endo for eval #30, suspected possible fracture.
5/7/2014	30	fract-porcelain-	Dx: Tooth #30 - fractured porcelain on mesial of crown, mesial open margin, and previous endo access through the crown restored with composite.
5/7/2014	30	fract--vertical	non-restorable #30-patient was seen in Endo and tooth has vertical fracture and not restorable, due to purulence discharge patient placed on 2 weeks of Amoxicillin, then to return in 2 weeks for extra

Date	Tooth	Key-No-Yes	phrase
5/7/2014	30	broke--	missing 1,16,17,32, broken #30 with previous RCT, #30 broken, erythema associated with the buccal aspect of #30, purulance discharge from the buccal aspect, no vestibular fullness, no other gross cari
5/7/2014	30	broke--root	missing teeth 1,16,17,32, Broken crown #30, #30 previously root canal treated, PAP associated with #30, no other gross caries noted
5/7/2014	30	fract--	at this time the an attempt was made to extract #30 with cowforn however the tooth was then fractured in 2 peices.
5/7/2014	5	broke--	Pt states that her tooth (#5) broke off a couple of months ago and has been causing her severe discomfort since.
5/8/2014	3	broke--	broken 3,18
5/8/2014	3	split--root	tooth 3 broken/split in half down to the root
5/8/2014	3	fract--	Fractured 3-ext
5/14/2014	19	broke--	#29 broken, #19 broken to gumline with large periapical radiolucency.
5/14/2014	19	fract--	#19 and 29 fractured crowns with gross decay, swelling of buccal vestibule and sensitivity to palpation around #19
5/14/2014	3	fract--	#3 gross caries/fracture- percussion +++, palpation +++
5/14/2014	3	broke--	#3 broke a year ago.
5/14/2014	30	broke--	Broken #s 30 and 18 to gumline.
5/15/2014	15	fract--	carious and fractured #15
5/15/2014	18	fract--	#18 buccal fracture, gross decay and #19 gross decay

Date	Tooth	Key-No-Yes	phrase
5/15/2014	18	fract--	Dental: gross decay #18 and #19; #18 buccal fracture
5/15/2014	19	fract--	#18 buccal fracture, gross decay and #19 gross decay
5/15/2014	19	fract--	Dental: gross decay #18 and #19; #18 buccal fracture
5/15/2014	19	fract--	#19 fractured on buccal on sunday.
5/15/2014	28	broke--	broken teeth:6,7,8,9,10,11,12,14,15,22,23,24,25,26,27,28
5/15/2014	28	broke--	broken: 6,7,8,9,10,11,12,14,15,22,27,28-ext future visit OMFS
5/16/2014	14	broke--	broken 14
5/16/2014	14	broke--	broken 14 ext
5/16/2014	18	fract--	#18 Fracture EXT
5/16/2014	18	fract--	#18Fracture
5/16/2014	18	fract--	#18Fractured
5/16/2014	3	fract--	#3-palatal cusp fracture, unrestorable
5/16/2014	3	fx--	#3-removed fx cusp - unrrrestorable
5/16/2014	3	fract--	#3 Fractured but still attached lingual cusp, unable to determine depth of fracture.
5/16/2014	3	fract--	Tooth #3 has fractured lingual c
5/16/2014	30	fract-amalgam-	#30 - Class 3 mobility, fractured amalgam restoration to pulp
5/16/2014	30	fract--	fractured crown #30 &31, B tender to palation
5/16/2014	30	fract--	fractured crown #30 &31--ext
5/16/2014	30	broke--	#30 broken crown, Tender to palpation

Date	Tooth	Key-No-Yes	phrase
5/16/2014	30	broke--	#30 broken crown, Tender to palpation--exo
5/16/2014	30	broke--	previously treated #30 has crown broken off, patient is symptomatic and syas pain keeps him up at night
5/16/2014	30	fract--	#30 fractured, non-restorable
5/16/2014	30	fract--	1) #30- large fracture, non-restorable- extract
5/16/2014	30	fract--	1) #30- large fracture, non-restorable
5/16/2014	30	fract--	1) Large fracture tooth #30
5/16/2014	30	fract--	1) #30- Large fracture, non-restorable
5/19/2014	13	broke--	Pt reports that teeth #'s 4, 5, 12 &13 started to hurt 2 weeks ago and that #'s 5 and 13 have been broken off for ~6months
5/19/2014	30	broke--root	root tips of #30, microdent distal #16, broken down #1
5/19/2014	30	broke--root	root tips of #30, broken down #1
5/19/2014	4	broke--	Pt reports that teeth #'s 4, 5, 12 &13 started to hurt 2 weeks ago and that #'s 5 and 13 have been broken off for ~6months
5/21/2014	18	broke--	Pain began Sunday, #18 broke one year ago.
5/21/2014	19	fract--	Fractured #19 with gross caries
5/21/2014	19	fract--	Dental: Fractured #19 with gross caries, fractured #5, multiple other carious lesions
5/21/2014	31	fract--	Dental: Fractured DB cusp #31, recurrent decay,
5/21/2014	31	crack--	Approx 2 weeks ago tooth cracked (points to #31).
5/21/2014	31	crack--	#31 Previously restored and cracked, fracture and decay communicates with pulp, #19 grossly carious

Date	Tooth	Key-No-Yes	phrase
5/21/2014	31	fract--	#31 fractured DB cusp, recurrent decay
5/22/2014	19	fract--	#19 Fractured tooth
5/22/2014	30	fract--	Fractured #30
5/23/2014	18	fract--	1) Non-restorable, fractured #18 with PAP
5/23/2014	18	fract--	1) Non-restorable fractured #18 with PAP
5/23/2014	18	fract--	1) Non-restorable, fractured #18 with PAP-extraction
5/23/2014	18	fract--	#18 fractured, non-restorable,19 rt tip
5/23/2014	19	fract--	#18 fractured, non-restorable,19 rt tip
5/23/2014	2	broke--	generalized missing teeth , broken down tooth #1 , #2
5/23/2014	3	crack--	nonrestorable cracked #3
5/23/2014	3	crack--	cracked #3
5/23/2014	3	crack--	cracked #3, grossly decayed
5/23/2014	3	crack--	cracked and grossly decayed #3
5/23/2014	3	broke--	here for broken tooth,pt points to #3
5/23/2014	3	crack--	was in pain for 3weeks before #3 cracked on Mother's day, was in excruciating apin before tooth cracked but today pain isn't as bad.
5/27/2014	18	fract--	#18 has buccal fracture and loss of buccal cusps.
5/27/2014	18	fract--	#18 buccal fracture.
5/27/2014	18	split--	Tooth #18 causing pain and split MD
5/27/2014	19	fract--	Fractured, non-restorable #19
5/27/2014	19	fract--	1) Fractured, non-restorable #19
5/27/2014	19	fract--	1) Large fracture #19

Date	Tooth	Key-No-Yes	phrase
5/27/2014	19	fract--	1) Fractured, non-restorable #19- Extraction
5/27/2014	19	fract--	Fractured, non-restorable #19
5/27/2014	20	broke--	Broken down, fractured #20
5/27/2014	20	fract--	Fractured #20
5/27/2014	21	broke--	#21 broken down with distal decay
5/27/2014	21	broke--	#21 broken down and carious.
5/27/2014	21	broke--	#21 broken down with gross decay on distal
5/27/2014	31	fract--	50yof with caries #31 with mesial cusps fractured, tooth is intermittently symptomatic and non-restorable.
5/27/2014	31	fract--	fractured and carious tooth #31.
5/27/2014	4	fract--	No restorable 4 and 5, fracture
5/27/2014	5	fract--	No restorable 4 and 5, fracture
5/29/2014	2	fract--	#2 fractured crown and mobile with a parulis lesion on the palate- nonrestorable- extraction
5/29/2014	2	fract--	#2 fractured crown and mobile with a parulis lesion on the palate
5/29/2014	2	fract--	#2 fractured crown and mobile with a parulis lesion on the palate- nonrestorable
5/30/2014	19	fract--	#19 previous endo treatment, fractured, carious, periapical radiolucency
5/30/2014	19	fract--	#19 - restoration lost, tooth has fractured.
5/30/2014	19	fract--	#19 caries/ fractured/periapical abscess
5/30/2014	19	fract--	#19 previously endo treated, fractured, carious, periapical radiolucency
6/2/2014	13	fract--root	Mesial chip on #9, caries on #28-D, Root tip #13 and fracture #14.

Date	Tooth	Key-No-Yes	phrase
6/2/2014	14	fract--root	Mesial chip on #9, caries on #28-D, Root tip #13 and fracture #14.
6/2/2014	18	fract-partial-	Multiple carious lesions, fracture with gross caries #18, caries #19, generalized severe plaque and calculus, peg laterals, distally rotated #5 and #12, impacted #11, partially erupted #6
6/2/2014	19	fract--	Distal fracture approaching pulp #19
6/2/2014	19	fract--	#19 - distal fracture, palpation (-), percussion (-), cold (+++)
6/2/2014	5	fract--	#5 - fractured lingual cusp, gross caries
6/3/2014	18	fract--	#18 and #19 have gross caries with fractured cusps
6/3/2014	2	fract--	Distal half of #2 fractured.
6/3/2014	21	fract--	fractured #21
6/3/2014	21	fract--	fractured #21
6/3/2014	28	fract--	Grossly carious, fractured, and non restorable #28
6/3/2014	28	fract--	Grossly carious, fractured #28
6/4/2014	3	fract-denture-	explained to pt the poor prognosis maxillary dentition with decay #3, fractured #4 lingual cusp and that pt will need maxillary complete denture due to generalized mobility, severe PD
6/4/2014	3	broke--	swelling and pain for 3 days, filling broke last night
6/4/2014	3	fract--	Fracture M #3.
6/4/2014	3	fract--	Fractured #3 mesial
6/4/2014	3	fract--	Mesial Fractured #3
6/4/2014	30	fract--	Fractured crown #30, unrestorable

Date	Tooth	Key-No-Yes	phrase
6/6/2014	19	fract--	#19: Gross caries with DL cusp fractured off (Palpation ++ buccal, percussion ++)
6/6/2014	3	fract--	Also discussed with pt need for full coverage crown on #30 due to risk of tooth and/or restoration fracturing again.
6/6/2014	3	broke--	S: PPTC for emergency with broken provisional bridge #13-15.
6/6/2014	3	fract--	Diagnosis Fractured enamel #23-I, #24-I
6/6/2014	3	fract--	Additonal Narrative At patient's request, repaired #23-I and #24-I with composite to alleviate sharp spots where enamel fractures were contacting his tongue.
6/6/2014	3	fract--	#3 is fractured (per endo and perio consults)
6/6/2014	3	fract--	#3 caries, distal marginal ridge fracture, sensitive to percussion, negative palpation
6/6/2014	31	fract--	#31 Most of coronal fractured due to decay
6/9/2014	2	fx--	lusal assessment and Full perio exam PDs <=6mm w/ loc BOP and localized furcation involvements Cl 1-2, mobility Cl I localized, occlusal interference upon L lat #3/31, otherwise group fxn R and L and
6/9/2014	2	broke--	Endo tx #2, broken down on distal
6/9/2014	2	broke--	Dental: Broken down endo tx #2
6/9/2014	30	fract--	#30 gross decay, lingual cusp fractured
6/9/2014	4	fract--root	#4-fractured root-non restorable
6/9/2014	4	fract--root	crown #4 fractured root
6/10/2014	2	crack--	Gross decay and cracked #2, 31
6/10/2014	3	fract--	She brought a note from the dentist she visited that stated that the mesial and distal of number 3

Date	Tooth	Key-No-Yes	phrase
			were fractured and that they would both need RCT.
6/10/2014	3	fract--	3 fractured on mesial and distal
6/10/2014	31	fract--	#31 crown fractured off
6/10/2014	31	fract--	#31 fractured - non restorable
6/10/2014	5	fract--root	#5 crown fractured off, root tips remain
6/10/2014	5	fract--root	#5 fractured crown, root tips remaining
6/11/2014	19	broke--root	crown of #19 broke off about a year ago and the root tips have been bothering her off and on for the past couple weeks
6/11/2014	2	fract--	gross decay and fractured crowns on all 2nd molars
6/11/2014	30	fract--root	Grossly carious/fractured #s 1 (retained root), 4, 5, 6, 16 (retained root), 17 (retained root), 30 (retained root), 31 (fractured to gumline), 32 (retained root).
6/11/2014	31	fract--root	Grossly carious/fractured #s 1 (retained root), 4, 5, 6, 16 (retained root), 17 (retained root), 30 (retained root), 31 (fractured to gumline), 32 (retained root).
6/12/2014	30	broke--	#30- Crown broken and missing
6/12/2014	30	fract--root	#30- Crown fractured, remaining roots, PAP present
6/12/2014	30	fract--	#30- Fractured missing crown.
6/12/2014	30	fract--	Coronal Fracture #30 M, exposed pulp
6/12/2014	30	fract--	Coronal fracture #30 M, endodontic RCT explained to the patient, patient opted to extract the tooth due to finances and desire to immediately relieve pain

Date	Tooth	Key-No-Yes	phrase
6/13/2014	19	crack--	the filling in tooth 19 cracked about two months ago and then two days ago it came out and the tooth became symptomatic
6/17/2014	15	fract--	S: pptc for oper, cc: "QUOTE", #15 fractured a couple weeks ago, no symptoms, no changes to med hx
6/17/2014	15	fract-amalgam-	A: fractured amalgam on mesial #15 with open margins on distal and lingual
6/17/2014	15	fract-amalgam-	P: took PA of #15, due to questionable prognosis of RTC and subgingival margins of existing #15 amalgam restoration, did not recommend pt invest in a crown at this time, to keep tx at this appt conser
6/17/2014	15	fract--	Grossly fractured to gumline: #s 4 and 15
6/17/2014	15	fract--	#s 4 and 15 grossly fractured to gumline, previously RCT'ed
6/17/2014	15	fract--	Grossly fractured and previously RCT'ed #s 4 and 15
6/17/2014	15	fract--	Pt advised that grossly fractured #15 is non-restorable and will require extraction.
6/17/2014	30	broke--	broken symptomatic #30-ext today
6/17/2014	30	broke--	broken symptomatic #30
6/17/2014	30	broke--	broken 30
6/17/2014	4	fract--) for EXT of previously RCT'ed and grossly fractured #4.
6/17/2014	4	fract--	Grossly fractured to gumline: #s 4 and 15
6/17/2014	4	fract--	#s 4 and 15 grossly fractured to gumline, previously RCT'ed

Date	Tooth	Key-No-Yes	phrase
6/17/2014	4	fract--	Grossly fractured and previously RCT'ed #s 4 and 15
6/17/2014	5	fract--	#5 fracture
6/17/2014	5	fract--	#15 fracture
6/18/2014	13	fract--	fractured #13, acute apical abcess
6/18/2014	13	fract--	Gross caries on #13 fractured buccal cusp, pain on palpation and percussion.
6/18/2014	18	fract--	#18 - grossly decayed and fractured on distal with PARL.
6/18/2014	18	fract--	#18 - grossly decayed and fractured on distal
6/18/2014	19	fract-amalgam-	19-MODL large fractured amalgam -watch F
6/18/2014	19	fract-amalgam-	19-MODL large fractured amalgam -watch F
6/18/2014	19	fract--	Fracture #19
6/18/2014	19	fract--root	Fractured distal root #19
6/18/2014	19	fract--root	Fracture mesial root #19
6/18/2014	30	fract--	no pariapical findings, fracture on the distal of #30
6/18/2014	30	fract--	fracture in the distal of #30
6/18/2014	30	fract--	#30 Distal caries and fracture- Restorable with possible need for NSRCT- informed pt of restoring options and patient elects to have #30 extracted
6/18/2014	30	fract--	#30 presents with fracture line on buccal and lingual
6/18/2014	30	fract--	#30 with fracture line on buccal and lingual
6/18/2014	30	fract--	Fractured tooth #30

Date	Tooth	Key-No-Yes	phrase
6/19/2014	19	broke--	endo treated #19 w/ broken crown, #3 gross decay
6/19/2014	19	broke--	endo treated #19 w/ broken crown, pulp stone in #2 & 14, #3 gross decay
6/19/2014	19	fract--	Fractured crown #19
6/19/2014	19	fract--	#19 fractured off crown
6/19/2014	29	broke--	#29 broken crown- non restorable, recommended ext
6/19/2014	29	broke--	29 has broken off crown
6/19/2014	29	fract--	#20 fractured PFM crown, #29 fractured crown & nonrestorable
6/19/2014	4	fract--root	Grossly carious/fractured #s 1 (retained root), 4, 5, 6, 16 (retained root), 17 (retained root), 30 (retained root), 31 (fractured to gumline), 32 (retained root).
6/19/2014	4	fract--	#14 - Fractured DL cusp.
6/19/2014	5	fract--root	Grossly carious/fractured #s 1 (retained root), 4, 5, 6, 16 (retained root), 17 (retained root), 30 (retained root), 31 (fractured to gumline), 32 (retained root).
6/20/2014	21	fract--	Pain at an 8/10, tooth #21, fractured for 2 months
6/20/2014	21	fract--	fractured crown #21
6/20/2014	21	fract--	Fractured crown #21
6/23/2014	12	broke--	#10 broken, #11 and #12 symptomatic
6/24/2014	15	broke--	#14 and #15 carious, broken down crowns.
6/25/2014	13	broke--	#13 severely broken down.
6/25/2014	13	broke--	#1, 16, 32 impacted, #3 broken restoration, #13 restoration MO fell out

Date	Tooth	Key-No-Yes	phrase
6/25/2014	14	broke--	#19, #14 Gross caries/broken crowns, multiple other carious lesions.
6/25/2014	18	fract--	#18 tooth fractured on mesio lingual surface
6/25/2014	18	fract--	#18 fractured
6/25/2014	19	broke-amalgam-	#19 w/ History of DO amalgam, gross caries and broken restoration.
6/25/2014	19	fract--	Grossly carious #19 (grossly decayed/fractured to gumline).
6/25/2014	2	broke--	Broken shoulder 2 screws placed 2013, patient states no pre-med was discussed prior to den
6/25/2014	20	broke--	Pt reports remote hx of LL gingival swelling associated with broken down tooth (points to #20) but states
6/25/2014	30	fract--	36 yom present to clinic with a fractured 30 with severe pain
6/26/2014	12	fract--	Caries and fractured #12
6/26/2014	12	broke--	Caries and broken teeth #12, 19, 30.
6/26/2014	12	fract--	Carious and fractured #12
6/26/2014	19	fract--	fractured #19
6/26/2014	3	broke--	Broken down, non restorable 3, 4, and 5
6/26/2014	3	broke--	dental - broken down, non restorable 3, 4, and 5
6/26/2014	3	broke--	broken down, non restorable 3, 4, and 5
6/27/2014	14	broke--	#14 Gross caries, broken down crown.
6/27/2014	2	fract--	Caries and fractured restoration #2
6/30/2014	14	fract--	fractured #14 at the gum line
6/30/2014	14	fract--	fractured #14

Date	Tooth	Key-No-Yes	phrase
6/30/2014	14	fract--	#14 fractured at the gum line and the gingiva around it is inflamed
6/30/2014	19	fract--	fractured, symptomatic #14, 19.
6/30/2014	19	broke--	broken 19
6/30/2014	19	broke--	broken tooth 19
6/30/2014	3	split--root	extracted #3 - split roots, used periotomes to remove roots
7/1/2014	12	fract--	#12-fractured crown
7/1/2014	12	fract--	#12-fractured crown-EXT w/ LA
7/1/2014	15	broke--	Hard tissue exam (Findings) #6 has leaking facial resin; #15 does not have much retention thats why the crown is falling off; #19 has loose filling needs eval for new restoration MODL broken at dista
7/1/2014	19	broke--	#19 & #20 crowns broke off a few weeks ago while chewing.
7/1/2014	20	broke--	#19 & #20 crowns broke off a few weeks ago while chewing.
7/1/2014	3	fract--	#3 Fractured DL cusp
7/1/2014	3	fract--	#3 Fractured recurrent decay
7/1/2014	3	fract--	#3 Fractured recurrent decay--EXT
7/1/2014	5	fract--root	- #s 5 and 6 - fractured to gumline with retained roots
7/1/2014	5	fract--root	#s 5 and 6 fractured to gumline with retained roots
7/1/2014	5	fract--	#5 - fractured to gumline
7/2/2014	15	fract--	Fractured #15

Date	Tooth	Key-No-Yes	phrase
7/2/2014	15	fract--	Fractured #15-unrestorable, recommended ext
7/2/2014	15	fract--	Fractured #15-extr
7/2/2014	18	fract--	Fractured #18
7/2/2014	18	fract--	Dental: #18 PARL, fractured crown/ unrestorable
7/2/2014	30	fract--	#30 Fractured restoracion restorable tooth
7/2/2014	30	fract--	patient comes with a fractured restoration that causes pain on #30 with sensitivity to percussion
7/2/2014	30	fract-amalgam-	#30 MODBL fractured amalgam, #2 O caries, maxillary tori
7/2/2014	30	fract-amalgam-	#30 MODBL fractured amalgam w/ PARL
7/2/2014	30	fract-amalgam-	Dental: #30 MODBL fractured amalgam, #2 O caries.
7/2/2014	31	fract--	Fractured #31 with caries
7/2/2014	31	fract--	fractured tooth #31
7/2/2014	31	fract--	Fractured #31, tooth restorable w/ probable endo/crown, pt elects to ext
7/2/2014	31	fract--	dental: fractured #31 - EXT with LA
7/2/2014	5	broke--	tooth broke 5 weeks ago and started to be sensitve this morning.
7/3/2014	14	broke--	#14 - inflamed tissue on buccal gingiva - possibly where abcess broke through
7/3/2014	15	fract--	#15 fractured, gross caries
7/3/2014	19	fract--	#18 and #19 have gross caries with fractured cusps
7/3/2014	19	fract--	#29, 30, 31, 19, 12, 13 fractured crowns.
7/3/2014	19	fract--	Fractured crown on #19

Date	Tooth	Key-No-Yes	phrase
7/3/2014	19	fract--	#19 fractured crown.
7/3/2014	19	fract--	Dental: #19 - positive bite stick test indicating probable fracture
7/3/2014	19	fract--	#19 fractured tooth - MD fracture
7/3/2014	2	fract--	Fractured #2, #15
7/7/2014	30	fract--	Fractured tooth #30.
7/7/2014	30	fract--vertical	Tooth #30 with vertical fracture extending from the mesial marginal ridge to the distal marginal ridge with loss of the DL cusp and the fracture extending down to the alveolar bone.
7/8/2014	13	broke--	Broken Left Femur 2013
7/8/2014	2	fract--	A: MB, DB cusps of #2 fractured.
7/8/2014	2	fract--	A: Fractured restoration on #2.
7/8/2014	2	broke--	S: PPTC with broken #32 and POE.
7/8/2014	2	fract--	A: Fractured restoration on tooth #32.
7/8/2014	2	fract--	Small fractured restoration on #2 (less of a priority than #32)
7/8/2014	20	fract--	Fractured tooth #20
7/8/2014	20	fract--	Tooth #20 fractured 10 days prior from eating chips
7/8/2014	20	fract--root	Pt presented from undergrad clinic for removal of root tip #20 after crown fracture.
7/8/2014	3	fract--root	#3 Carious lesion DB and root fracture
7/8/2014	5	fract--root	Root tip #5 after crown fracture
7/9/2014	12	fract--root	#4 caries,#12 Root fracture
7/9/2014	12	fract--root	#12 has mobile lingual cusp, possible root fracture.

Date	Tooth	Key-No-Yes	phrase
7/9/2014	18	crack--	#18 crack
7/9/2014	18	crack--	took PA #18, crack on the DL cusp, its visible clinica;y.
7/9/2014	18	fract--root	Endo consult with Dr -- determined #18 nonrestorable with likely fracture of mesial root, PD of 10 mm on MB root.
7/9/2014	31	broke--	This tooth is broken down(Points to #31)
7/9/2014	31	broke--	S: "QUOTE" Patient points to #31.Tooth has been broken for the past year, it only hurts under pressure, no swelling noted by pt, no fever, no trouble swallowing.
7/9/2014	4	fract--root	#4 caries,#12 Root fracture
7/10/2014	18	fract--	#18 fractured crown and generalized decay, sensitive to percussion and cold, no palpation sensitivity
7/10/2014	18	fract--root	generalized bone loss, generalized caries, root tips #31, carious lesion #30, #18 fractured crown and caries
7/10/2014	18	fract--root	Dental: generalized bone loss, generalized caries, root tips #31, carious lesion #30, #18 fractured crown and caries
7/10/2014	19	fract--	Fractured crown on #19 with previous RCT
7/10/2014	19	fract--	fractured crown #19
7/10/2014	19	fract--	Endo treated #19, crown fracture to furcation
7/10/2014	20	broke--	Broken down #20
7/10/2014	20	fract-clasp-	Because of the fractured lingual cusp on #20 the retentive clasp arm is not adpting snugly to tooth #20.

Date	Tooth	Key-No-Yes	phrase
7/10/2014	20	fract--	Patient also presented with fractured #20 which is planned for EXT at next apPt Referral to grad perio for evaluation of deep probing depths across the maxilla.
7/10/2014	20	fract--	#20 fractured to gingiva
7/10/2014	20	broke--	Tooth #20 non-restorable broken to gum
7/10/2014	20	fract--	Dental: #20 fractured to gingivae
7/10/2014	30	fract--	#30 tender to palpation, distal fracture into the dentin, approaching the pulp in the radiograph
7/10/2014	30	fract--	#30 gross decay/fracture, approaching the pulp
7/10/2014	30	fract--	#30 crown fractured on the distal during ext of #31 and and grossly carious.
7/10/2014	30	fract--	#30 - fractured lingual surface.
7/10/2014	31	fract--	S: PPTC with fractured #31 and #13
7/10/2014	31	fract--root	#31 fractured with distal decay which is creeping down the root.
7/10/2014	31	fract--	#31 fractured restoration 4 months ago while eating.
7/10/2014	31	fract--	#31 gross caries, fractured restoration
7/10/2014	31	fract--	#30 crown fractured on the distal during ext of #31 and and grossly carious.
7/11/2014	14	fract--	Abfraction of #3,5,12,13,14,28,29.
7/11/2014	2	fract--	Distal portion of #2 crown grossly fractured to gumline.
7/11/2014	2	fract--	#2 - fractured/decay on distal surface of crown
7/11/2014	2	fract--	- Fractured, non-restorable #2

Date	Tooth	Key-No-Yes	phrase
7/11/2014	30	fract--root	#30 fractured DB cusp, widening of PDL space and small periapical lesion on mesial root
7/11/2014	30	fract--	#30 fracture of DB cusp and decay present
7/14/2014	14	fract--	fracture due to gross caries #14
7/14/2014	14	fract--	#14 Fracture line down lingual.
7/14/2014	15	broke--	15 broken down crown, most painful tooth, Purulence could be expressed at buccal gingiva of #15.
7/14/2014	19	crack--	Gross caries on #19 and cracked endo treated #30
7/14/2014	30	fract--	1) #30-Fracture- mesiodistally
7/14/2014	30	fract--	#30- fractured, non-restorable
7/14/2014	30	fract--	Fractured/carious #30.
7/14/2014	30	fract--	#30 MB fracture due to gross caries
7/14/2014	30	fract--	#30-gross caries, fracture.
7/14/2014	30	fract--	Pt points to LR back tooth (#30), states the tooth is fractured.
7/14/2014	30	fract--	51 yo F referred by GP FP for evaluation and extraction of fractured, non-restorable tooth #30.
7/14/2014	30	fract--vertical	Tooth #30 with vertical fracture extending through the furcation and gross mobility of the DL cusp.
7/14/2014	30	fract--	Fractured, symptomatic tooth #30.
7/14/2014	30	fract--	PA: Fracture tooth #30 with fracture extending through the furcaion with peri-furcal radiolucency.
7/15/2014	14	fract--	#14 fracture 2-3 months ago and the pain been consistant since then.

Date	Tooth	Key-No-Yes	phrase
7/15/2014	18	fract--	ML cusp fracture on #18, unrestorable without endo/crown
7/15/2014	18	fract--	#18 fractured a day ago
7/15/2014	18	fract--	#18 fractured, RCT therapy with temporary filling
7/16/2014	18	fract--	#18 DL cusp fracture to gingival margin, gross caries
7/16/2014	18	broke--	#18 broken, generalized caries
7/16/2014	18	fract--	#18 DL cusp fracture to gingival margin, gross caries, unrestorable
7/16/2014	2	fract--	Patient concerns include: #9 MLFI restoration (done when you were much younger:), #8 with fracture on facial surface but wants to clean it first and see what it look like and #20, crown came off abou
7/16/2014	2	broke--	consult for 20, broken down, caries, endo tooth.
7/16/2014	2	broke--	pt recently broke 2 to gum line.
7/16/2014	2	fract--	Patient currently has a treatment plan for restorative procedures, crown for #14 and implant for #2 (severely fractures and currently requiring extraction with Dr on 7/16/2014).
7/16/2014	2	fract--	Fracture decay on #2D
7/16/2014	3	fract--	1) #3- Large fracture with temporary restoration- non-restorable
7/16/2014	30	fract--	Fractured crown with gross decay #30.
7/16/2014	30	fract--	Fractured crown, PAP #30 and gross decay #30.
7/17/2014	14	fract--	#14 crown fractured to level of bone
7/17/2014	14	fract--	Crown on #14 completely fractured around a week ago.

Date	Tooth	Key-No-Yes	phrase
7/17/2014	14	fract--	#14 crown fractured to level of bone, unrestorable
7/17/2014	14	broke--	#14: broken filling mesial
7/17/2014	14	broke--	#14: broken filling mesial- restorable w/ endo/crown, pt elects to ext
7/17/2014	18	fract--	#18: crown fractured to gumline
7/17/2014	18	fract--	#18 crown fractured to gumline
7/17/2014	18	fract--	#18 crown fractured last year
7/17/2014	18	fract--	#18: crown fractured to gumline- non restorable
7/17/2014	3	fract--	Caries lesion/fracture OB on #3, with pulpal involvement.
7/18/2014	13	broke--	13 broken down crown, slightly painful.
7/18/2014	13	fract--	#13, 16, 18, 30 coronal fractures
7/18/2014	14	broke--	#14 crown broken at gum-line to furcation
7/18/2014	14	broke--	#14 crown broken at gum-line to furcation, unrestorable
7/18/2014	19	broke--	She will have dental insurance coming through and although #19 is broken down, it has been broken down for several years and is not bothering her.
7/18/2014	19	fract--	Dental History Implant consult- fractured #19
7/18/2014	19	fract--root	only over gingiva created, upto but not past the mucogingival junction, reflected flap, extracted #19 by sectionied with 702 bur, removed roots, superior buccal plate fracture, placed 1 cc of puros a
7/18/2014	21	fract--	1) Fractured non-restorable #21- extraction
7/18/2014	21	fract--	1) Fractured non-restorable #21

Date	Tooth	Key-No-Yes	phrase
7/18/2014	21	fract--	#21 Fractured non-restorable
7/18/2014	31	fract--	Fractured crown with gross decay #31.
7/18/2014	31	fract--	#31 Fractured crown & gross decay.
7/21/2014	14	fract--	#14 fractured
7/22/2014	15	fract--	#15 - fracture
7/22/2014	15	fract--	#15 - fractured DL surface.
7/22/2014	30	fract--	#30 lingual fracture (restorable with endo/crown, pt elect to ext).
7/22/2014	30	fract--	#30 fractured L
7/22/2014	30	fract--	#30 ML and DL cusp fracture.
7/23/2014	19	broke--	Pt noted that #19 broke recently.
7/23/2014	19	broke--	Tooth #19 severely broken down with associated PARL.
7/23/2014	19	broke--	Broken down tooth #19 with associated PARL.
7/23/2014	19	broke--	Broken down #19.
7/23/2014	19	fract--	Caries/Fracture 19
7/23/2014	31	broke--	Broken crown #31.
7/23/2014	31	fract--	Fractured tooth #31.
7/23/2014	31	fract--	-Fractured and symptomatic #31.
7/23/2014	31	fract--	#31- fractured lingual cusp
7/24/2014	14	fract--	#14-M fractured restoration
7/24/2014	14	fract--	Dental: #14-M fractured restoration.
7/24/2014	14	fract--	#14 caries and fractured restoration

Date	Tooth	Key-No-Yes	phrase
7/24/2014	2	fract--	2xXXX pigmented lesion on L anterior maxillary edentulous ridge: possible oral melanotic macule, 1x1cm ulceration on the R lateral border of the tongue consistent with trauma due to fractured 30, 1x2c
7/24/2014	2	fract--	2xXXX pigmented lesion on L anterior maxillary edentulous ridge: possible oral melanotic macule, 1x1cm ulceration on the R lateral border of the tongue consistent with trauma due to fractured 30, 1x2c
7/25/2014	18	fract-partial-	Caries #20, #4, #14, #16, #19, #31, partially impacted #17 and #32, fractured #18, ectopic eruption #7
7/25/2014	18	fract--	Dental: Grossly decayed and fractured #18, sensitive to percussion hot/cold.
7/25/2014	4	fract--	#4 lingual crown fracture, percussion sensitive.
7/25/2014	4	fract--	Dental:fractured lingua crown #4- non restorable-recommend ext
7/28/2014	31	fract--	Fractured tooth #31.
7/28/2014	31	fract--	Dental- Referred from outside dentist for ext fractured #31 under LA.
7/29/2014	12	fract--	Grossly fractured/decayed #s 4, 5, 7, 8, 9, 10, 11, 12, 13.
7/29/2014	13	fract--	Grossly fractured/decayed #s 4, 5, 7, 8, 9, 10, 11, 12, 13.
7/29/2014	15	fract--	1.#15 gross caries, fractured crown- pt aware tooth could be restored w/ endo/crown, pt elects to ext
7/29/2014	15	fract--	#15 gross caries, fractured crown
7/29/2014	2	fract--	Grossly fractured/decayed #s 4, 5, 7, 8, 9, 10, 11, 12, 13.

Date	Tooth	Key-No-Yes	phrase
7/29/2014	28	fract--	Distal fracture #28 with gross caries.
7/29/2014	29	fract--	Fractured tooth #29 (possibly restorable)
7/29/2014	29	fract--	Fractured tooth #29, symptomatic
7/29/2014	29	fract--	Extraction of fractured/symptomatic tooth #29 under LA, without epinephrine (secondary to tachycardia and unknown cardiac issue that appears benign according to cardiologist).
7/29/2014	3	fract--	Grossly fractured/decayed #s 4, 5, 7, 8, 9, 10, 11, 12, 13.
7/29/2014	4	fract--	Grossly fractured/decayed #s 4, 5, 7, 8, 9, 10, 11, 12, 13.
7/29/2014	5	fract--	Grossly fractured/decayed #s 4, 5, 7, 8, 9, 10, 11, 12, 13.
7/30/2014	15	crack--	Cracked tooth #15
7/30/2014	15	crack--	Cracked tooth #15 Non-restorable (Referral from grad endo by Dr)
7/30/2014	15	fract--	fractured #7, 8, 15
7/30/2014	15	fract--	fractured #15
7/30/2014	15	fract--	fractured/irreversible pulpitis #15
7/30/2014	15	fract--	fractured tooth #15
7/31/2014	19	fract--	Fractured tooth #19
7/31/2014	19	fract--	#19 DL cusp fractured
7/31/2014	19	fract--	Fractured tooth #19 (DL cusp)
8/1/2014	14	broke--	Broken down carious #3/14/20/29/30
8/1/2014	31	fract--	fractured #31
8/1/2014	4	fract--	#4 Fractured tooth non-restorable

Date	Tooth	Key-No-Yes	phrase
8/4/2014	31	fract--	#31 large DL fracture with caries
8/4/2014	31	crack--	This tooth is cracked and it hurts (31)
8/4/2014	31	fract--	#31 fractured 1 year ago.
8/5/2014	13	fract--	A small portion of the D of 13 fractured (undermined enamel from large decay).
8/5/2014	2	fract--	#2 fractured/nonrestorable
8/5/2014	30	fract--	#30 MODL fracture with caries
8/5/2014	30	fract--	#30 Large MODL fracture with clinical caries
8/5/2014	30	fract--	#30 has been fractured for 9 years and presents with clinical caries MODL.
8/5/2014	30	fract--	Fractured #30
8/6/2014	13	fract--	Fractured crown #13
8/6/2014	19	crack--	Follow-up 8/6 in GP for evaluation of possible crack #19
8/6/2014	19	crack--	1 .#19 Sensitive to biting, possible crack on buccal
8/6/2014	19	crack--	Cracked tooth #19
8/7/2014	2	fract--	Grossly carious tooth #2, caries/fractured restoration #30, generalized caries.
8/7/2014	31	fract--	I/O Fracture MLC #31, about 1 mm above crestal bone, recurrent caries, asymptomatic to Pressure and percussion.
8/7/2014	31	fract--	A: {15} year old {aa male}, ASA {1} , hx of {benign murmur} , fractured ML cusp #31, MTA pulp
8/7/2014	31	broke--	19 yo M presents for evaluation of broken tooth #31.

Date	Tooth	Key-No-Yes	phrase
8/8/2014	19	fract--	Fractured DO composite #19 with recurrent decay.
8/8/2014	19	fract--	Brief examination revealed core #19 still in place, however small DB portion of restoration had fractured.
8/8/2014	19	fract--	TX: Assesment of #19 - core remains in place with fractured DB portion, no signs of decay noted.
8/8/2014	19	fract--	tooth #19 fractured over a year ago, pt has been applying orajel to site, but it is no longer effective, pt went to hospital in Manassas on 8/2/14 for pain and was prescribed penicillin and tramadol,
8/8/2014	19	fract--	fracture on #19
8/8/2014	19	fract--	fractured #19
8/8/2014	19	fract--	pt presented with #19 fractured, pt requested ext rather than RCT, anesthesia obtained via IAN block and LBN block with supplemental PDL, papillary, and pulpal injections, tissue separated with perios
8/8/2014	3	fract--	#3 symptomatic, fractured, and worn down into dentin
8/8/2014	31	fract--	31 has been fractured for about a year, pain began 2 weeks ago and is intermittent.
8/8/2014	4	fract--	Patient stated she went to general dentist because #4 crown fractured and dentist suggested getting a bridge.
8/8/2014	4	fract--	Hard Tissue DX #4 fractured crown
8/11/2014	15	fract--	During extraction of #15, crown of #16 fractured.
8/11/2014	19	fract--root	No root fracture visible on #19.

Date	Tooth	Key-No-Yes	phrase
8/11/2014	31	crack--	#31 Crack on buccal and mesial.
8/11/2014	31	crack--	#31 Visible buccal crack in crown.
8/12/2014	15	fract--	Gross decay #15 ML fracture
8/12/2014	15	fract--	#15 Gross caries and fractured ML
8/12/2014	19	fract--	#19 fractured crown
8/12/2014	19	fract--	#19 fractured crown (non-restorable)
8/12/2014	19	fract--	#19 fractured crown.
8/12/2014	2	fract--	#2- gross decay/fractured (percussion sensitive)
8/12/2014	30	broke--	S: PPTC for exam with CC of upper right tooth broken (#6) and lower left tooth broken (#30).
8/12/2014	30	fract--	Dental History #30 fractured around 8months.
8/12/2014	31	fract--	fractured and gross caries #31
8/12/2014	31	fract--	#20 and 31- fractured and gross caries with PARLs
8/12/2014	31	fract--	#20, #31 fractured buccal cusps with gross caries
8/12/2014	4	fract-elevat-	#4 Non-restorable tooth- Elevated, fractured crown with forceps, bone troughed out around buccal and distal of tooth, tooth delivered with elevator
8/13/2014	13	fract--	A: Lingual half of #13 fractured to gumline.
8/13/2014	13	fract--	A: #13 lingual part of crown fractured off with gross caries.
8/13/2014	30	fract--	Defective Restorations: #30fractured, has been that way a long time
8/13/2014	4	fract--	Fractured restoration #4 with abfraction lesion
8/13/2014	4	fract--	Fractured/carious teeth #s 4, 19, 28

Date	Tooth	Key-No-Yes	phrase
8/13/2014	4	broke--	Patient points to #4 and says "it broke during a cleaning and I just want it taken out".
8/14/2014	2	fract--	#2 fractured crown
8/14/2014	2	fract--root	#2 fractured, retained roots
8/14/2014	28	fract--	#28-30 fractured at gum line
8/14/2014	3	fract--	#13 crown is fractured.
8/14/2014	3	fract--	Surgical extraction of #13, small buccal flap, crown fractured during ext.
8/14/2014	3	fract--	#28-30 fractured at gum line
8/14/2014	30	fract--	#28-30 fractured at gum line
8/15/2014	19	fract--	fractured crown #19
8/15/2014	19	fract--	19 - Fractured tooth
8/15/2014	19	fract--	fractured #19
8/15/2014	19	fract--	fractured/carious #19 extending into pulp
8/15/2014	19	fract--	fractured/carious #19- extraction
8/15/2014	19	fract--	fractured carious #19
8/18/2014	31	fract--	#31 caries, fractured- EXT
8/18/2014	31	fract--	#31 caries, fractured
8/19/2014	2	fract--	#2 D cusp fracture, pulpitis- tooth could be restored w/ endo/crown, pt elects to ext
8/19/2014	2	fract--	#2 D cusp fracture.
8/20/2014	12	broke--	Badly broken down teeth #4, 6, 7, 8, 9, 10, 12, 19, 21-27, 29.
8/20/2014	14	fract-amalgam-	Fractured previous amalgam restoration #14 with recurrent decay.

Date	Tooth	Key-No-Yes	phrase
8/20/2014	14	fract--	#14 Fractured with recurrent decay.
8/20/2014	14	fract--	Fractured #14
8/20/2014	14	fract--	Fractured tooth #14
8/20/2014	4	broke--	Badly broken down teeth #4, 6, 7, 8, 9, 10, 12, 19, 21-27, 29.
8/21/2014	15	fract--	#15 nonrestorable fractured crown
8/21/2014	15	fract--	#15 RL crown consistent of fractured crown, apical RL
8/21/2014	15	fract--	#15 fractured crown, nonrestorable
8/21/2014	15	fract--	#15 fractured crown, nonrestorable, symptomatic to percuss/palpation, apical RL
8/21/2014	2	fract--	Grossly carious/fractured tooth #2, non-restorable
8/21/2014	20	fract--	#10,20, 21 fractured
8/21/2014	21	fract--	#10,20, 21 fractured
8/21/2014	4	fract--	#4 distal caries, possible fractured restoration, symptomatic to percuss, 7/10 pain level
8/22/2014	18	fract--	DL cusp of #18 fractured with caries.
8/22/2014	29	fract--	#29 presents w/ gross decay and fractured restoration.
8/22/2014	29	fract--	Caries at #29 w/ 4 mth hx of fractured restoration.
8/22/2014	29	fract--	Fractured cusp/gross caries #29
8/22/2014	29	fract--	Most likely hyperkeratotic tissue associated w/ sharp edge of fractured tooth #29.
8/25/2014	13	split--	surgical extraction of 13 14 15 16 31, FTMPF, reflected tissue, split teeth with hand instrument, extracted teeth without complication

Date	Tooth	Key-No-Yes	phrase
8/25/2014	14	split--	surgical extraction of 13 14 15 16 31, FTMPF, reflected tissue, split teeth with hand instrument, extracted teeth without complication
8/25/2014	15	split--	surgical extraction of 13 14 15 16 31, FTMPF, reflected tissue, split teeth with hand instrument, extracted teeth without complication
8/25/2014	2	fract-amalgam-	#2 existing MOD amalgam restoration fractured with recurrent caries.
8/25/2014	2	fx--	Fractured teeth: #2 DB cusp FX (missing) to gum-line
8/25/2014	2	fx-partial-root	Due to Fx tooth structure, current caries involvement, poor crown-to-root ratio, and only partial functioning occlusion against opposing tooth, the recommendation was given to Pt to EXT #2.
8/25/2014	31	split--	surgical extraction of 13 14 15 16 31, FTMPF, reflected tissue, split teeth with hand instrument, extracted teeth without complication
8/26/2014	12	fract--	#12: fracture crown and unrestorable ++ percussion and + palatal to palpation
8/26/2014	3	broke-amalgam-	Broken amalgam restoration/carious#3
8/26/2014	3	broke-amalgam-	#3 broken amalgam restoration on DL and recurrent carious lesion in pulp proximity- tooth is restorable w/ endo/crown, pt elects to ext
8/26/2014	3	broke--	Broken restoraion and extesive carious lesion in pulp proximity #3
8/26/2014	3	broke-amalgam-	Broken amalgam restoration DL of the crown #3
8/26/2014	3	broke--	Tooth #3 broken crown about a year and half ago.

Date	Tooth	Key-No-Yes	phrase
8/26/2014	5	fract--	traumatic ulceration on R buccal mucosa adj to fracture #5, most likely due to sharp edge of tooth #5.
8/26/2014	5	fract--	#5: fracture crown\ unrestorable percussion ++ and negetive to palpation.
8/26/2014	5	fract--	#15 fracture crown\ negetive to percussion
8/27/2014	18	fract--root	#18 mesial root fracture
8/27/2014	19	broke--	#19 Broken crown and carious lesion on D
8/27/2014	2	fract--	Swelling upper right maxilla, fractured crown #2- non restorable
8/27/2014	2	broke--root	Multiple root tips present, carious and broken #2
8/27/2014	21	fract--	Fractured crown #21
8/28/2014	14	fract--	Carious and fractured #14
8/28/2014	18	fract--	Dental findings: fractured #18, primary and secondary caries
8/28/2014	18	fract--root	#18 fractured restoration and root
8/28/2014	18	fract--	#18 restoration fractured 7-8 months ago denies pain or swelling
8/28/2014	3	fract--	#9 coronal fracture, happened 3 weeks ago, patient does not report any pain or sensitivity associated with the tooth.
8/28/2014	31	fract--vertical	A: #31 (abscess present on MB and DB line angles of gingiva and vertical fracture MD), #14 DOBL repl
8/28/2014	5	broke--	#5 Crown was broke on last Dec
8/28/2014	5	broke--	#5 broken restoration and extesive current carious/ pain on percussion

Date	Tooth	Key-No-Yes	phrase
8/28/2014	5	broke--	#5 broken crown and extensive carious lesion/ PARL
8/29/2014	14	fract--	A: Fractured and carious #14 DL.
8/29/2014	14	fract--	Dental History Fractured DL #14 x1.5wks
8/29/2014	4	fract--	#4 fractured
8/29/2014	4	fract--root	#4 -patient was informed about the fracture of the tooth and offered the option to restore the tooth with root canal , crown lengthening ,crown , patient elected to extract the tooth
9/3/2014	14	fract--	DE: Dr: Buccal portion of #14 fractured, #30 remains severely fractured, please evaluate both teeth for restorative or replacement, #3 DF decay
9/3/2014	14	fract--	The MB and DB cusps of #14 have fractured off within the past few months.
9/3/2014	14	fract--	#14 MB, DB cusps fractured to below the gingiva.
9/3/2014	14	broke--	A: Temporary crown from #11-14 broke at #11.
9/3/2014	14	broke--	S: Pt's provisional broke at #14.
9/3/2014	14	broke--	Intraoral: Moderate swelling UL with sutures in place, 4 unit bridge broken from #11-#14 with #11 broken provisional crown on MIFL surfaces, #14 pink Triage provisional intact
9/3/2014	14	fract--	Estrablished patient presents to clinic with a fractured provisional bridge #12 to #14.
9/3/2014	14	fract--	Established patient presents to clinic with CC of fracture provisional bridge #11 to #14.
9/3/2014	19	broke--	#31 broken with gross decay- decay also noted on #s19 and 30 (pt informed)
9/3/2014	19	fract--	Carious fractured 19.

Date	Tooth	Key-No-Yes	phrase
9/3/2014	30	broke--	#31 broken with gross decay- decay also noted on #s19 and 30 (pt informed)
9/3/2014	30	fract--	#3 fractured ML cusp, #30 fractured DB (nonrestorable)
9/4/2014	12	fract--	watch abfraction lesions on B of #12-13
9/4/2014	12	fract--	#12 fractured crown off, patient informed
9/4/2014	12	fract--	P: #12 fractured crown off a month ago, patient informed that the tooth needs to come out.
9/4/2014	12	fract--	Dental History Fractured #12 three weeks ago while eating.
9/4/2014	12	fract--	decayed and fractured #12
9/4/2014	12	fract--	my tooth fractured, points to #12
9/4/2014	29	fract--vertical	Dental: Vertical root fracture #29 that is endo treated with a post and PFM crown placed.
9/4/2014	29	fract--vertical	Vertical fracture noted on the distal of #29
9/5/2014	13	fract--	#13 fractured D+ pain on percussion
9/5/2014	19	fract--	#19- Pulpally deep restoration #19, no caries or obvious fracture
9/5/2014	2	crack--	Patient says the one with a big hole in it is bothering the patient the most (points to #2) and the one with the crack (#3) he would like out at the next apPt 7/10 pain today.
9/5/2014	2	fract--	#20 large carious lesion, #16 fractured cusp and sensitive to percussion and palpation
9/5/2014	2	fract--	Patient states #2 has been fracturing more and more since her las
9/5/2014	29	fract--root	Fractured #25-27, Root caries #29
9/8/2014	12	fract--vertical	#12 vertical root fracture nonrestorable

Date	Tooth	Key-No-Yes	phrase
9/8/2014	15	broke--	Pt also noted that a tooth had broken in the ULQ (#15) a few weeks ago but w
9/8/2014	19	fract--	#19 RL crown consistent with Fractured crown, gross caries
9/8/2014	19	fract--	#19 Fractured crown, gross caries, palpation sensitive
9/8/2014	19	fract--	#19 Fractured crown, gross caries,
9/8/2014	19	fract--	#19 Gross decay, fractured crown.
9/8/2014	19	fract--	#19 fractured crown, gross decay.
9/8/2014	19	fract--	#19 crown fracture, gross decay
9/8/2014	4	crack--	#4 cracked
9/8/2014	5	fract--	Large fracture #5.
9/9/2014	13	broke--root	Generalized broken down teeth with root tips remaining #3, #8, #9, #10, #13, #15,
9/9/2014	14	fract--	A: Fractured 5 and 14 with draining abcess at the gumline.
9/9/2014	19	broke--	#19 crown broken, symptomatic apical periodontitis
9/9/2014	5	fract--	A: Fractured 5 and 14 with draining abcess at the gumline.
9/10/2014	13	crack--	MD crack on pulpal floor #13.
9/10/2014	13	crack--	Told patient to brush with sensodyne and if there is no improvement we would have to consider the crack in #13 or other possible causes.PT understood.
9/10/2014	13	crack--	Pt has cracked tooth #13 along lingual margin of MOD.
9/10/2014	19	fract--	Fractured, carious non restorable 19 and 30.

Date	Tooth	Key-No-Yes	phrase
9/10/2014	30	fract--	Fractured, carious non restorable 19 and 30.
9/11/2014	20	fract--	#20 caries, #8 fracture
9/11/2014	30	fract-porcelain-	Slight porcelain fracture on #30-M.
9/12/2014	18	fract--	#18 Coronal fracture
9/12/2014	18	fract--	#18 Coronal fracture, (+) perc (-) palp no swelling drainage
9/12/2014	2	fract--	3 years ago fractured arm treated in a nonsurgical procedure and to give birth, 2005 and 2008 underwent C section on both
9/15/2014	13	broke--	Grossly carious #13 with broken cusp - non restorable
9/15/2014	19	fract--	#19-D fractured off.
9/15/2014	19	fract--	Large caries, fractured #19
9/15/2014	19	fract--vertical	S: Pt last seen in grad endo where #19 was deemed unrestorable due to suspected vertical root fracture and apical radiolucency on M and D roots.
9/15/2014	3	fract--	fractured MB and ML cusps on #3, sensitive to percussion
9/15/2014	3	fract--	gross decay #3 and crown fracture
9/15/2014	30	broke--	#30 presents with broken MB cusp with gross decay inside.
9/15/2014	31	fract-porcelain-	Complete fracture #30 porcelain facing, FPD #29-31 margins sealed and acceptable, occlusion verified.
9/15/2014	31	fx--	O: BP: 114/62, HR: 62, H&N exam (WNL), Intraoral Fx: Caries #31 MB, Radiology Fx: n/a
9/15/2014	31	split--root	split crown and roots of #31

Date	Tooth	Key-No-Yes	phrase
9/16/2014	18	fract--	Gross caries #18 - ML and DL cusps fractured off
9/16/2014	31	fract--	Fractured crown: #31 w/ hx of draining fistula.
9/16/2014	31	fract--	#31: fractured crown at gingival margin.
9/16/2014	31	fract--	#31: crown fractured crown, PAP
9/16/2014	5	fract--root	Hard tissue exam (Findings) Dental Exam as per Dr : Radiographs reviewed and noted a fracture on the root of tooth #5.
9/16/2014	5	fract--root	Radiograph Findings PA of #5 was taken today and noted a fracture on the root surface.
9/16/2014	5	fract--root	Radiographs reviewed and noted a fracture on the root of tooth #5.
9/17/2014	13	fract--	Fractured #13.
9/17/2014	13	fract--	Fractured #13
9/18/2014	14	broke--root	-Severely broken down #3, and #14, and root tips #4 and #9.
9/18/2014	14	broke--	Broken down #3, #14.
9/18/2014	18	broke--	Dental -Broken down tooth #18
9/18/2014	18	fract--	#18 fractured, "QUOTE"
9/18/2014	18	fract--	Fractured lingual cusp of tooth #18
9/18/2014	18	fract--	#18 fractured cusp and acute symptomatic pain-tooth is restorable w/ endo/crown, pt elects to ext
9/18/2014	19	broke--	Badly broken down teeth #4, 6, 7, 8, 9, 10, 12, 19, 21-27, 29.
9/18/2014	19	fract--	Large carious lesion and fractured cusp of #19.
9/18/2014	20	fract--	#20: fractured.
9/18/2014	20	fract--	fractured #20.

Date	Tooth	Key-No-Yes	phrase
9/18/2014	20	fract--	Fractured of #20.
9/18/2014	21	broke--	Badly broken down teeth #4, 6, 7, 8, 9, 10, 12, 19, 21-27, 29.
9/18/2014	29	fract--	Patient had temporary crown #29 fractured and dislodged.
9/18/2014	29	broke--	Badly broken down teeth #4, 6, 7, 8, 9, 10, 12, 19, 21-27, 29.
9/18/2014	3	broke--root	-Severely broken down #3, and #14, and root tips #4 and #9.
9/18/2014	3	broke--	Broken down #3, #14.
9/18/2014	4	broke--root	-Severely broken down #3, and #14, and root tips #4 and #9.
9/18/2014	4	broke--	Broken down #3, #14.
9/19/2014	18	fract--	#18 gross caries with fractured lingual cusp
9/19/2014	19	fract--	#19 gross caries and D fracture
9/19/2014	3	fract--horizontal	Horizontal root fracture #3
9/19/2014	30	fract--	#30 fractured MB and ML cusps, carious
9/19/2014	30	fract--	caries and fractured cusp #30
9/19/2014	30	fract--	#30 fractured and carious, may be restorable but pt wants it out due to severe pain, explained to pt that tooth may be saveable with crown/RCT but pt wants ext
9/19/2014	30	fract--	#30 caries and fractured MB/ML cusps
9/19/2014	5	fract--	#5 fractured cusp, #17 caries - refer to UG clinic
9/19/2014	5	fract--	#5 fractured buccal cusp, caries #17
9/19/2014	5	fract--	#5 fractured, buccal cusp slight mobile
9/19/2014	5	fract--	Fractured #5

Date	Tooth	Key-No-Yes	phrase
9/22/2014	30	fract--	#30 carious, fractured distal, symptomatic
9/22/2014	31	broke--	#31 grossly carious with broken crown - non restorable
9/22/2014	31	broke--	Grossly carious #31 with broken cusp
9/23/2014	12	fract--	TX: Intra-oral assessment reveals temporary restoration on the #2 and #12 DOL fracture.
9/23/2014	12	fx--	#12 fx below gingiva, non-restorable
9/23/2014	5	broke--	rampant caries with heavy restoration on all teeth, missing teeth 1,16,17,32, broken #5, all teeth with class one mobility
9/23/2014	5	broke--	broken #5 with rampant caries
9/23/2014	5	broke--	broken #5 with rampant caries-plan to extract under LA with socket preservation for possible future implant placement.
9/24/2014	12	fract--	Acute pain localized to tooth #12 on percussion probably fractured
9/24/2014	19	fract-deliver-root	Tooth #19- fractured into mesial and distal roots, roots were delivered separately.
9/25/2014	12	broke--	12 and 5 broken at gum line
9/25/2014	18	crack--	1: #18 cracked, non-restorable
9/25/2014	18	crack--	#18 cracked tooth
9/25/2014	19	fract--	fractured cusp tipsDB and DL of #19
9/25/2014	20	split--	#20 split in half
9/25/2014	20	split--	#20 split in half with PARL
9/25/2014	29	fract--	fractured #29
9/25/2014	29	fract--	fractured/carious #29
9/25/2014	31	fract--	Fractured cusp #31.

Date	Tooth	Key-No-Yes	phrase
9/25/2014	5	fract--	Gross caries, fractured tooth #5.
9/25/2014	5	fract--	Fractured, carious tooth #5, missing tooth #4.
9/25/2014	5	fract--	Gross caries, fractured #5, non-restorable.
9/26/2014	20	fract--	Carious/fractured non restorable teeth 20, 21, 22, 23, 24, 25, 26, 27, 28 with mandibular tori bilaterally
9/26/2014	20	fract--	Fractured non restorable 20, 21, 22, 23, 24, 25, 26, 27, No other radiographic pathology.
9/26/2014	20	fract--	Fractured non restorable teeth 20, 21, 22, 23, 24, 25, 26, 27, 28.
9/26/2014	21	fract--	Carious/fractured non restorable teeth 20, 21, 22, 23, 24, 25, 26, 27, 28 with mandibular tori bilaterally
9/26/2014	21	fract--	Fractured non restorable 20, 21, 22, 23, 24, 25, 26, 27, No other radiographic pathology.
9/26/2014	21	fract--	Fractured non restorable teeth 20, 21, 22, 23, 24, 25, 26, 27, 28.
9/26/2014	28	fract--	Carious/fractured non restorable teeth 20, 21, 22, 23, 24, 25, 26, 27, 28 with mandibular tori bilaterally
9/26/2014	28	fract--	Fractured non restorable teeth 20, 21, 22, 23, 24, 25, 26, 27, 28.
9/29/2014	12	fract--	O: Bp 123/84 P 67R.Fractured composite veneer restoration on tooth9.
9/29/2014	3	broke--	A: #9 composite resin restoration broke off, cervical 1/3 of restoration is remaining.
9/29/2014	3	fract--	O: Bp 123/84 P 67R.Fractured composite veneer restoration on tooth9.
9/29/2014	3	fract--	#13- Abfraction on L

Date	Tooth	Key-No-Yes	phrase
9/29/2014	4	fract--	O: Bp 123/84 P 67R.Fractured composite veneer restoration on tooth9.
9/30/2014	15	crack-elevat-root	#3,15- periosteum used to release soft tissue, crown on tooth #3 cracked, root tips elevated with irish, all roots were delivered separately.
9/30/2014	28	fract--	(Scanned): Necrotic bone/osteolysis of the right mandibular body extending from the area of tooth #28 to the area of #32 with inferior broder osteolysis, but no evidence of pathologic fracture.
9/30/2014	3	crack-elevat-root	#3,15- periosteum used to release soft tissue, crown on tooth #3 cracked, root tips elevated with irish, all roots were delivered separately.
9/30/2014	30	fract--	#30 - fractured MB
10/1/2014	12	crack--	Cracked tooth #12
10/1/2014	12	crack--	#12: Cracked tooth running M-D.
10/1/2014	12	crack--	#12: cracked tooth.
10/1/2014	15	fract-forcep-	crown fractured w/150 forceps
10/1/2014	19	fract--	Fractured restoration #19
10/1/2014	19	fract-amalgam-	A: Clinical exam shows #19 with fractured amalgam restoration.
10/1/2014	19	fract--	EXT #19-fractured DB, caries
10/2/2014	12	fract--	Patient has fractured #12, wants to ext and wait to restore it later.
10/2/2014	14	fract--	#14 fractured and decay
10/2/2014	14	fract--	fractured #14
10/2/2014	14	fract--	Dental-Fractured lingually #14
10/2/2014	30	fract--	#30 Mesial Fracture

Date	Tooth	Key-No-Yes	phrase
10/2/2014	30	fract--	#30 Mesial FractureRefer to SOD
10/2/2014	30	fract--	dental: #30 fractured MOB #30 filling
10/2/2014	30	fract--	dental: #30 fractured MOB #30 filling -
10/3/2014	13	broke--	#13 broke in 2009 from hard candy.
10/3/2014	13	fract--	#13-fracture
10/3/2014	13	fract--	Fractured #13
10/3/2014	14	fract--	#14 - fractured 3 months ago, pain increased to 8/10 on pain scale1.5 weeks ago.
10/3/2014	14	fract--	#14 - fractured, gross decay
10/3/2014	18	fract--	18- caries and fracture
10/3/2014	19	fract--	Clinical exam: #19 DO composite fractured out.
10/3/2014	19	fract--	S: PPTC: with fractured restoration on #19
10/3/2014	19	fract--	O: Clinical exam: Distal 1/2 of #19 fractured off.
10/3/2014	19	fract--	Hard tissue exam Fractured restoration Distal #19
10/3/2014	19	fract--	Additional Narrative #19 restoration fractured Distal leaving small slice.
10/3/2014	19	fract--	#19 possitive transillumination, possible fracture, will be evaluated under microscope during NSRCT.
10/3/2014	19	fract--root	#19 has some coronal fracture, informed pt that if this extends onto root that tooth would need be extracted.
10/3/2014	3	broke--	Broken #3
10/3/2014	30	fract--	#29, 30, 31, 19, 12, 13 fractured crowns.
10/3/2014	4	fract--	#4 fractured

Date	Tooth	Key-No-Yes	phrase
10/3/2014	4	broke--	dental-broken down #4
10/3/2014	4	fract--	Decay and fractured #4
10/6/2014	30	broke--	#30 - broken restoration, very sensitive to percussion
10/6/2014	31	fract--	dental: #31 - fractured crown
10/6/2014	31	fract--	#31 - grossly decayed/fractured
10/6/2014	31	fract--	#31 - fractured
10/6/2014	31	fract--	#31 fractured 1 week ago.
10/6/2014	4	broke--	Broken #4, 15, 30
10/6/2014	4	fract--	#4 fractured due to decay
10/7/2014	18	fract--	Fractured #18
10/7/2014	18	fract--	Fractured #18
10/7/2014	18	fract--	Fractured #18
10/7/2014	19	fract--	#19 gross decay and fractured lingual
10/7/2014	19	fract--	#19 Gross Decay, Fractured Lingual
10/7/2014	19	fract--	#19-fractured
10/7/2014	19	fract--	#19-Carious lesion and fractured
10/7/2014	21	fract-deliver-root	Root of tooth #21 fractured, it was delivered with root tip pick
10/7/2014	31	fract-amalgam-	#31 fractured, existing amalgam restoration
10/7/2014	31	fract-amalgam-	#31 fracture distal portion of crown, has a large existing amalgam restoration
10/7/2014	31	fract--	Distal portion of 31 is fracture, no PARL
10/7/2014	4	fract--	HPI: Fractured cusp of #4 due to caries

Date	Tooth	Key-No-Yes	phrase
10/8/2014	15	crack--	generalized missing teeth , plaque and calculus , #15 symptomatic to precussion , class 1 mobility on tooth #15 MOD crack through tooth #15
10/8/2014	15	crack--	crack tooth syndrome #15
10/8/2014	15	crack--	dental : cracked tooth syndrome tooth #15
10/8/2014	19	fract--root	#19: Previously treated, chronic apical abscess (tooth not definitively restored after RCT, temporary restoration fractured, contamination of root canal system led to re-infection of tooth)
10/8/2014	19	fract--	O: Extraoral exam: WNL, Intraoral exam: reveals tooth #19 has a fractured temporary and a draining sinus tract.
10/8/2014	2	fract--	#2 Gross Decay/ Buccal fracture
10/8/2014	2	fract--	#2 Gross decay/Buccal Fracture
10/8/2014	5	fract--	#5 had a restoration placed 20 yrs ago which fractured 2 years ago.
10/8/2014	5	fract--	Fractured crown #5
10/8/2014	5	fract--	Fractured #5, PAP
10/9/2014	15	broke--	PPTC with non restorable broken down #15
10/9/2014	15	broke--	#15- grossly decayed, broken down
10/9/2014	18	crack--	Cracked tooth #18
10/9/2014	3	fract--	#3 fractured ML cusp, #30 fractured DB (nonrestorable)
10/9/2014	30	fract--	#30 fractured
10/9/2014	30	fract--	#30 recurrent decay/fracture
10/10/2014	19	fract--	Fractured #19

Date	Tooth	Key-No-Yes	phrase
10/10/2014	19	fract--	#19 - periapical RL, missing restoration, fractured
10/10/2014	5	crack--	Clinical Exam: #5 presents with a crack M& D, can se
10/10/2014	5	crack--	cracked #5, large DO restoration
10/13/2014	13	broke--	#13 has been broken for a couple years.
10/13/2014	13	fract--	#13 fractured crown.
10/13/2014	15	fract--	#15 fractured DOL
10/13/2014	15	fract--	Fractured #15 deemed to be restorable.
10/13/2014	20	broke--	Broken/carious #20
10/13/2014	3	fract--	Deep pits and fissures on {-}, fractured #K, generalized calculus #3 and #5, maxillary orthodontic braces and wires placed today at VCU ortho
10/13/2014	3	fract--	hx of {regional odontodysplasia}, {mixed} dentition, dental caries {-}, deep pits and fissures {-}, fractured #K, calculus #3 and 5
10/13/2014	3	broke--	PA reveals broken down #3, tooth appears intact clinically.
10/13/2014	30	fract--	#30-fractured MOBL.
10/13/2014	30	fract--	#30 fractured MOBL
10/13/2014	31	broke--	Broken down non restorable 31
10/13/2014	4	fract--	#4 fractured B cusp
10/14/2014	19	broke--	Broken down teeth with decay #17,19,30,31
10/14/2014	2	fract--	extensive crown and bridge work, fractured tooth #2.
10/14/2014	2	broke--	Broken down non restorable 2

Date	Tooth	Key-No-Yes	phrase
10/14/2014	2	fract--	Fractured ankle - surgery 2008 and has steel plate - all without complications
10/14/2014	31	fract--	Fractured DL cusp of tooth #31 with associated pain upon percussion
10/14/2014	31	broke--	Expained to pt that tooth #31 could be restored and sensitivity was most likely due to broken DL cusp.
10/14/2014	31	fract--	Fractured tooth #31
10/14/2014	31	fract--	Pt was eating pork and bit down on bone and fractured #31.
10/14/2014	31	fract--	Fracture of tooth #31 lingual.
10/14/2014	31	fract--	Fractured #31 with severe sensitivity
10/15/2014	20	broke--	Pt broke tooth #20 two weeks ago when eating chicken.
10/15/2014	20	fract--	Fractured #20
10/15/2014	20	fract--	Fractured tooth #20
10/16/2014	3	fract--	Grossly carious tooth #3 with fracture of the coronal tooth structure (tooth is non-restorable) with moderate TTP and percussion sensitivity.
10/16/2014	30	vrf--	Recommended further evaluation of the PARL and possible VRF with CBCT #30.
10/16/2014	30	broke--	broken down non restorable #18 and #30
10/16/2014	30	broke--	Pt presents with #18 and #30 broken down and non restorable.
10/16/2014	4	fract--	Fractured crown #14
10/16/2014	4	fract--	S: Patient presents to emergency clinic for fractured tooth #4.
10/16/2014	4	fract--	Fractured #4 non restorable

Date	Tooth	Key-No-Yes	phrase
10/17/2014	12	fract--	EO exam WNL, IO exam WNL: Clinical exam showed that #13 had fractured since last apPt #12 had recurrent decay on mesial, and #11 had open margin on mesial.
10/17/2014	12	fract--	Significant dental findings: #11,12 present with PAP, #13: fractured top gum line
10/17/2014	13	fract-amalgam-	#13: L cusp has incompletely fractured and is mobile, DO portion of amalgam is not present, MO portion of amalgam is loose
10/17/2014	13	fract--	#13: Difficult to determine extent of L fracture.
10/17/2014	13	fract--	#13: Previously initiated treatment, Symptomatic apical periodontitis, Cuspal fracture (L) subgingival
10/17/2014	13	fract--	P: Discussed findings with the patient and the need to remove the L cusp and determine extent of fracture and possibility of restoring #13.
10/17/2014	13	fract--	EO exam WNL, IO exam WNL: Clinical exam showed that #13 had fractured since last apPt #12 had recurrent decay on mesial, and #11 had open margin on mesial.
10/17/2014	13	fract--	Significant dental findings: #11,12 present with PAP, #13: fractured top gum line
10/17/2014	14	fract--	Fractured #14
10/17/2014	15	fract--	#15- gross caries, fractured crown
10/17/2014	30	broke--	broken down non restorable #30
10/17/2014	5	fract--	#5-gross caries, fractured crown
10/17/2014	5	fract--	#15- gross caries, fractured crown
10/20/2014	14	fract--	Fractured #14
10/20/2014	14	broke--	Broken/symptomatic #14

Date	Tooth	Key-No-Yes	phrase
10/20/2014	14	broke--	Broken/carious #14
10/21/2014	15	broke--	Severly broken down #15
10/21/2014	3	crack--	#3- Periapical radiolucency, cracked- Nonrestorable
10/21/2014	3	crack--	#3- Periapical radiolucency, cracked- Nonrestorable - Ext #3
10/21/2014	4	fract--	Fractured tooth #4 with small periapical radiolucency
10/21/2014	4	fract--	Fractured, non-restorable tooth #4.
10/22/2014	18	fract--	#17 and #18 crowns fractured approx 1mo ago while eating.
10/23/2014	13	fract--	#13 fractured
10/23/2014	19	fract--	#19- Gross decay/fracture
10/23/2014	19	fract--	#19- Gross decay/fracture- Extract
10/23/2014	19	fract--	#19- Gross decay/fractured
10/24/2014	12	fract--	B fracture #12 (non-restorable)
10/24/2014	12	fract--	#12 fractured
10/24/2014	12	fract--	Fractured #12
10/24/2014	12	fract--	Fractured #12 one year ago.
10/24/2014	13	fract--	Teeth #'s 9,10,11,13 have fractured at gum line
10/24/2014	14	broke--	#14- Decayed/Broken down-
10/24/2014	14	broke--	#14- Decayed/Broken down- Ext
10/24/2014	14	broke--	#14- Decayed/Broken down
10/24/2014	14	broke--	Patient says that teeth have been broken down for many months, but that #14 has started hurting in the last two days.

Date	Tooth	Key-No-Yes	phrase
10/24/2014	3	fract--	#3, #30 gross decay/fractured
10/24/2014	3	fract--	#30- Fractured/Gross decay
10/24/2014	3	fract--	#3- Fracture/Gross decay
10/24/2014	3	fract--	Fractured #3 and #30
10/24/2014	3	fract--	#30 fractured 2 days ago.
10/24/2014	30	fract--	30 DB cusp fractured
10/24/2014	30	fract--	30 DB cusp fractured-refer to gp
10/24/2014	30	broke--	#30-- pain on percussion tenderness to palpation, broken D marginal ridge
10/24/2014	30	fract--	#3, #30 gross decay/fractured
10/24/2014	30	fract--	#30- Fractured/Gross decay
10/24/2014	30	fract--	Fractured #3 and #30
10/24/2014	30	fract--	#30 fractured 2 days ago.
10/24/2014	30	broke--	#30- Decayed/Broken down-
10/24/2014	30	broke--	#30- Decayed/Broken down- Ext
10/24/2014	30	broke--	#30- Decayed/Broken down with PARL
10/24/2014	30	broke--	#30- Decayed/Broken down
10/27/2014	13	fract--vertical	#13 vertical fracture M-D
10/27/2014	13	fract--vertical	#13 vertical fracture M-D ext
10/27/2014	13	fract--	fractured #13 M-D
10/27/2014	15	broke--	broken down tooth #15 , #16 broken down to the gingiva , #17 is broken down to the gingiva
10/27/2014	3	fract--	Crown fracture on #3 to below CEJ, PARL
10/27/2014	3	fract--	#3 crown fracture

Date	Tooth	Key-No-Yes	phrase
10/27/2014	3	fract--	#3 fracture tooth down to CEJ, PARL
10/27/2014	3	fract--	#3 crown fracture, sensitive to percussion
10/28/2014	18	fract--	Grossly carious and fractured tooth #18.
10/28/2014	18	fract--	Grossly carious/fractured tooth #18
10/28/2014	18	broke--	broken down non restorable #18 and #30
10/28/2014	18	broke--	Pt presents with #18 and #30 broken down and non restorable.
10/28/2014	28	fract-elevat-root	Root tip of tooth #28 fractured off, had to be elevated and delivered w/ hemostat.
10/28/2014	31	fx--	8 mm probing M and MB #31.Radiographs - PA #31 shows M rt fx.
10/28/2014	31	fract-deliver-root	fractured tooth 31 was sectioned between the mesial and distal roots and each root was delivered intact.
10/28/2014	31	fract--	#31 gross decay, fractured.
10/28/2014	31	fract--	#31 fractured tooth, RL around apex
10/28/2014	31	fract--	#31 fractured, caries, PAP- EXT .
10/28/2014	5	fract--	Fractured tooth #5
10/28/2014	5	fract--	#5 fractured and filling fell out.
10/28/2014	5	fract--	#5 existing filling fractured
10/29/2014	12	fract--	O: BP 112/70 P 56 Ill-, All -, Hosp -, Surg + Pacemaker (April '10), Med + Coreg, Lisinopril Small fracture #13MO, Leakage #9 F.
10/29/2014	13	broke--	generalized caries , tooth #13 broken down to the gum line , broken down #1 , 16 , 30 , 31 ,32
10/29/2014	14	fract--	gross caries #14, fracture #29
10/29/2014	14	fract--	dental: caries, gross caries #14, fracture #29

Date	Tooth	Key-No-Yes	phrase
10/29/2014	14	fract--	caries #14, fracture #29.
10/31/2014	15	fract--	#15- Lingual cusp fractured off to 5mm below marginal gingiva
10/31/2014	15	fract--	ext #15- Lingual cusp fractured off to 5mm below marginal gingiva-
10/31/2014	15	fract--	Reports "QUOTE" on impact and tooth fractured (#15).
10/31/2014	3	fract--	Fractured #3
10/31/2014	3	fract--	Fractured #3 with gross decay
10/31/2014	3	broke--	I broke my tooth #3 a year ago, it is sensitive to cold drinks and I could not eat on right side.
11/3/2014	18	fract--	Fracture #18 and #30 with gross decay
11/3/2014	18	fract--	#18 fractured/gross decay
11/3/2014	20	fract--	#20 Gross caries and fracture cusp
11/3/2014	30	fract--	Fracture #18 and #30 with gross decay
11/3/2014	30	fract--	#30 and #31 fracture and gross decay
11/4/2014	13	broke--	"I have a broken tooth (points to #13) t
11/4/2014	18	fract--	#18-fractured DOL, gross decay
11/4/2014	18	fract--	#18-fractured DOL, gross decay.
11/4/2014	18	fract--	Dental findings: #18 fractured
11/4/2014	18	fract-partial-	#18 filled with temporary restoration, partially fractured, Pt sensitive to palpation and percussion.
11/4/2014	18	fract--root	#18 fractured on distal, temporary restoration on distal, pap M root
11/4/2014	18	fract--	#18 fractured on distal, temporary restoration in place on distal

Date	Tooth	Key-No-Yes	phrase
11/5/2014	13	broke--	#13 crown broken, RCT, percussion +, palpation +, mobility Many restorations
11/5/2014	13	broke--	#13 crown broken, RCT, percussion +, palpation +, mobility -
11/5/2014	13	broke--	#13 crown broke on Sunday.
11/5/2014	19	fract--root	Fractured mesial root tip of tooth 19 retained in socket.
11/5/2014	2	fract--	Fractured crown of tooth #20
11/5/2014	20	fract--	Fractured crown of tooth #20
11/5/2014	3	crack--	#3 irreversible pulpitis, cracked tooth
11/5/2014	3	crack-elevat-	#3- irreversible pulpitis, cracked tooth, used periosteal elevator to reflect tissue, elevate, delivered #3 with forceps.
11/5/2014	3	crack--	#3 cracked tooth syndrome- referred by endo bc patient elects ext vs NSRCT
11/5/2014	3	crack--	#3 cracked tooth syndrome- referred by endo ext
11/5/2014	31	fract--	Caries on #18, #30 and fractured #31
11/5/2014	31	fract--root	#31 gross decay, fractured, PAP M root
11/5/2014	31	broke--root	#31 broken and gross decay, PAP M root
11/7/2014	19	fract--	#19 fractured distal, carious, widened pdl, pap
11/7/2014	2	fract--	#2, D fracture
11/7/2014	31	broke--	Dental :broken down #30 , class 1 mobility on tooth #31 large carious lesion radiographically
11/7/2014	31	broke--	generalized missing teeth , broken down #30 , class 1 mobility on tooth #31 large carious lesion radiographically
11/7/2014	5	crack--	#5-cracked tooth

Date	Tooth	Key-No-Yes	phrase
11/7/2014	5	crack--	Cracked #5
11/7/2014	5	crack--	Cracked #5--EXT tooth no restorable
11/7/2014	5	crack-amalgam-	patient has cracked #5, states pain started a month ago while eating food, #5 had an existing amalgam restoration on #5 not present anymore
11/7/2014	5	crack--	#5 cracked M-D
11/10/2014	12	fract--	Fractured teeth 5, 6, 7, 8, 9, 10, ?11, 12, 23, 24, 25, 26.
11/10/2014	14	broke--	generalized caries , broken down #14 to the gum line
11/10/2014	14	broke--	Dental : broken down #14 to the gum line
11/10/2014	14	broke--	#14 broken down previously endo treated
11/10/2014	31	fract--root	Non restorable tooth 31 with root fracture.
11/10/2014	31	fx--root	Pt referred to us from commonwealth endo due to root fx on tooth 31.
11/10/2014	31	broke-elevat-	Ext #31 with forceps, crown broke off, remainder of tooth fragments removed in pieces using elevators.
11/10/2014	5	fract--	Fractured teeth 5, 6, 7, 8, 9, 10, ?11, 12, 23, 24, 25, 26.
11/11/2014	15	crack--	Cracked tooth #15
11/11/2014	18	fract--vertical	location of lesion (extending up into furcation area, with very little at apex) that prognosis for #18 is poor, and that there is probably vertical root fracture.
11/12/2014	18	fract--	#18: Fractured DB cusp.
11/12/2014	18	fract--	Dental: coronal fracture of 18

Date	Tooth	Key-No-Yes	phrase
11/12/2014	19	broke--	#19 broke 1 year ago, started hurting 3-4 days ago.
11/12/2014	2	fract--	Dental: #2 fracture/gross decay.
11/12/2014	2	fract--	#2 fracture
11/12/2014	2	fract--	#2 fracture/gross decay
11/12/2014	2	fract--	#2 fractured, sensiive to hot/cold/biting.
11/12/2014	2	broke--	Broke Right arm 20 years ago.
11/12/2014	28	fract--	fractured #28, #12
11/12/2014	28	fract--	Gross caries/crown fracture #28
11/12/2014	3	fract--	#3 fracture
11/12/2014	3	broke--	#3 broke a month ago, started swelling yesterday, chronic pain, 5/10, denies fever, no pain to hot/cold, hurts when patient bites down.
11/12/2014	30	fract--	Dental: Enamel fracture 30
11/12/2014	30	fract--	Buccal/Distal buccal cusp on 30 fractured off
11/13/2014	18	fract--	Fractured crown 18
11/13/2014	19	fract--	19: fractured distal
11/13/2014	19	fract--	#19 fractured distal
11/13/2014	4	broke--	Additonal Narrative Pt was eating cereal with walnuts and tooth 4 broke.
11/13/2014	4	broke--	Dental History #4 broke from use in May.
11/13/2014	4	broke--	#4 and #5 broke last year.
11/13/2014	5	broke--	#4 and #5 broke last year.
11/13/2014	5	crack--	#5 Cracked
11/13/2014	5	crack--	#5 cracked

Date	Tooth	Key-No-Yes	phrase
11/13/2014	5	fract--	#5 fracture
11/14/2014	4	broke--	Hard Tissue: Caries: 2 M, F, #6 DL, #7 DL, ML, #8 DL, ML, #9 DL-watch ML- defective margin, #14 D,#19L, #22 BL margin, #23 DL #24 DF, #26 DL, #29 Around margin on F, #30 F amalgam defect in margin with
11/14/2014	4	fract--	Caries detected #4 B/loose crown, #5 L, #6 ML and DL, #7 ML and DL, #8 ML and DL, #11 D, 19 L, #20 Mesial, #29 B, #30 pt had fractured restoration back in september and upon removing the decay informe
11/14/2014	4	broke--	Pt reports history of: breast cancer (surgery 2007, biopsy-2012, patient currently in remission) with chemotherapy treatment for 5 yrs; Pancreatitis (Dec 2011); Meningitis (December 2011) total of 4
11/14/2014	4	fract--root	Tooth #14 may be fractured at the root.
11/14/2014	4	fract-forcep-	The PFM crown of tooth #4 was removed with crown remover forceps, the clinical crown had fractured and remained in the crown along with the post-core.
11/14/2014	4	fract--	caries/fractured #4
11/14/2014	4	broke--	on xrays 4 broken and multiple areas of caries.
11/17/2014	19	fract--	#19: Fracture MD, caries reaching the canals.
11/17/2014	30	fract--	A:Generalized high caries risk, xerostomia, #7- non-restorable, #30-non restorable, supperation at #23 location with fractured crown and overgrown tissue.
11/17/2014	31	fract--	#31- gross decay, fractured MD

Date	Tooth	Key-No-Yes	phrase
11/18/2014	13	fract-elevat-	Upon attempted luxation/elevation of #13 with elevators and forceps, tooth crown fractured off to below gumli
11/18/2014	29	fract--	DE: Dr : discussed large filling on #29 that may be at increased risk for fracture, but pt states that the filling has been in place since approx "1950." No other significant findings
11/18/2014	29	fract--	Dr : discussed large filling on #29 that may be at increased risk for fracture, but pt states that the filling has been in place since approx "QUOTE" No other significant findings
11/18/2014	30	broke--vertical	tooth #30 is broken down and has a radiolucency at the apex, has vertical defect on distal
11/19/2014	15	fract--	Gross occlusal caries (fractured buccal cusps) #15.
11/19/2014	31	fract--	#31: crown fracture, gross caries
11/19/2014	31	broke--	buccal half of tooth #31 is broken off, sensitive to percussion
11/19/2014	31	broke--	tooth #31 is broken and painful
11/20/2014	18	fract--	#18:Gross caries, fractured crown.
11/20/2014	4	fract--	Bigelow presents to Grad Perio for txplanning for #4 that is fractured at the gingival margin.
11/20/2014	4	broke--	Pt had broken off #4 t
11/21/2014	15	fract--root	Hard tissue exam (Findings) watch #18 restoration defect (B), abfraction on #21 and #20 and needs to be monitored, #30 has root caries, #15 (M) needs to be restored
11/21/2014	15	broke--	#30 has broken off since the last appointment and he has been having sensitivity to cold and percussion on #15 (treated at last appointment)

Date	Tooth	Key-No-Yes	phrase
11/21/2014	29	fract--	#29: Caries reaching pulp, crown is fractured.
11/21/2014	30	fract--	Carious/Fractured #30
11/21/2014	4	fract--	tooth #4 fractured.
11/24/2014	18	fract--	#18- MB and ML cusps are fractured.
11/24/2014	18	fract--root	#18- fractured Mesial cusps, root tips extend into IAN canal.
11/24/2014	18	fract--root	Dental- #18 fractured and non restorable and root tips extend into IAN canal.
11/24/2014	18	fract--	Fractured #18
11/24/2014	18	fract-amalgam-	#18 has a fractured old amalgam filling, painfull to percussion
11/24/2014	18	fract--	#18- DL cusp fracture.
11/24/2014	18	fract--	Dental- #18- DL cusp fracture.
11/24/2014	18	fract--	#18- caries, fracture, unrestorable
11/24/2014	2	fract--	#2- fractured ccrown, gross caries non-restorable
11/24/2014	2	fract--	#2 - Fractured crown, gross caries, non-restorable
11/24/2014	29	fract--	Fractured #29
11/24/2014	3	fract--	Fractured #3 with gross caries
11/24/2014	3	fract--	fractured non restorable #3 referred from facuilty practice
11/24/2014	3	fract--	fractured #3
11/24/2014	30	fract--root	Patient informed #30 has infection, possible root fracture, will evaluate in GP.
11/24/2014	30	fract--root	#30 root fracture
11/25/2014	14	fract--root	retained root tip 14, 17, fractured #15

Date	Tooth	Key-No-Yes	phrase
11/25/2014	15	fract--root	retained root tip 14, 17, fractured #15
11/25/2014	30	fract--root	Fractured teeth with root tips #3,17,25,30
11/25/2014	31	fract--	Fractured caries #31- EXT
11/25/2014	31	fract--	Fractured caries #31
11/25/2014	4	fract--	I/O: Tooth 4 fractured to gumline and non restorable.
11/26/2014	4	crack--	#4 Cracked Mesial- Distal, Confirmed with Illumination
11/26/2014	4	crack--	#4 Cracked Mesial- Distal, Confirmed with Illumination
11/26/2014	4	crack--	Cracked my tooth points to #4
11/26/2014	4	crack--	#4 Cracked Mesial- Distal, Confirmed with Illumination -EXT
12/1/2014	15	fract--	#15 fractured and grossly decayed, Retained #T.
12/1/2014	15	fract--	#15 unrestorable and fractured
12/1/2014	19	fract-amalgam-	#19 has an MO amalgam with fracture below gingiva.
12/1/2014	30	broke--	Broken down #30 , 32
12/1/2014	30	broke--	generalized caries , tooth #13 broken down to the gum line , broken down #1 , 16 , 30 , 31 ,32
12/1/2014	31	broke--	generalized caries , tooth #13 broken down to the gum line , broken down #1 , 16 , 30 , 31 ,32
12/2/2014	12	fract--	#12 fractured with PARL
12/2/2014	12	fract--	#12 fractured crown.
12/2/2014	13	broke--	Significant dental findings: #13: presents with broken crown to gingival margin, presence of abscess.

Date	Tooth	Key-No-Yes	phrase
12/2/2014	18	fract--vertical	#18 vertical root fracture
12/2/2014	30	fract-porcelain-	Diagnosis #30: Existing crown has open margin in B with caries, fractured 2/3rds porcelain, and keeps falling off.
12/3/2014	15	fract--	fractured restoration #15 DO
12/3/2014	15	fract--	Per review of student's notes, patient is to have EXT of grossly carious/fractured non-restorable teeth #s 4, 5, 15, 16 in preparation of BMT.
12/3/2014	15	fract--root	Fractured/decayed retained roots #s 2, 5, 15, 16.
12/3/2014	15	fract-partial-	#15 large carious lesion and crown partially fractured, buccal mucosa tender upon palpation and percussion.
12/3/2014	2	broke--	Broken down #2
12/3/2014	29	fract-amalgam-	A: #29 presents with fractured amalgam restoration.
12/3/2014	30	fract--	Dental:#30, #31 coronal fracture- non-restorable.
12/3/2014	30	fract--	#30, #31 coronal fracture- non-restorable
12/3/2014	31	fract--	Dental:#30, #31 coronal fracture- non-restorable.
12/3/2014	31	fract--	#30, #31 coronal fracture- non-restorable
12/3/2014	4	fract--	Per review of student's notes, patient is to have EXT of grossly carious/fractured non-restorable teeth #s 4, 5, 15, 16 in preparation of BMT.
12/3/2014	5	fract--	fractured restoration #15 DO
12/3/2014	5	fract--	Per review of student's notes, patient is to have EXT of grossly carious/fractured non-restorable teeth #s 4, 5, 15, 16 in preparation of BMT.
12/4/2014	15	fract--	#15- Mesial marginal ridge fracture with large MO decay

Date	Tooth	Key-No-Yes	phrase
12/4/2014	15	fract--	Dental- #15- Mesial marginal ridge fracture
12/4/2014	18	fract--	#14 - open margin on class V resin.#18 - O Amal + fracture lines on M + D on watch.
12/4/2014	18	fract--	Fracture on M marginal ridge of #18, needs MO composite.
12/4/2014	18	crack-amalgam-	#18 O amalgam, MMR and DMR cracks, B and L cracks - no significant probings
12/4/2014	18	crack--	Hx:NSRCT initiated on 10/24/14 due to cracked tooth #18
12/4/2014	18	crack-amalgam-	#18 O amalgam with worn O Cavit access resto, 7mm pocket along crack line on the D
12/4/2014	18	fract--	#18 & 22 gross decay/fracture
12/4/2014	18	fract--	#18 & 22 gross decay and fractured crowns
12/4/2014	4	fract-elevat-root	#4 was elevated, crown fractured off and extract of roots with ~3mm buccal and lingual flap reflectin and forcep with no complications.
12/4/2014	4	fract--	TX: #4 crown had fractured to gumline since last apPt Pt was not in pain.
12/4/2014	4	broke--	Broken, non-restorable #4, 6
12/5/2014	2	fract--	Grossly carious/fractured tooth 2.
12/5/2014	31	broke--	#31- Broken to the gum line
12/5/2014	31	fract--	#31- fractured restoration.
12/5/2014	31	fract--	#31- fractured restoration, restorable
12/8/2014	14	fract--root	Fractured tooth #14, root tips present with gingiva growth over top of the root tips
12/9/2014	12	fract--	#12: Fractured composite with recurrent decay.
12/9/2014	14	fract--	#14- fractured on the Mesial.

Date	Tooth	Key-No-Yes	phrase
12/9/2014	19	fract--	#19-fractured RCT, #30-NRC
12/9/2014	19	fract--	#19, fractured RCT with periapical abscess
12/9/2014	19	fract--	fractured crown #19 with previous RCT, painful to palpation on lingual
12/9/2014	2	fract--	Dental History fractured tooth #2
12/9/2014	29	fract--	Non restorable #29 and #31 due to caries and periodontal involvement,crown fracture both teeth.
12/9/2014	29	fract--	#29 - fractured crown and gross decay
12/9/2014	30	fract--	#19-fractured RCT, #30-NRC
12/9/2014	31	fract--	Non restorable #29 and #31 due to caries and periodontal involvement,crown fracture both teeth.
12/9/2014	31	fract--	#31 - fracture and gross decay
12/9/2014	4	fract--	#4- Fractured crown
12/9/2014	4	fract--	extract #4- fractured crown
12/9/2014	4	fract--	#4 fractured crown
12/10/2014	28	fract--	#28 Fractured crown/caries
12/10/2014	28	fract--	1- Fractured crown on #28.
12/10/2014	28	fract--	periapical radiolucency #19 RCT, fractured #28
12/10/2014	28	fract--	fractured #28
12/10/2014	28	fract--	Tooth #28 has a fractured crown.
12/10/2014	30	fract-porcelain-	Diagnosis Fractured porcelain on PFM #30.
12/10/2014	30	fract--root	No opposing tooth for #31 and fractured root on previously RCT #30.

Date	Tooth	Key-No-Yes	phrase
12/10/2014	31	broke--	Hard Tissue: Caries present on #15: Buccal, #31:B and defect on mesial of restoration-smooth/polish, #20: porcelain of 3 unit bridge broke off 2 months ago, Once in a while patient is Sensitive to cold
12/10/2014	31	fract--root	No opposing tooth for #31 and fractured root on previously RCT #30.
12/11/2014	13	fract--	#13 fractured crown
12/11/2014	18	fract--	#18 gross caries and fractured
12/11/2014	19	fract--	DE: Dr: PA of #30 19/20 and first molars and 4 HBWs , #2 MODL (lingual cusp is fractured on the mesial and lingual), #12 DOB (evaluate with bws first), watch #18 distal (around margin), watch
12/11/2014	19	fract--	DE: Dr: PA of #30 19/20 and first molars and 4 Hbws should be taken at the next restorative visit, #2 MODL (lingual cusp is fractured on the mesial and lingual), #12 DOB (evaluate with bws fir
12/11/2014	19	fract--	RTC: Return to clinic for PA of #30 19/20 and first molars and 4 Hbws should be taken at the next restorative visit, #2 MODL (lingual cusp is fractured on the mesial and lingual), #12 DOB (evaluate wi
12/11/2014	2	fract--	Fractured #2, 8
12/11/2014	2	fract--	#2 Fracture distal with calculus bridge from #2-3
12/11/2014	29	fract--	#29 fracture crown, nonrestorable
12/11/2014	29	fract--	#29 fracture crown
12/11/2014	29	fract--	#29 fracture crown close to crestal bone
12/11/2014	29	fract--	#29 fracture crown- nonrestorable

Date	Tooth	Key-No-Yes	phrase
12/11/2014	30	fract--	#30 fractured crwon - > EXT
12/11/2014	30	broke--	#30 broken off crown.
12/11/2014	5	fract--	Diagnosis Fractured #5
12/12/2014	12	fract--	#12 sensitive to perussion and palpation, crown fracture causing the most pain, non-restoreable
12/12/2014	12	fract--	#12 sensitive to perussion and palpation, crown fracture causing the most pain
12/12/2014	18	fract--	S:PPTC as an emergency patient with a fractured DL and ML cusps of #18
12/12/2014	18	fract--	A: Fractured DL and ML cusps of #18, patient elects to have crown placed
12/12/2014	19	fract--	#19 fractured cusp, non-restorable
12/12/2014	20	fract--	#20- fractured crown
12/12/2014	20	fx--	#20- fx crown
12/12/2014	20	fract--	#20- fractured crown, not carious
12/12/2014	21	fract--	S: PPTC with fractured buccal cusp of tooth #21.
12/12/2014	21	fract--	Dental: fractured #21
12/12/2014	29	broke--	A: #29 badly decayed and broken
12/12/2014	3	fract--	#3- non-restorable with fractured crown
12/12/2014	5	fract--root	#5- non-restorable, fractured crown, retained root
12/15/2014	19	fract--	#5, 6, 19 fractured with gross decay
12/15/2014	19	fract--	Dental: #19-Gross decay, parulis, PARL, #6 and 7 fractured crown
12/15/2014	19	fract--root	#19-fractured crown, PARL on M & D roots
12/15/2014	19	fract--	#19-Gross decay, #20-O composite, #5 and #6 fractured crowns

Date	Tooth	Key-No-Yes	phrase
12/15/2014	2	fract--	#2-ML fracture
12/15/2014	3	fract--	#3-fractured
12/15/2014	3	fract--	#3- fractured crown
12/15/2014	3	broke--	Pt states he broke #3 eating a popcorn kernel and is in constant pain.
12/15/2014	31	fract--vertical	Severe vertical bone loss #31M, no evidence of fracture noted in coronal portion of #31.
12/15/2014	31	fract--	gross fracture #31
12/15/2014	5	fract--	#5, 6, 19 fractured with gross decay
12/15/2014	5	fract--	#19-Gross decay, #20-O composite, #5 and #6 fractured crowns
12/16/2014	13	fract--	#13 Coronal fractured off
12/16/2014	13	fract--	Clinical crown of #13 fractured off
12/16/2014	13	fract--	#13 Crown fractured off, #14 Necrotic
12/16/2014	14	fract--root	#14 MB root fracture
12/16/2014	14	fract--	#13 Crown fractured off, #14 Necrotic
12/16/2014	30	broke--	Mom says that #30 has been bothering patient for a while now, and it is waking her up at night and has broken.
12/17/2014	12	fract--root	#12-fractured crown, root tips remain, sensitive to percussion
12/17/2014	12	fract--root	#12-fractured crown, root tips remain
12/17/2014	13	fract--	#13- fractured crown
12/17/2014	14	fract--	Grossly carious/fractured #14.
12/17/2014	14	fract--	#14 - crown fracture
12/17/2014	14	crack--	Cracked #14

Date	Tooth	Key-No-Yes	phrase
12/17/2014	19	fract--	Fractured #19
12/17/2014	19	fract--	#19- Caries/fractured crown
12/17/2014	19	fract--	#19- Caries/fractured crown and PARL
12/17/2014	29	fract--	Occlusally a slight piece of temporary on #29 had fractured, replaced with Integrity.
12/17/2014	29	fract--	Tooth #29 with fractured crown with buccal gingival recession and secondary caries.
12/17/2014	29	fract--	Pt states #29 fractured a few days prior and reports constant pain worsening at night.
12/17/2014	31	fract--	#31- pain on percussion and fractured D marginal ridge
12/17/2014	4	fract--	A: PSR: 0 0 0 / 0 2 0, caries #4 D, fracture #30 M
12/18/2014	14	fract--	#14 fractured
12/18/2014	14	broke--	45 y/o male reports to clinic with broken #14, pt fractured buccal cusps while eating hard candy one day ago.
12/18/2014	14	fract-amalgam-	14 - fractured buccal cusps with existing amalgam restoration
12/18/2014	19	fract--	#19 Gross decay and fracture
12/18/2014	19	fract--	#19 decay and fracture
12/18/2014	19	fract--	Fractured/Decay #19
12/18/2014	3	fract--root	Fractured teeth with root tips #3,17,25,30
12/18/2014	3	fract--	Fractured non restorable tooth 3
12/18/2014	3	fract--	Fractured non restorable tooth 3.
12/19/2014	30	fract--	#30 is fractured.
12/19/2014	30	fract--	#30: fractured crown

Date	Tooth	Key-No-Yes	phrase
12/19/2014	30	fract--	Pt reports #30 crown fracture 6 months ago and constant 10/10 pain.
1/5/2015	2	fract--root	Upon extraction of #2 by dental student, buccal plate fractured off and was noted to be fused to buccal roots of #2 resulting in large buccal cortical defect at site #2.
1/5/2015	3	fract--	carious/fractured #3
1/6/2015	12	fract--	#12 coronal fractured
1/6/2015	12	fract--	#12 coronal fracture
1/6/2015	12	fract--	#12 coronal fracture at level of gingiva margin-irreversible pulpitis, unrestorable
1/6/2015	15	broke--	HPI: pt points to #15 and states she thinks it broke.
1/6/2015	19	fract-elevat-root	Elevated #19 and removed with cowhorns, distal root fracture, removed with east/west and socket irrigated.
1/6/2015	20	broke--	Patient points to tooth #20 and says that tooth is broken and it hurts.
1/6/2015	20	fract--	#20 fractured restoration with recurrent caries
1/6/2015	30	fract--	Fractured restoration #30
1/6/2015	30	fract--	#30 fractured restoration with recurrent caries, several other teeth with carious lesions
1/6/2015	30	fract--	#30 fractured restoration,pt denies endo
1/7/2015	20	fract--	#20 fractured
1/7/2015	20	fract--	#20 fractured, PAP
1/7/2015	20	fract--	#20 fractured, PAP, non-restorable

Date	Tooth	Key-No-Yes	phrase
1/7/2015	31	broke--	She states that she has a lot of broken down teeth but the one that is bothering her the most is tooth #31.
1/8/2015	15	fract--	Gross decay/fractured#15
1/8/2015	15	fract--	Gross decay, fracture #15
1/8/2015	15	fract--	pt reports #15 fracture a month ago, gradually widening of remaining fragments causing pain to tongue, no associated tooth pain
1/8/2015	18	fract--	#18 D fracture
1/8/2015	18	fract--	#18 D fracture, caries into the pulp- restorable with RCT
1/8/2015	18	fract--	#18 fractured to the gum line, recurrent caries #20, 28, 29, 30,
1/8/2015	18	fract--	Dental: #18 fractured to the gum line, recurrent caries #20, 28, 29, 30
1/8/2015	20	fract--	crown fracture and gross decay #20, refer to general practice to assess other restorative needs
1/8/2015	30	fract--	Fractured #30 with symptomatic apicle periodontitis
1/8/2015	30	fract--	#30 fractured crown, gross decay
1/8/2015	30	fract--	#30 fractured crown with associated PAP
1/8/2015	31	fract--	#31 coronal fracture- unrestorable
1/8/2015	31	fract--	#31- coronal fracture, gross caries- unrestorable
1/9/2015	18	fract--	#18: fractured, endo treated
1/9/2015	18	fract--	#18: fractured crown.
1/9/2015	18	fract--	Grossly carious/fractured #s 18 and 19.
1/9/2015	18	fract--	Grossly carious/fractured #s 18 and 19

Date	Tooth	Key-No-Yes	phrase
1/9/2015	19	fract--	Grossly carious/fractured #s 18 and 19.
1/9/2015	19	fract--	Grossly carious/fractured #s 18 and 19
1/9/2015	30	fract--	#30 large restoration, fractured crown
1/9/2015	30	fract--	Fractured #30
1/9/2015	30	fract--	#30 had RCT about a year ago, fractured last week while pt was eating, has been hurting since.
1/12/2015	12	broke--	Broken down and carious teeth #11 and #12, both tender to palpation.
1/12/2015	13	fract--	Fractured non restorable tooth 13.
1/12/2015	19	fract--	#19 distal fracture, sensitive to percussion
1/12/2015	19	fract--	#19 Distal fracture and carious RL
1/12/2015	2	fract--	#2 Distal Crown fracture
1/12/2015	2	fract--	#2 Distal Crown Fracture and carious
1/12/2015	2	fract--	#2 Distal fracture and carious
1/12/2015	30	split--	split tooth #30
1/12/2015	4	fract--	Pt reports fracture of #4 two weeks ago, with gradual increasing pain since, and swelling which began two days ago.
1/12/2015	4	fract--root	dental: Fractured crown #4, remaining root tip
1/12/2015	4	fract--root	Fractured crown #4, remaining root tip
1/12/2015	4	fract--	Fractured #4
1/13/2015	19	broke--	broken #19
1/13/2015	29	fract--	#29 distal fracture.
1/14/2015	2	broke--root	A: Blunt roots anteriorly, caries, plaques, deep pocket between #3 and 2, broken restoration on #31D

Date	Tooth	Key-No-Yes	phrase
1/14/2015	2	fract--	Perio consult was done by Dr for #3 and #2 bone defect and #31 distal fracture.
1/14/2015	2	fract--	HIV positive, Neuralgia, caries #2M ,#3MD, and fracture restoration on #31D
1/14/2015	2	fract--	caries on #2M and #3MD, Fracture restoration on #31D, bone defect between #2 and #3
1/15/2015	3	broke--	Throbbing, constant pain in the UR two weeks ago for a week (tooth #3 that was broken).
1/15/2015	3	fract--	#3- PARL, Gross caries, fractured crown
1/15/2015	3	fract--	#3- Gross caries, fractured crown
1/15/2015	5	crack--	Cracked tooth #15
1/16/2015	12	fract--	#12 M-D fracture
1/16/2015	13	fract--	Fractured #13.
1/16/2015	3	fract--	Fracture #18 and #30 with gross decay
1/16/2015	31	fract-partial-	Also, #31 core buildup partially fractured 2 months ago.
1/16/2015	31	fract-amalgam-	#31 is most urgent since amalgam has fractured.
1/16/2015	31	fract-amalgam-	#31 fractured amalgam smoothed and Pt was informed that this tooth needs a crown asap.
1/16/2015	31	fract--root	also explained that "I should get a discount on the root canal tooth (#3) because my lower teeth (#31 and #30) the gold ones were placed too high and they made my tooth above it fracture and made me
1/16/2015	31	fract--root	#31 Coronal RO consistent w/ crown, Radicular RO consistent w/ root filling from previous NSRCT (obturation appx 1-2mm from radiographic apex, adequate taper and density in D canal, RO in apical part

Date	Tooth	Key-No-Yes	phrase
1/16/2015	31	fract--	A: Dx #31: Previously Treated, Acute Apical Abscess, Fractured tooth in Furcation
1/16/2015	31	crack--	#31 cracked tooth, nonrestorable
1/16/2015	31	crack--	#31 cracked tooth
1/16/2015	31	fract--	#30 and #31 fracture and gross decay
1/20/2015	13	fract--vertical	#13 non restorable, vertical root fracture.
1/20/2015	14	fract--root	#14 shows root fracture and #20 is palpation and percussion sensitive.
1/20/2015	2	fract--root	#2 - crown fractured and decayed/root tips remaining
1/20/2015	2	broke--	#2 broke a couple years but over the last couple days it spontaneously hurts me and there is swelling around the gum
1/20/2015	20	fract--root	#14 shows root fracture and #20 is palpation and percussion sensitive.
1/20/2015	28	fract--	#29 fractured crown, #28 gross caries
1/20/2015	29	fract--	#29 fractured crown, #28 gross caries
1/20/2015	30	fract--	#30 gross decay/ fractured restoration
1/20/2015	30	broke--	broke #30 10 months ago while eating pop corn
1/20/2015	30	fract--	#30 restoration fracture and gross distal decay
1/21/2015	13	fract--	Caries and fractured DO #13, 18, 19
1/21/2015	19	fract--	Caries and fractured DO #13, 18, 19
1/21/2015	29	fract--	told her that she does not need to go through with the proposed txt plan (extraction and site pres #29 due to fracture/infection).
1/21/2015	31	fract--	#31-MO large IRM filling with D crown fracture
1/21/2015	31	fract--	distal fracture, nonrestorable #31

Date	Tooth	Key-No-Yes	phrase
1/21/2015	31	fract--	Fractured, nonrestorable #31
1/22/2015	18	fract--	Fractured #18
1/22/2015	3	broke--	my upper tooth (3) is broken
1/22/2015	4	fract--vertical	#4 vertical root fracture
1/22/2015	4	fract--	Fractured #4 occlusal, multiple carious lesions
1/23/2015	2	broke--root	Root tips and broken down teeth #2-32
1/23/2015	2	broke--root	Root tips/broken down/severely decayed teeth #2-32
1/26/2015	18	fract--root	Updated panorex- teeth #18 and 17 have large carious lesions- tooth #17 is non-restorable and is likely to fracture at crown and root tips approximate IAN canal.
1/26/2015	19	fract-amalgam-	A: Decay #19ML and fractured amalgam with pins ML and DL #19ML.
1/26/2015	2	broke--	generalized missing teeth , generalized periodontitis , broken down #2 ,
1/27/2015	29	fract--root	Roots w/ fractured off crowns- #13,29
1/27/2015	5	broke--	Patient presented 3 broken down upper teeth,#4,5, and 6.
1/27/2015	5	broke-denture-	Presently,he is wearing very broken down lower interim acrylic prosthesis which is carrying #23,24,25,and 26 teeth with a heavy denture adhesive.Patient was presented with the treatment plan which in
1/28/2015	30	fract-elevat-root	D root tip of #30 fractured off and elevated out seperately.
1/30/2015	14	fract--	#14-MO crown fracture to gumline, grossly decayed
1/30/2015	15	fract--	#15 DO fracture

Date	Tooth	Key-No-Yes	phrase
1/30/2015	15	fract--	#15 DO coronal fracture
1/30/2015	15	fract--	fractured clinical crown #15
1/30/2015	15	fract--	Fractured #15
1/30/2015	15	fract--	Fractured #15 - possibly restorable, pt elects extraction
1/30/2015	15	crack--	Symptomatic cracked #15
1/30/2015	18	fract--	#18- Fractured MO restoration with caries
1/30/2015	4	fract--	#14-MO crown fracture to gumline, grossly decayed
1/30/2015	4	fract--	#4 - fractured clinical crown, caries to pulp
2/2/2015	18	fract--	fractured #18
2/2/2015	19	broke--root	generalized missing teeth , #9 broken down , root tip , #19 carious with pain on precussion
2/2/2015	2	fract--root	Fractured/decayed retained roots #s 2, 5, 15, 16.
2/2/2015	5	fract--root	Fractured/decayed retained roots #s 2, 5, 15, 16.
2/3/2015	12	fract-forcep-	Extraction of #12 with forceps, Crown fracture.
2/3/2015	12	broke--	Patient points to broken #12
2/3/2015	13	fract--	#13 fractured
2/3/2015	14	fract--	fractured cusp #14.
2/3/2015	14	fract-amalgam-	There is an existing #14-MO amalgam restoration that has fractured and is loose.
2/3/2015	14	fract-amalgam-	There is an existing #14-MO amalgam restoration that has fractured and is loose (originally done 02/2014).
2/3/2015	30	fract--	Additional Narrative #30 Crown margin is adapted to tooth but cervical abfraction has occurred post-crown placement

Date	Tooth	Key-No-Yes	phrase
2/3/2015	5	fract--	Pain #5, decay, fractured
2/3/2015	5	fract--	#5 fractured non restorable
2/3/2015	5	fract--	fractured #5
2/3/2015	5	fract--	#5 fractured, non restorable
2/4/2015	3	fract--	#3 good decay, DL cusp fractured
2/4/2015	3	broke--	#3 gross decay, DL cusp broken below gum line
2/5/2015	13	fract--	Fractured #9, 10, 13
2/5/2015	13	fract--root	#13 2x1mm PAP with fractured cusp , slight D curvature of root
2/5/2015	13	fract--	Fractured #9, 10, 13 - rest
2/5/2015	20	fract--	#20 clinical crown fracture with pulpal exposure
2/5/2015	20	fract--	Clinical crown fracture on #20 and #21
2/5/2015	21	fract--	#21 clinical crown fracture
2/5/2015	21	fract--	Clinical crown fracture on #20 and #21
2/5/2015	30	fract--	#30 - fractured- pt elects EXT
2/5/2015	30	fract--	#30 - fractured crown
2/5/2015	30	fract--	#30 - previous RCT, fractured filling
2/6/2015	13	fract--	#13 fracture, patient desires EXT
2/6/2015	15	fract--	#30 mesial monitor for incipient decay, #4 Mesial decay radiographically, #15 fractured has has RCT
2/6/2015	15	fract--	Dr : decay on D of #4 radiographically, #15 fractured, #19 symptomatic to cold hot and biting pressure.

Date	Tooth	Key-No-Yes	phrase
2/6/2015	15	fract--	#30 mesial monitor for incipient decay, #4 Mesial decay radiographically, #15 fractured has has RCT
2/6/2015	15	fract--	Tooth #15 has fractured off and has existing decay.
2/6/2015	15	fract--	Additional Narrative Pt stated tooth #15 fractured off 20+ years ago.
2/6/2015	15	fract--vertical	He said that 15 might have a vertical root fracture because of the fact that it has 10mm pocket on the ML aspect as compared to the 5mm all around and despite the tooth being asymptomatic prompt extrac
2/6/2015	15	fract--	Hard tissue exam abfractions 6B, 14B, 15B, 28B
2/6/2015	15	fract--	Procedures added to treatment plans glass ionomer to repair abfractions in 6B, 14B, 15B, 28B
2/6/2015	4	fract--	#4 nonrestorable due to fracture and recurrent decay
2/6/2015	4	fract--	4M fracture down to crestal bone levels with recurrent decay
2/6/2015	4	fract--	Fractured M of 4, recurrent decay
2/6/2015	4	broke--	Tooth #4 broke after christmas
2/9/2015	12	fract--	#12 GC, Fractured restoration
2/9/2015	13	fract--	#13- Gross decay/fractured cusp - Ext
2/9/2015	13	fract--	fractured/unrestorable #13
2/9/2015	13	fract--	#13- Gross decay/fractured cusp
2/9/2015	18	fract--	Cariou and fractured #18
2/9/2015	18	fract--	Fractured and carious #18

Date	Tooth	Key-No-Yes	phrase
2/9/2015	18	broke--	"Pain on LL and I have broken tooth #18
2/9/2015	18	fract--	Fractured #18 on Distal - (restable w/multiple step pt elects to ext)
2/9/2015	18	fract--	Fractured tooth #18 pain on chewing.
2/9/2015	18	fract--	#18 Fractured tooth (pt elect ext)
2/9/2015	3	fract--	Teeth #'s 9,10,11,13 have fractured at gum line
2/9/2015	4	broke--	Broken #4,, Carious #14, #19
2/9/2015	4	broke--	Broken and carious #4 with associated PAP
2/9/2015	4	broke--	Broken #14, Broken #19
2/9/2015	4	broke--	Broken #4 with PAP
2/9/2015	4	broke--	Carious and broken #4 with associated PAP radiolucency in approximation of right maxillary sinus.
2/9/2015	4	fract--	Fractured #14, carious #19, possible PAP #30
2/10/2015	12	fract--	Fractured #12 and fractured restoration #5
2/10/2015	12	fract--	fractured #12
2/10/2015	12	fract--	Fractured teeth #12
2/10/2015	12	fract--	#12 fracture
2/10/2015	12	fract-forcep-	Crown of #12 fractured off with forcep.
2/10/2015	30	fract--	#30 Fractured/ gross caries.
2/10/2015	30	broke--	This tooth broke and hurts (#30)
2/10/2015	30	fract--	#30- fractured ,Loss of lamina dura
2/10/2015	30	fract--	Fractured #30 with pain
2/10/2015	30	broke--	Toot#30 Broke 4 days ago with pain
2/10/2015	5	fract--	#5 fractured crown to gum line

Date	Tooth	Key-No-Yes	phrase
2/10/2015	5	fract--	#5 fractured crown (hopeless prognosis) explained to pt saving the tooth with multiple steps (crown lengthening, RCT, crown) vs.
2/10/2015	5	fract--	#5 fractured to gum line (hopeless prognosis/non-restorable)
2/10/2015	5	fract--	Fractured tooth #5 (Hopeless)
2/10/2015	5	fract--	#5 fractured months ago.
2/11/2015	18	fract--	Fractured #18
2/11/2015	19	fract--	Fractured #19,20 with PAP
2/11/2015	20	fract--	Fractured #19,20 with PAP
2/12/2015	15	fract--	Fractured left heel 15 years ago- surgically corrected and three screws placed.
2/12/2015	19	fract--	fractured #19
2/12/2015	19	fract--root	#19 fractured and PARL M root
2/12/2015	2	broke--	2 weeks ago tooth broke off.
2/12/2015	31	fract--	fractured restoration #31
2/12/2015	31	fract--	Fractured restoration #31
2/12/2015	31	fract--	#31 crown fractured
2/12/2015	31	fract--	Fractured restoration #31, #31 previously endo treated
2/13/2015	14	fract--	Pt presents with fractured tooth #14
2/13/2015	18	fract--	#18 - fractured cusp
2/13/2015	19	fract--	#19 previously endo treated tooth with fractured DM,DL cusp, no pain with palpation,slight pain with percussion
2/13/2015	19	fract--	#19 fractured DM,DL cusp, no pain with palpation,slight pain with percussion

Date	Tooth	Key-No-Yes	phrase
2/13/2015	19	fract--	fractured #19
2/13/2015	30	fract--root	Patient also had fractured tooth #30 with only root tips presents.
2/13/2015	4	fract--	#4, #5, #6, #7, #8 fractured
2/13/2015	5	fract--	#4, #5, #6, #7, #8 fractured
2/16/2015	13	fract--	#13 fractured
2/16/2015	13	fract--	#13 fractured - EXT
2/16/2015	14	split-elevat-root	surgical extraction of 14, ftmpf reflected, split tooth with bur into 3 sections, removed the roots with elevator and forceps, irrigated with ns.
2/16/2015	14	fract--	Fractured #14 w/ pain
2/16/2015	14	fract--	Fractured #14
2/16/2015	14	fract--	Fractured #14 w/ pain and percussion sensitivity
2/16/2015	14	fract--	Fractured #14 w/ pain - EXT #14
2/16/2015	19	fract--	#19 Gross caries/fractured M cusp to gum line.
2/16/2015	19	fract--	Fractured and decayed #19
2/16/2015	2	broke--	#2 broken restoration with gross decay
2/16/2015	2	broke--	#2 BROKEN RESTORATION WITH GROSS DECAY DISTALLY
2/16/2015	2	broke--	#2 Broken restoration with gross decay distally
2/16/2015	20	fract--	#20 fractured
2/16/2015	28	fract--	surgical extraction of 28 and 29, crowns carious and fractured,
2/16/2015	29	fract--	surgical extraction of 28 and 29, crowns carious and fractured,
2/16/2015	3	fract--	#1 - Caries, #3 gross decay and fracture

Date	Tooth	Key-No-Yes	phrase
2/16/2015	30	fract--root	Fractured #30 (retained root tip) - Ext
2/16/2015	30	fract--root	Fractured #30 (retained root tip)
2/16/2015	4	fract--vertical	95percent BL on #14 palatal root seems to be from vertical root fracture.
2/16/2015	5	fract--vertical	95percent BL on #14 palatal root seems to be from vertical root fracture.
2/18/2015	14	broke--	Gross carious lesion #14, crown broken down
2/18/2015	18	fract--	crown of #18 fractured off, caries #17
2/18/2015	18	fract--	#18 fractured while eating last week.
2/18/2015	18	fract--	#18- gross caries, fracture, non restorable
2/18/2015	28	fract--	Fractured non restorable teeth 4, 10, 28, 29.
2/18/2015	3	broke--	#3 has broken restoration
2/19/2015	29	fract--	#29 - Distal marginal ridge fracture, caries
2/19/2015	5	fract--	#5 fractured w/ slight vestibular swelling.
2/19/2015	5	fract--	#5 Fractured
2/19/2015	5	fract--root	#5 fractured root tips present
2/20/2015	14	broke--	dental: broken teeth #3,14,30
2/20/2015	14	broke--	broken teeth #3,14, 30
2/20/2015	14	broke--root	broken teeth/rampant decay/root tip: #3, 14, 30
2/20/2015	18	fract--	#18- gross decay & fracture, PARL
2/20/2015	18	fract--	#18- Fracture and gross decay
2/20/2015	3	crack-amalgam-	#3 has large DO amalgam, with crack in MMR.
2/20/2015	3	crack--	PPTC after referral back from grad endo- patient was referred for RCT on tooth #3 but upon accessing, crack was found extending on pulpal

Date	Tooth	Key-No-Yes	phrase
			floor through tooth and tooth was deemed non-restorable
2/20/2015	3	crack--	Referred from AEGD for Cracked tooth #3
2/20/2015	3	broke--	dental: broken teeth #3,14,30
2/20/2015	3	broke--	broken teeth #3,14, 30
2/20/2015	3	broke--root	broken teeth/rampant decay/root tip: #3, 14, 30
2/20/2015	3	fract--	fractured #3 to the pulp
2/20/2015	3	broke--	broken #3, all else WNL
2/20/2015	30	broke--	dental: broken teeth #3,14,30
2/20/2015	30	broke--	broken teeth #3,14, 30
2/20/2015	30	broke--root	broken teeth/rampant decay/root tip: #3, 14, 30
2/20/2015	4	broke--	Dental History Broken crown #4, Missing #19 20+ years
2/20/2015	4	broke--	Diagnosis/Indication for Procedure #2/4 EXT, broken br
2/20/2015	4	fract--	fractured crown #4
2/23/2015	14	fract-amalgam-	A: a fractured Amalgam restoration BL on tooth #14 , and grade 2 mobility on tooth #13 .
2/23/2015	14	broke--	broken down non restorable #14
2/23/2015	14	fract-amalgam-	#14 large fractured Amalgam restoration with 2 pins
2/23/2015	14	fract--	large MODL amalgam restoration on tooth #14 fractured BL .
2/23/2015	14	fract-amalgam-	fractured amalgam restoration on tooth #14
2/23/2015	15	fract--	#3 and 15 crown fractured.

Date	Tooth	Key-No-Yes	phrase
2/23/2015	15	fract--	Fractured and decayed #15
2/23/2015	15	fract--	#3 and 15 fractured.
2/23/2015	18	fract--	Fractured #9,10,10,18
2/23/2015	18	fract--	Fractured #18
2/23/2015	19	fract--	A: #19 fracture
2/23/2015	19	fract--	A: generalized recurrent decay, #19 B cusps have fracture since previous visit, large blue bruise on pt's face located along R
2/23/2015	19	fract--	19 - tooth has fractured after having large composite restoration after endo treatment, caries undermining restoration, non-restorable
2/23/2015	19	fract--	49 y/o female presents with fractured #19.
2/23/2015	31	fract--	Decay #32,31,20 (with fractured crown), 17,
2/24/2015	14	fract--	Fractured #7, #10, #11, #14, #31
2/24/2015	18	fract--	gross decay and crown fracture #18
2/24/2015	18	fract--	gross decay with fracture crown #18
2/24/2015	18	fract--	gross decay and fracture crown #18
2/24/2015	19	fract--	#4 with fractured lingual cusp and M overhang, #5 mobile with RL at apex from previous radiographs, #11 D RL, DL decay, #12 F composite marginal defect, #18 purulent drainage from sulcus #19 D margina
2/24/2015	19	fract--	Hard tissue exam Clinical caries noted on #11D #31DL, Abfraction noted on #12B, #13B, #19B, #21B (See Tx developed 4/2012).
2/24/2015	19	fract-amalgam-root	Hard tissue exam (Findings) #11D decay, abfraction #12, #13 exposing root canal and needs restoration, #19 decay, #20 occlusal amalgam

Date	Tooth	Key-No-Yes	phrase
2/24/2015	3	fract--	36 yo female with history of multiple(4-5) myocardial infarctions (age 16-28, last episode 8 yrs ago, unknown cause) , C5-C6 incomplete spinal cord injury s/p spinal fusion 1995.
2/24/2015	30	fract--	Fractured #30
2/24/2015	30	fract--	#30 Fractured
2/24/2015	30	fract--	- Fractured #30
2/24/2015	30	fract--	#30 Fractured DL Cusp-non restorable
2/24/2015	30	fract--	Fractured DL cusp #30
2/25/2015	12	broke--	Pt CC at today's visit is that tooth #12 has broken off when eating popcorn.
2/25/2015	12	fract--	#12 - Class 1 fracture.
2/25/2015	12	fract--	Class 1 fracture #9 and #12
2/25/2015	12	fract-amalgam-	A: Fractured amalgam restoration on #12 (DO), buccal cusp also fractured.
2/25/2015	14	fx--	55 yo F referred from GP for ext and socket pres tooth #14, due to fx and not restorable.
2/25/2015	14	fx--	Fx #14
2/25/2015	15	crack--	Evidence of bruxism with certical crack #21 on buccal and mesial marginal ridge and pt has worn through gold restoration on #15 lingual cusp (does not need repair at this time- watch).
2/25/2015	18	crack--	Patient called to inform me that his lower back tooth cracked off (#18).
2/25/2015	18	fract--	Gross decay and fracture restoration #18
2/25/2015	18	fract--	#18 gross decay, fractured crown
2/25/2015	19	fract--root	Retained root tip 19 and fractured 20

Date	Tooth	Key-No-Yes	phrase
2/25/2015	19	broke--	Broken crown #19
2/25/2015	19	broke--	Broken crown #19- unrestorable
2/25/2015	19	fract--root	PPTC with retained root tips #19 and fractured #20.
2/25/2015	19	broke--	Broken tooth #19
2/25/2015	20	fract--root	Retained root tip 19 and fractured 20
2/25/2015	20	fract--root	PPTC with retained root tips #19 and fractured #20.
3/2/2015	2	fract-forcep-root	Delivered crown of #2 with forceps, Fracture of MB/DB/P roots
3/2/2015	20	fract--	MI 2008 - Pt indicates physician told him he has <30% ejection fraction
3/2/2015	3	fract--root	fractured crown #3, root tips remain
3/2/2015	3	fract--	dental, caries control, fractured crown #3
3/2/2015	3	fract--	fractured crown #3
3/2/2015	30	fract--	Signed consent for retx #30, with the understanding there is a good chance tooth is fractured and will require extraction.
3/2/2015	30	fract--	asymptomatic fractured #30, non restorable
3/2/2015	30	fract--	Fractured #30, deemed non-restorable
3/2/2015	30	fract--	Fractured #30, non-restorable
3/3/2015	14	fract--	Myocardial infraction May 2014.
3/3/2015	19	broke--	broken distal cusp #19/fractured restoration and caries
3/3/2015	19	fract--	Gross decay #19, fractured cusp
3/3/2015	19	fract--	dental: #19 gross caries, fractured distal cusp

Date	Tooth	Key-No-Yes	phrase
3/3/2015	2	fract--	#2 mesial fracture with PAP
3/3/2015	2	fract--	#12 crown fracture
3/3/2015	2	fract--	fractured tooth #2 with PAP- restorable w/ endo/crown, pt elects to ext
3/3/2015	2	fract--	#12 crown fracture at gumline
3/3/2015	2	broke--	Broken #2 with PAP - EXT
3/3/2015	2	fract--	Fractured #12 - future EXT
3/3/2015	2	fract--	#2 fractured at the mesial - extremely sensitive to palpation and percussion
3/3/2015	2	fract--	#12 crown fractured at the gumline
3/3/2015	4	fract-elevat-root	Ext #4 with forceps, root fractures, reflected small buccal FTMPF, elevated the root with root pick, irrigated with NS, closed with 3-0 chromic x2.
3/4/2015	3	fract--	#30-gross decay, fracture
3/6/2015	30	fract--	Fractured restorations #5, 12, 13, 19, 21, 30, 31
3/6/2015	30	fract--	Cariou #30- fractured distal cusp
3/6/2015	31	fract--	Fractured restorations #5, 12, 13, 19, 21, 30, 31
3/6/2015	31	fract--	#31 necrotic, crown fractured and missing.
3/6/2015	4	fract--	fractured #14
3/6/2015	4	fract--	fracture #14
3/6/2015	4	fract--	#14 fracture - EXT at a later date
3/6/2015	5	fract--	Fractured restorations #5, 12, 13, 19, 21, 30, 31
3/9/2015	31	fract--	#31 unrestorable, carious exposure, fractured existing clinical crown
3/9/2015	5	fract--	Abfraction #5 and #6

Date	Tooth	Key-No-Yes	phrase
3/9/2015	5	fract--	P:4% Septoc with 1:100.000 epi local infiltration half carpule #4 crown prep'd, M and D fracture line, prep'd margin below them, made temp with acrylic A3.5 + A3, adjusted occlusion and polished, ceme
3/9/2015	5	fract--	A: Fractured #5 lingual cusp mobile segment.
3/9/2015	5	fract--	S: PPTC for fractured #5 L cusp.
3/9/2015	5	fract--	A: Fractured #5 lingual cusp, no sensitivity to cold/hot.
3/9/2015	5	fract-amalgam-root	Oral exam reveals a fractured amalgam restoration on #5 (DO) that extends far subgingival onto the root surface.
3/9/2015	5	fract--	Dental History Multiple restorations on #5, reasons for restoration replacement have been related to secondary caries and/or fracture of the existing restoration likely due to heavy occlusion.
3/9/2015	5	fract-amalgam-	Pt presented today (2/27/15) with fractured DO amalgam that was placed in October 2014.
3/9/2015	5	fract-amalgam-	Additional Narrative PPTC for replacement of fractured DO amalgam of #5.
3/10/2015	20	fract--	#20 most painful on percussion (++) , Large abfraction.
3/10/2015	20	fract--	Abfraction on #8,9, 19,20, 21
3/10/2015	29	fract--	fractured and decayed #16, 29
3/10/2015	29	fract--	#29 fractured and decayed
3/10/2015	29	fract--	#29 fractured and decayed - EXT
3/10/2015	29	fract--	#29 fractured and decayed-non-restorable

Date	Tooth	Key-No-Yes	phrase
3/10/2015	30	broke--	Took PA #30: Gross decay,PAP noted, both distolingual and distobuccal cusps broken to the gumline.
3/11/2015	20	fract--	fracture crown of #20
3/11/2015	29	fract--	Coronally decayed and fractured #29
3/11/2015	3	fract--	fractured #3
3/11/2015	3	fract--	fractured #3
3/11/2015	30	fract--	Mesiodistal crown fracture #30
3/11/2015	30	fract--	Fractured crown / nonrestorable tooth #30
3/11/2015	30	fract--	Fractured crown / nonrestorable tooth #30 - EXT
3/11/2015	30	fract--	Fractured #30 Nonrestorable
3/11/2015	31	fract--	Fractured 31
3/11/2015	31	fract--	Fractured 31.
3/12/2015	30	fract--	#30 DO coronal fracture- restorable
3/12/2015	30	fract--	#30- fractured crown and caries
3/12/2015	30	fract--	fractured non-restorable #30
3/12/2015	30	fract--	fractured non-restorable #30 - EXT
3/12/2015	30	fract--	#30 fractured non-restorable
3/12/2015	30	fract--	fractured non-restorable #30 - sensitive to percussion
3/12/2015	30	fract--	#30 - clinical crown fracture - nonrestorable
3/12/2015	31	broke--root	A: Blunt roots anteriorly,caries, plaques, deep pocket between #3 and 2, broken restoration on #31D
3/12/2015	31	fract--	Dr advised pt to have a perio consult for tooth#31due to the extensive fracture.

Date	Tooth	Key-No-Yes	phrase
3/12/2015	31	fract--	Perio consult was done by Dr for #3 and #2 bone defect and #31 distal fracture.
3/12/2015	31	fract--	Distal fracture on #31, No cold response on #10, EPT:25 Positive Cold response on #31, EPT: 18
3/12/2015	31	fract--	HIV positive, Neuralgia, caries #2M ,#3MD, and fracture restoration on #31D
3/12/2015	31	fract--	caries on #2M and #3MD, Fracture restoration on #31D, bone defect between #2 and #3
3/12/2015	31	broke--	calculus and broken restoration on #31D
3/12/2015	31	fract--	#31 fracture crown with gross decay
3/13/2015	14	fx--	During removal #14 GP, MB roort tip fx see GP Med HX
3/13/2015	20	broke--	DE: Dr recommends appt asap to correct broken restorations at #11 & #20.
3/13/2015	20	fract--	Abfraction present #20
3/13/2015	20	fract--	Per Dr: Abfraction #20 buccal, please evaluate for restoration with composite to prevent further loss of tooth structure.
3/13/2015	20	fract--	Referred from hygiene clinic to restore large abfraction on #20.
3/13/2015	20	fract--	A: Large abfraction on #20.
3/13/2015	31	fract--	fractured lingual surface of #31
3/13/2015	4	fx--	During removal #14 GP, MB roort tip fx see GP Med HX
3/13/2015	5	fract--	Fractured tooth #5
3/13/2015	5	fract--	multiple fractured teeth #5
3/16/2015	19	fract--	complete crown fractured tooth #19.

Date	Tooth	Key-No-Yes	phrase
3/16/2015	19	fract--	Fractured tooth 19
3/16/2015	19	fract--	76 yom who presents to the emergency clinic for evaluation of fractured tooth 19.
3/16/2015	20	fract--	Decay #32,31,20 (with fractured crown), 17,
3/16/2015	29	fract--	Fractured tooth 29.
3/16/2015	29	fract--	-Fractured tooth 29
3/16/2015	31	crack--	3 weeks ago, endo told me there is a crack on #31.
3/16/2015	4	broke--	#4 broken to gumline w/ caries
3/17/2015	12	crack--	Dental History patient reports that she cracked the teeth in December of 2012.
3/17/2015	12	fract--	Dental History tooth fractured in December 2012, edges have been sharp, no pain associated
3/17/2015	12	fract--	Incidentally, the Pt also noted that she had a lingual cusp fracture of #12.
3/17/2015	19	broke--root	Patient broke 60 min appt for removal of retained root tip #19 and to finish scaling.
3/17/2015	19	fract--root	Exam reveals fractured root fragment #19 with inflammed soft tissue surrounding it
3/17/2015	2	fx--	#2 gross caries with fx MB and ML cusps
3/17/2015	31	fract--	Symptomatic #31 with large carious fract
3/17/2015	31	fract--	Large tooth fracture on MO of #31
3/17/2015	31	fract--	Large carious fracture MOBL of #31, Mn tori
3/17/2015	4	fract--	A: Patient has fractured #4, non-restorable
3/17/2015	4	fract--	A: #4 crown fracture, non-restorable.
3/18/2015	12	fract--	Caries/fractured #12, fractured #29.

Date	Tooth	Key-No-Yes	phrase
3/18/2015	30	fract--	Gross caries/ fracture #30
3/18/2015	30	fract--	#30 previous pulpectomy, fractured tooth
3/18/2015	4	crack--	Dental: cracked #4
3/18/2015	4	fract--	fractured tooth #4
3/18/2015	4	crack--	cracked #4, painful upon percussion
3/19/2015	19	fract--	Pelvic Fracture circa 1947
3/19/2015	19	fract--	Clavicle fracture 1958
3/19/2015	19	fract--	Gross fracture of #7, 19, 20
3/19/2015	19	fract--	Gross coronal fracture of #7, 19, 20
3/19/2015	19	fract--	Gross coronal fracture of #7, 19, 20 - non-restorable
3/19/2015	19	broke--	broken teeth #7, 19, 20
3/19/2015	20	fract--	Gross fracture of #7, 19, 20
3/19/2015	20	fract--	Gross coronal fracture of #7, 19, 20
3/19/2015	20	fract--	Gross coronal fracture of #7, 19, 20 - non-restorable
3/19/2015	20	broke--	broken teeth #7, 19, 20
3/19/2015	29	fract--	Gross coronal fracture #6, 29
3/19/2015	29	fract--	Gross coronal fractures #6, 29 - non-restorable
3/19/2015	4	fract--root	#4- Previous obturation (adequate density, length and taper), RL seen on mesial aspect of root (10xXXX), possible fracture line in coronal third of root
3/19/2015	4	crack--	Reviewed recommended tx #4 extraction due to possible crack and poor prognosis.

Date	Tooth	Key-No-Yes	phrase
3/19/2015	4	fract--root	PA shows a root fracture on #4, tooth is non-restorable.
3/20/2015	18	fract--	#18- soft tissues released, attempted to luxated tooth but crown fractured, bu
3/20/2015	2	fract--root	Root fracture of tooth 2
3/20/2015	2	fract--	Fractured tooth 2.
3/20/2015	2	crack--	Pt was seen 2 months ago for eval for ext of non restorable cracked #2.
3/20/2015	2	broke--root	dental: Broken #2, retained root tips
3/20/2015	2	broke--	Broken #2
3/20/2015	20	fx--	#20 fx crown with pulp exposure
3/20/2015	20	fx--	#20 fx with pulp exposure
3/20/2015	5	fract--	presented with fractured #5, unrestorable,previously endo trated
3/20/2015	5	fract-elevat-root	#5 elevatedwithraight elevators and delivered with 151 forceps without any root fractures.
3/20/2015	5	fract--	#5 Unrestorable and fractured crown
3/23/2015	28	broke--	Patient broke her lower right tooth #28 5 days ago.
3/23/2015	30	fract--	#30- Fractured D restoration, caries, Painful to percussion
3/23/2015	30	fract--	#30- Fractured D restoration, Painful to percussion
3/24/2015	2	fx--	#2 fx ML & DL cusps, PAP
3/24/2015	2	fract--	#2 ML and DL cusps fractures, part of occlusalcomposite filling came off
3/24/2015	2	fract--	#2 PAP, distal cusp fracture

Date	Tooth	Key-No-Yes	phrase
3/24/2015	2	fract--	#2 PAP, fracture ML & DL cusps, can be restored with endo, followed crown lengthening but pt opt to have tooth ext
3/25/2015	18	fract-deliver-root	Crown of #18 fractured, delivered w/ distal root.
3/25/2015	19	fract-forcep-	Crown of #19 fractured, delivered w/ forcep.
3/25/2015	31	fx--	#31 PAP, fx crown
3/25/2015	5	fract-forcep-	#5 crown fractured, delivered w/ forcep.
3/26/2015	18	crack--	Tooth 18 cracked.
3/26/2015	19	fract--	#19- Fractured restoration, gross caries
3/26/2015	19	fract--	#19- Fractured restoration, gross caries, non restorable
3/26/2015	19	fract--	#19- Fractured restoration, gross caries.
3/26/2015	19	fract--	fractured #19 to gingiva
3/26/2015	4	fract--vertical	P- determined #4 likely has vertical root fracture- PA had no significant findings to think otherwise and retreatment not best idea anyways due to post.
3/27/2015	13	broke--	UL tooth (#13) broke 3 years ago, pain started 3 months ago.
3/27/2015	13	fract--	fractured and gross caries #13
3/27/2015	18	broke--root	Broken down teeth, root tips (3, 16, 32, 17,18)
3/27/2015	30	fx--	#30 gross caries, fx crown
3/27/2015	30	fx--	#30 gross caries, fx crown- nonrestorable
3/27/2015	31	fract--root	Teeth fractured at gumline with retained root tips #2, 12, 15, 30, 31
3/30/2015	15	fract--	Gross caries and fractures as noted above 2,3,4, 13, 14, 15

Date	Tooth	Key-No-Yes	phrase
3/30/2015	19	fract--	Fractured #19 while eating chicken bone on 12/30/2014.
3/30/2015	19	fract--	Fractured tooth with decay #19.
3/30/2015	19	fract--	#19 - Fractured tooth w/ decay.
3/30/2015	19	fract--	Fractured tooth #19
3/30/2015	31	fract--	#29, 30, 31, 19, 12, 13 fractured crowns.
3/30/2015	31	broke--	caries, broken tooth #31
3/31/2015	14	fx--vertical	-Vertical root fx tooth 14
3/31/2015	20	fract--	fractured, carious tooth 20
3/31/2015	20	fract--	fractured tooth 20
3/31/2015	20	fract--	patient is anemic, patient has a fractured tooth 20 , generalized plaque
3/31/2015	20	fract--	Fractured tooth 20
4/1/2015	3	broke--	Crown broken on #3, 4
4/1/2015	3	broke--	Pt reports the crown on #3, 4 broke off.
4/1/2015	4	broke--	Crown broken on #3, 4
4/1/2015	4	broke--	Pt reports the crown on #3, 4 broke off.
4/2/2015	12	fract--	Fractured #12, non-functional #15
4/2/2015	12	fract--	Widened PDL on #12 and crown fractured, previously RCT
4/2/2015	12	fract--	Hyperkeratotic tissue on left lateral border of tongue, pt reports biting on fractured #12
4/2/2015	12	fract--	#12: fractured to gumline.
4/2/2015	12	fract--	Fractured tooth 12 (endo treated)
4/2/2015	12	fract--	tooth 12 endo treated fractured 9/2014 -

Date	Tooth	Key-No-Yes	phrase
4/2/2015	15	fract--	Fractured #12, non-functional #15
4/2/2015	19	fract--	Dental: Fractured #19, non-restorable.
4/2/2015	19	fract--	Fractured #19.
4/2/2015	19	fract--	Gingival overgrowth over fractured #19
4/2/2015	4	fract--	#4, 14, 15, 31,32 crowns fractured
4/2/2015	4	broke--	#4: gross caries/broken down.
4/3/2015	13	fract--	#13 fractured.
4/3/2015	13	fract--	#13 fractured
4/3/2015	18	fract--root	fractured crown #18 Root tip #20
4/3/2015	2	broke-amalgam-	#2 broken amalgam restoration - non restorable
4/3/2015	20	fract--	fractured crown on previously treated RCT #20
4/3/2015	20	fract--root	fractured crown #18 Root tip #20
4/3/2015	20	fract--	fractured crown on previously treated RCT#20
4/3/2015	20	fract--	Fractured #20.
4/3/2015	20	fract--	Fractured #20, 31
4/3/2015	20	fract--	#20, 31 severely fractured.
4/3/2015	29	fract--	#29 has large fracture on distal- pulp exposed
4/3/2015	31	fract--	Fractured #20, 31
4/3/2015	31	fract--	#20, 31 severely fractured.
4/6/2015	12	fract--	Fractured teeth 3, 4, 5, 6, 11, 12, 13, 14, 15, 18 and 31.
4/6/2015	13	fract--	Fractured teeth 3, 4, 5, 6, 11, 12, 13, 14, 15, 18 and 31.
4/6/2015	14	fract--	Fractured teeth 3, 4, 5, 6, 11, 12, 13, 14, 15, 18 and 31.

Date	Tooth	Key-No-Yes	phrase
4/6/2015	15	fract--	Fractured teeth 3, 4, 5, 6, 11, 12, 13, 14, 15, 18 and 31.
4/6/2015	18	fract--	Fractured teeth 3, 4, 5, 6, 11, 12, 13, 14, 15, 18 and 31.
4/6/2015	2	fract--	Fractured teeth 3, 4, 5, 6, 11, 12, 13, 14, 15, 18 and 31.
4/6/2015	29	fract--	#29: fractured with periapical pathosis present ass'd with periodontitis
4/6/2015	31	fract--	Fractured teeth 3, 4, 5, 6, 11, 12, 13, 14, 15, 18 and 31.
4/6/2015	31	fract--	Gross caries/fractured tooth #31
4/6/2015	5	fract--	Fractured teeth 3, 4, 5, 6, 11, 12, 13, 14, 15, 18 and 31.
4/7/2015	13	fract--vertical	flap with possible GTR, flap debridement or extract and graft with subsequent implat placement #12,13 if tooth appears to be vertically fractured.
4/7/2015	13	split--root	consistent with temporary crown (acrylic), Canal anatomy appears to demonstrate Type IV Weine with split in middle 1/3rd of root ~13.0 mm apical to occlusal surface of preparation, Lamina dura intact
4/7/2015	13	fract--	Lesion distal to tooth #13 could be perio/endo, perio, or a fracture.
4/7/2015	13	fract-elevat-root	If root is fracture, Dr discussed sectioning root of #13 under bridge, elevating incrementally and extracting #13 root leaving bridge intact.
4/7/2015	18	fract--	fractured restoration #18 with caries
4/7/2015	18	fract--	#18 fractured and gross decay, non-restorable
4/7/2015	2	fract--	Fracture 2002

Date	Tooth	Key-No-Yes	phrase
4/7/2015	2	fract--	Tooth 1, 2, 16 fractured/gross decay into pulp
4/7/2015	20	fract--	Fracture 2002
4/7/2015	20	broke--	broken arm over 20 years ago
4/7/2015	30	fract--	tooth #30 nonrestorable due to gross caries extending to pulp, distal of crown fractured
4/7/2015	30	fract--	#30 gross decay- distal of crown fractured
4/7/2015	31	fract--	Large fracture #31,
4/7/2015	31	fract--	gross decay / fracture tooth 31
4/7/2015	31	fract--	Dental: Large fracture #31, caries #16, 17, 32
4/8/2015	13	fract--	#13: fractured to gumline
4/8/2015	13	broke--	#13: broken to gumline
4/8/2015	13	broke--	#13: broken to gumline- hurts to eat for 4 days.
4/8/2015	18	fract--	Fractured #4,18
4/8/2015	18	fract--	Fractured #4,15,18,20,29
4/8/2015	18	fract--	Symptomatic fractured #4,18
4/8/2015	19	fract--root	#19 fractured- two root tips remaining
4/8/2015	19	fract--root	#19 fractured- root tips remaining
4/8/2015	19	fract--	dental - fractured, carious tooth 19 and 20
4/8/2015	19	fract--	fractured 19 and 20
4/8/2015	19	fract--	fractured tooth 19 and 20, gross caries
4/8/2015	19	fract--	gross caries, fractured 19 and 20
4/8/2015	20	fract--	dental - fractured, carious tooth 19 and 20
4/8/2015	20	fract--	fractured 19 and 20
4/8/2015	20	fract--	fractured tooth 19 and 20, gross caries

Date	Tooth	Key-No-Yes	phrase
4/8/2015	20	fract--	gross caries, fractured 19 and 20
4/8/2015	3	fract--	#3 gross caries, fracture ML & DL cusps
4/8/2015	30	fract--	#30 - Coronal fracture.
4/8/2015	30	fract--	#30 - Coronal fracture, previous endodontic treatment.
4/8/2015	30	fract--	1) #30 - Coronal fracture with decay
4/8/2015	30	fract--	#30 - Caries, Fracture, non-restorable
4/8/2015	4	fract--	Fractured #4,18
4/8/2015	4	fract--	Fractured #4,15,18,20,29
4/8/2015	4	fract--	Symptomatic fractured #4,18
4/9/2015	14	fract--	fractured crown #14, ext
4/9/2015	14	fract--	crown fracture of #14
4/9/2015	18	fract--	fractured crown #17, gross caries #18 D
4/9/2015	18	fract--	#18 - Severely Decayed and Fractured
4/9/2015	18	fract--	Tooth 18 is fractured, gross decay
4/9/2015	18	fract--	fractured, gross decay tooth 18
4/9/2015	18	fract--	Dental - fractured / decayed tooth 18
4/9/2015	19	fract--	P: took PA of #19, endo tested #19-21, Dr for endo consult, determined need for RCT due to irreversible pulpitis from bacteria leaking into pulp chamber from fracture, discussed the possibility
4/9/2015	19	crack--	Advised NSRCT #19 with favorable prognosis (to trace the crack, prognosis may be guarded depending on the apical extent of the crack)..
4/10/2015	14	fract-elevat-	Upon elevation of tooth #14, crown fractured off.

Date	Tooth	Key-No-Yes	phrase
4/10/2015	19	fract--	Fractured #19
4/10/2015	19	fract--	Fractured tooth #19 is rubbing against tongue.
4/10/2015	20	fract--	distal of tooth #20 is fractured
4/10/2015	20	fract--	Pain associated with #20- distal fractured
4/10/2015	30	fract--	Fractured crown #30, #18.
4/13/2015	19	fract--	Dental- #19 fractured unrestorable
4/13/2015	19	fract--	#19 fractured.
4/13/2015	19	fract--	#19 fractured below gingiva.
4/13/2015	19	fract--	#19Crown fractured this past Monday, No pain or swelling associated
4/13/2015	19	fract--	Fractured #19 crown, unrestorable
4/13/2015	19	fract--	#19 fractured.
4/13/2015	19	fract--	Fractured restoration #19
4/13/2015	19	fract-amalgam-	#19 fractured amalgam restoration
4/13/2015	19	fract--	#19 fractured crown
4/13/2015	19	fract--	#19 fractured and grossly carious
4/13/2015	2	fract--	Fractured crown: #12
4/13/2015	2	fract--	Fractured crown (at gingiva): #12
4/13/2015	2	fract--	Fractured crown (at gingiva): #12 - Ext
4/13/2015	2	fract--	Fractured #2 with decay
4/13/2015	2	fract--	Fractured #2 with decay- restorable w/ endo/crown, pt elects to ext
4/13/2015	2	fract--	Fractured #2
4/13/2015	3	fract--	Fractured #13

Date	Tooth	Key-No-Yes	phrase
4/13/2015	30	fract--root	RO noted at the apex of #30 and possible fracture of D root.
4/13/2015	30	fract--	Hard tissue exam #30 fractured nonrestorable
4/14/2015	18	fract--	Tooth #18 is nonrestorable with apparent fracture through the furcation
4/14/2015	2	fract--	Pt said crown fractured off 2 weeks ago while he was cleaning his teeth.
4/14/2015	2	fract--	Teeth have fractured 2 weeks ago while patient was eating.
4/14/2015	2	fx--	#2 fx crown
4/14/2015	2	fract--	#2: fractured crown.
4/14/2015	20	fract--	A: Abfraction on #21 present, no caries on B of #20.
4/14/2015	29	fx--	Crown fxed, pain PAP, hopeless #26, 29
4/14/2015	30	fract--	EXT #30 - Discussed with patient options - retreat and/or possible exploration for fracture by endodontist.
4/14/2015	5	fract-porcelain-	Porcelain fracture noted on #5pt states this happened about 6 weeks ago.
4/15/2015	15	fract--	fractured, non restorable #15
4/15/2015	18	fract--	Gross Caries/Fractured #18
4/16/2015	20	broke--	Leg injury, 2005, 2006 broken femur, no complications
4/16/2015	20	broke--	broken femur 2006
4/16/2015	3	fract--	Clinically, #3's ML cusp has fractured off below the gingival margin.
4/17/2015	14	fract--	#4, 14, 15, 31,32 crowns fractured

Date	Tooth	Key-No-Yes	phrase
4/17/2015	14	fract--	#14, #15, #31, #32 fractured crowns
4/17/2015	14	fract--	Tooth #14 fractured lingual, gross decay
4/17/2015	15	fract--	#4, 14, 15, 31,32 crowns fractured
4/17/2015	15	fract--	#14, #15, #31, #32 fractured crowns
4/17/2015	2	fract--	#2 fractured at the gingival margin (with provisional and post)- non-restorable as there is not enough sound tooth structure
4/17/2015	2	fract--	Dental History Lingual of 12 fractured off, no known pulpal exposure due to restoration being placed at outside GP
4/17/2015	3	fract--	A: PA of #3 taken, PAP noticed and J shape lesion notice on distal #3, clinical exam noticed #3 has fracture line from mesail to distal.
4/17/2015	3	crack--	cracked tooth #3 with decay
4/17/2015	30	fract--	#30 fractured and carious, nonrestorable
4/17/2015	30	fract--	#30 carious and fractured
4/17/2015	31	fract--	#4, 14, 15, 31,32 crowns fractured
4/17/2015	31	fract--	#14, #15, #31, #32 fractured crowns
4/17/2015	4	fract--	PPD <4-5 mm bet 4-5 papilla edematous w/ localized BOP , fracture 5DL
4/20/2015	18	fract--	#18: Mesial cusp fractured.
4/20/2015	30	fract--	#18 fractured to the gum line, recurrent caries #20, 28, 29, 30,
4/20/2015	30	fract--	Dental: #18 fractured to the gum line, recurrent caries #20, 28, 29, 30
4/20/2015	30	fract--	#30- Fractured crown.

Date	Tooth	Key-No-Yes	phrase
4/21/2015	18	fx--root	O: BP: 104/56, HR: 70, H&N exam (WNL), Intraoral Fx: missing teeth, caries, root tip, Radiology Fx: possible root tip #3, root tip #8, caries, PARL #4 and 18, widened PDL #6 and 21
4/21/2015	30	fract--	#30 Gross caries with Distal cusps fractured off (Palpation-, Percussion ++)
4/22/2015	14	fract--	Fractured #14
4/22/2015	18	crack--	pt had restorability checked by grad endo and determined to be nonrestorable - #18 cracked tooth, #31 grossly carious
4/22/2015	31	crack--	pt had restorability checked by grad endo and determined to be nonrestorable - #18 cracked tooth, #31 grossly carious
4/22/2015	5	fract-elevat-root	Fractured root tips at site #5 after elevation/forceps.
4/23/2015	12	fract--	#12 fractured two days ago.
4/23/2015	15	fract--	#15-Fractured ML cusp with gross caries
4/23/2015	28	fract--	Gross Decay , fractured tooth 28
4/23/2015	30	broke--	30 still broken and asymptomatic, pt wants to leave alone for now
4/23/2015	30	broke--	#30 broken and asx
4/23/2015	30	crack--	#30 cracked and pt reports asx.
4/23/2015	30	crack--	DE: Dr stated #30 is cracked through the occlusal plane and has a periodontal abscess on the buccal leading to class two mobility.
4/23/2015	5	fract--	fractured teeth: 5, 9, 10, 27
4/23/2015	5	fract--	Dental: fractured teeth: 5, 9, 10, 27
4/24/2015	15	fract--	Fractured crown 15 and 16

Date	Tooth	Key-No-Yes	phrase
4/24/2015	15	fract--	Dental-Fractured crowns 15 and 16- non restorable
4/24/2015	15	fract--	Fractured crown 15 and 16
4/24/2015	19	fract--	#19 fractured crown
4/24/2015	19	broke--	Car accident shoulder injury, broken ribs 19 yrs
4/24/2015	19	fract--	Fractured #19
4/24/2015	19	fract--	Fractured and non restorable #19
4/24/2015	19	fract--	#19 Fractured
4/24/2015	2	fract--	S: PPTC with fractured #2
4/24/2015	2	fract--	Fractured #2
4/24/2015	2	fract--	Fractured #2 with 5x5mm PARL
4/24/2015	2	fract--	Fractured #2 - EXT
4/24/2015	2	broke--	#2 has no pain but patient reports the entire crown is broken now.
4/24/2015	20	broke--	July 2013- hip surgery, no replacment was done, metal parts were used to connect the broken pieces
4/27/2015	12	fract--	Fractured crown: #12
4/27/2015	12	fract--	Fractured crown (at gingiva): #12
4/27/2015	12	fract--	Fractured crown (at gingiva): #12 - Ext
4/27/2015	15	fract--	Fractured #15, 30
4/27/2015	19	fract--vertical	Tooth #19 with vertical root fracture with temporary core material in place.
4/27/2015	19	fract--vertical	Panorex/PA: Vertical fracture extending through furcation of tooth #19 with small furcal radiolucency.

Date	Tooth	Key-No-Yes	phrase
4/27/2015	19	fract--vertical	Tooth #19 with vertical root fracture and deemed non-restorable.
4/28/2015	13	fract--	Dental: #13 irreversible pulpitis with symptomatic apical periodontitis due to extensive coronal fracture.
4/28/2015	13	fract--	#13 coronal fracture
4/28/2015	13	fract--	Coronal fracture #13
4/28/2015	13	fract--	#13 coronal fracture to level of gingiva
4/29/2015	18	broke--	broken #18
4/29/2015	18	broke--	broken down #18
4/29/2015	5	fract--	Fractured #5 when eating, reports sensitivity to cold, spontaneous, wakes up in the night
4/30/2015	12	split--	Discussed with patient the implants perio has tx planned in #3,4,12,18,19- patient is going to split up treatment due to finances and work on upper first.
4/30/2015	21	broke--	Patient also states he wants the other broken tooth #21 extracted.
4/30/2015	30	fx--	gross caries #3 (fx crown), 14, 19, 30,31
4/30/2015	30	fx--	Dental: gross caries #3 (fx crown),14,19,30,31, plaque present on all teeth
5/1/2015	3	fract--	fractured D marginal ridge of tooth #3
5/4/2015	12	fract-amalgam-	Clinical examination shows fractured mesial amalgam on #3MODL and fistula between #12 and #13.
5/4/2015	12	fract--	Since #12 has a fractured core build up and recurrent decay, advised to have #12 retreated in grad endo.

Date	Tooth	Key-No-Yes	phrase
5/4/2015	12	fract--	Clinical Exam: #12 fractured core build up with secondary decay
5/4/2015	12	fract--	Intraoral exam: Fractured DOBL aspect of #12 with MD fracture, class 3 mobile lingual segment
5/4/2015	12	fract--	#12: Fractured coronal tooth structure 2mm from crestal bone with MD fracture separating L cusp from B cusp, hyperplastic gingiva on D aspect of tooth obscuring D tooth structure, two canals obturated
5/4/2015	12	broke--	Patient was seen in grad endo for #12 retreat earlier this week, which had broken off and was deemed nonrestorable.
5/4/2015	12	split--	A: #12 fractured/split tooth, 6mm PD mesial and 7 mm distal.
5/4/2015	12	fract-elevat-root	Buccal root tip of #12 fractured, was elevated and delivered w/o complication.
5/4/2015	13	fract-amalgam-	Diagnosis Fractured amalgam, #13MODL
5/4/2015	13	fract-amalgam-	Clinical examination shows fractured mesial amalgam on #3MODL and fistula between #12 and #13.
5/4/2015	13	fract--	#13 has recurrent decay and a fractured crown which patient elects to have extracted.
5/4/2015	13	fract--	#13 fractured crown with secondary decay
5/4/2015	20	fract--	#20 - fractured, PA RL
5/4/2015	20	fract--	EXT #20 - fractured, caries
5/4/2015	20	fract--	#20 - fractured, caries, extreme sensitivity to percussion
5/4/2015	20	fract--	fractured #20, extreme percussion sens
5/4/2015	20	fract--	#20 - fractured

Date	Tooth	Key-No-Yes	phrase
5/4/2015	30	fract--	#30 - fractured restoration, furcation involvement, non-restorable
5/4/2015	30	fract--	#30 - fractured restoration, furcation involvement
5/5/2015	15	fract--	1) fractured and non-restorable #15 with symptomatic apical periodontitis
5/5/2015	15	crack--	#15 - symptomatic apical periodontitis, cracked tooth
5/5/2015	3	crack--	Cracked #3
5/5/2015	3	crack--	#3 sensitive to percussion and lingual crack present
5/5/2015	5	fract--	Bilateral mandibular tori, Fractured crowns on 2,5,15
5/5/2015	5	fract--	Fractured crowns 2, 5, 15
5/5/2015	5	fract--	Dental- multiple fractured teeth (2, 5, 15) in need of extraction
5/5/2015	5	fract--root	Fractured #3, #5, retained mesial root #30
5/5/2015	5	fract--	Fractured #3,#5
5/5/2015	5	fract--	Fractured #3, #5, #30
5/6/2015	20	broke--	Broken tooth #20 - Previous RCT
5/6/2015	3	fract--	#3 DL cusps fractured, pulp exposed.
5/7/2015	14	broke--	Broken #14 filled w/ OTC tooth filling material.
5/7/2015	14	broke--	Broken #14 filled w/ OTC tooth filling material.
5/7/2015	14	fract--	Cariious & Fractured #14
5/7/2015	14	broke--	#14 broke about a month ago.
5/7/2015	18	fract--	DB cusp fracture #18

Date	Tooth	Key-No-Yes	phrase
5/7/2015	18	fract--	Previously NSRCT treated #18, subgingival fracture on DB cusp
5/7/2015	18	fract--	non-restorable #18 due to fracture, temporary fillings has been missing for several months
5/7/2015	31	fract--	#31 fracture: EXT (non restorable)
5/7/2015	31	fract--vertical	#31 vertical fracture
5/7/2015	31	fract--root	#31-root fracture.
5/7/2015	31	fract-amalgam-root	#31- large fractured amalgam restoration close to bone, percussion sensitive, PAP both roots
5/7/2015	31	fract-amalgam-root	#31- fractured amalgam restoration, PAP around mesial and distal roots
5/7/2015	31	fract-amalgam-	#31- fractured amalgam restoration close to bone, percussion sensitive
5/8/2015	19	fract--	Crown fracture #19, non-restorable
5/8/2015	19	fract--	Crown fracture #19, non-restorable EXT
5/13/2015	4	broke--	Tooth #4 has coronal fracture and #17 is grossly broken down.
5/13/2015	4	crack--	Top right tooth cracked off 6 months ago and began causing pain 4 days ago.
5/14/2015	12	fract-porcelain-	A: Generalized marginal gingivitis, Endo treated #12, Caries #2 MO and #5DO, Fractured porcelain on #8 PFM
5/14/2015	12	fract--	#12 was retreated in grad endo, in oct of 2012, composite restoration had a fracture line , but did not progress to the pulp chamber.
5/14/2015	20	fract--	#18 fractured to the gum line, recurrent caries #20, 28, 29, 30,
5/14/2015	20	fract--	Dental: #18 fractured to the gum line, recurrent caries #20, 28, 29, 30

Date	Tooth	Key-No-Yes	phrase
5/14/2015	20	fract--	#20 fractured to gum line and wire post sticking out of canal.
5/14/2015	3	fract--	Fractured non-restorable #3
5/14/2015	3	fract--	Fractured endo-treated #3
5/14/2015	3	fract--	Fractured #3ML
5/14/2015	31	fract-elevat-	Tooth #31 elevated, crown fractured and delivered w/ forcep.
5/15/2015	12	fract--root	Teeth fractured at gumline with retained root tips #2, 12, 15, 30, 31
5/15/2015	12	fract--	Fractured #12 - non-restorable
5/15/2015	13	fract--	Fractured tooth 2, 13.
5/15/2015	14	broke--	#14 broken restoration, gross caries
5/15/2015	15	fract--root	Teeth fractured at gumline with retained root tips #2, 12, 15, 30, 31
5/15/2015	18	fract--	Fractured teeth: 4, 5, 12, 17, 18, 31
5/15/2015	5	fract--	#5 - fractured, non-restorable
5/18/2015	14	split--root	#14 - surgical extraction - split tooth and split 3 root
5/18/2015	3	split--root	#3 surgical extraction - split tooth and split 3 roots, removed 3 roots with rongeur
5/18/2015	3	split--root	#14 - surgical extraction - split tooth and split 3 root
5/18/2015	4	fract--	A: #4 fractured mesial-distally.
5/18/2015	4	crack--	P: Patient concerned with the crack on #4, however it is not symptomatic.
5/18/2015	4	fract--	Fractured tooth #4
5/18/2015	4	fract--	PPTC with fractured tooth #4

Date	Tooth	Key-No-Yes	phrase
5/19/2015	13	fract--	Dental: Gross caries #13, fractured crown, symptomatic apical periodontitis
5/19/2015	15	fract--	Fractured tooth #15 due to gross caries.
5/19/2015	18	fract--	#18 crown fractured off approx 4 months ago.
5/19/2015	4	fract--	#4- Large caries, fractured
5/19/2015	4	fract--	#4-, gross caries, fracture
5/19/2015	4	fract--	Tooth 4 has been fractured for over 6 months
5/19/2015	4	fract--	fractured tooth #4.
5/19/2015	4	fract--	Fractured tooth 4,
5/19/2015	4	fract--	Dental: fractured #4, right facial swelling.
5/19/2015	4	fract--	Fractured #4
5/20/2015	3	fract-amalgam-	Fractured amalgam on tooth #3: unrestorable
5/20/2015	3	fract-amalgam-	Fractured amalgam on tooth #3
5/20/2015	31	crack--	Gross decay and cracked #2, 31
5/20/2015	4	fract--	#4 has been fractured and has acute pain associated with percussion.
5/20/2015	4	fract--root	Crown and root fracture #4
5/20/2015	4	fract--	Crown of #4 eventually fractured 5/18/15.
5/21/2015	18	fract--	#18 Gross decay, fractured cusp.
5/21/2015	18	fract--	tooth #18 has a large temporary restoration as well as a fractured cusp.
5/21/2015	31	fract--	#31- NSRCT, recurrent decay, fractured
5/22/2015	31	fract--	Gross caries #14,15,fractured cusp #31
5/22/2015	31	fract--	Gross caries #14,15, #31 fractured cusp

Date	Tooth	Key-No-Yes	phrase
5/26/2015	14	fract--	Dental: Fractured #14- tooth restorable w/ endo/crown, pt elects for extraction
5/26/2015	14	fract--	Fractured #14
5/26/2015	19	broke--	Med: Prior surgery for broken leg, 1995
5/26/2015	19	fract--	#19-DL cusp fractured off
5/26/2015	19	broke--	Broken leg 1995
5/26/2015	19	fract--	Fractured Crown #19
5/26/2015	19	fract--	fractured crown #19
5/26/2015	31	fract--	gross caries and fractured tooth #31
5/26/2015	4	fract--	#4 fractured off at gingiva, deemed unrestorable.
5/27/2015	13	broke--	July 2013- hip surgery, no replacment was done, metal parts were used to connect the broken pieces
5/27/2015	19	broke--	Broken nose - 1998
5/27/2015	2	broke--	July 2013- hip surgery, no replacment was done, metal parts were used to connect the broken pieces
5/27/2015	3	broke--	July 2013- hip surgery, no replacment was done, metal parts were used to connect the broken pieces
5/27/2015	31	fract--	O- 130/85, #31 asymptomatic, 31-MODBL core buildup fractured on the mesial
5/27/2015	4	fract--	- #4 fractured on mesial
5/27/2015	4	fract-amalgam-	#4 presents with fractured amalgam restoration with clinical recurrent caries and radiographic distal caries approximating pu
5/28/2015	12	fract--	Fractured, carious teeth #12,13 that are tender to palpation/percussion.

Date	Tooth	Key-No-Yes	phrase
5/28/2015	13	fract--	Fractured, carious teeth #12,13 that are tender to palpation/percussion.
5/28/2015	14	broke--	Pt states there is no pain associated with the tooth and points to #14, no hx of edema and that the tooth broke a few weeks ago.
5/28/2015	28	fract--	Tooth #28 gross caries/fractured
5/28/2015	28	fract--	Fractured #28
5/28/2015	28	fract--	#28 caries/fractured
5/28/2015	28	fract--	Fracture/caries #28
5/28/2015	29	fract--root	#30 fractured crown, #29 root tip PAP
5/28/2015	30	fract--root	#30 fractured crown, #29 root tip PAP
5/28/2015	4	fract--	Dental findings: Fractured crown on tooth #4 and #18
5/28/2015	4	crack--	Cracked crown on Tooth #4.
5/28/2015	4	crack--	Cracked tooth #4
5/28/2015	5	fract--	Fractured tooth #5
5/28/2015	5	fract--	fractured tooth 5 RL tooth 5
5/29/2015	15	broke-amalgam-	Diagnosis broken amalgam #15
5/29/2015	15	crack--	transillumination revealed evidence of a crack on the distal marginal ridge of tooth #15
5/29/2015	15	crack--	Visual cracks on D of #15
5/29/2015	15	crack--	Due to #15 having evidence of cracks, it being the most posterior tooth, and occluding on only approx.
5/29/2015	15	crack--	#15: cracked,non-restorable
5/29/2015	15	crack--	Dental: #15 cracked tooth

Date	Tooth	Key-No-Yes	phrase
5/29/2015	18	fract-amalgam-vertical	Tooth #18 with large occlusal amalgam filling with vertical fracture extending between the mesial and distal marginal ridges below the CEJ.
5/29/2015	18	fract-amalgam-vertical	Tooth #18 with large amalgam, vertical fracture through mesial and distal marginal ridges, and acute apical periodontitis.
5/29/2015	20	broke--	HPI: Patient broke her front tooth (#8) eating a sub sandwich in May 2014.
5/29/2015	31	fract--	#31 Fractured DL cusp, percussion +
5/29/2015	4	fract--	Fractured #1 ,4, 16
6/1/2015	13	fract--	Grossly carious/fractured tooth #13
6/1/2015	29	broke--	broken #29
6/1/2015	29	broke--	#29 broken and nonrestorable
6/1/2015	29	broke--	pt,s tooth broke 2 weeks ago pointing on #29.
6/1/2015	5	broke--	broken crown #5
6/2/2015	15	fract-elevat-root	#15: Elevated root tips out individually following intentional coronal fracture with root separation.
6/2/2015	15	fract--	Fractured tooth #15 at gingiva
6/2/2015	15	fract--	fractured #15, non-restorable
6/2/2015	18	fract--	Dental: #18 - fractured DL cusp - buccal, lingual swelling present - diagnosed as necrotic pulp with chronic apical abcess
6/2/2015	18	fract--	#18 - PARL, fractured cusp
6/2/2015	18	fract--	#18 - fractured DL cusp
6/2/2015	19	fract--	#19 Gross caries and Fractured crown
6/2/2015	2	fract-elevat-	#2: Fractured crown with attempted elevation.
6/2/2015	29	fract--	Fractured #29

Date	Tooth	Key-No-Yes	phrase
6/2/2015	3	fract--	Repaired fractured MIFL procelain on tooth #8 with procelain repair kit using Z250 composite shade A3.5.
6/2/2015	30	broke--	#30 broke down about a month ago, pain associated since.
6/3/2015	2	fract--	HPI: Patient also has concerns about UR molar area where #2 is fractured and extruded.
6/3/2015	29	fract--	#29 is fractured
6/3/2015	29	fract--	Fractured #29
6/4/2015	12	fract--root	#2 root tip #12 fracture crown
6/4/2015	12	fract--	Was hit on the face and #12 and #2 fractured.
6/4/2015	12	broke--root	Pt mentioned he tried to pull #12 out but the root broke on him.
6/4/2015	19	fract--	#19 fractured tooth two weeks ago, pt reports swelling and pain associated with the lower left mandible for the past week.
6/4/2015	2	fract--root	#2 root tip #12 fracture crown
6/4/2015	2	fract--	Was hit on the face and #12 and #2 fractured.
6/4/2015	2	broke--root	Pt mentioned he tried to pull #12 out but the root broke on him.
6/4/2015	2	fract--	crown fracture #2
6/4/2015	2	fract--	fracture crown #2
6/4/2015	30	fract--vertical	#30: vertical fracture through DL cu
6/4/2015	30	fract--	#30 distal marginal ridge is fractured, and sensitive to percussion
6/4/2015	30	fract--	#30 distal is fractured.
6/4/2015	30	fract--	#30 fractured d marginal ridge

Date	Tooth	Key-No-Yes	phrase
6/4/2015	31	broke--	Tooth broke apart about 5 days ago (pt points to #31).
6/4/2015	31	fract--	#31: perc +, palp +, fractured DL cusp (restorable)
6/4/2015	5	fract--	fractured #5, 26 and 25
6/4/2015	5	fract--	fractured #5,25,26
6/4/2015	5	fract--	Fractured #25,26,5
6/5/2015	14	fract--	#14 fractured crown
6/5/2015	14	fract--	Fractured crown #14
6/5/2015	14	fract--	Dental: fractured MO restoration #14
6/5/2015	14	fract--	Fractured MO restoration #14, no PARL #14
6/5/2015	14	fract--	Fractured MO restoration #14, sensitive to percussion
6/5/2015	15	fract--	#15 crown and tooth structure fractured.
6/5/2015	15	broke--	#15 crown broken.
6/5/2015	15	broke--	Last week #15 crown broke off.
6/5/2015	18	fract--	fractured/gross caries #18
6/5/2015	18	fract--	dental: fractured crown #18
6/5/2015	18	fract--	fractured #30, 18
6/5/2015	18	fract--	Carious/fractured tooth #18
6/5/2015	18	fract--	Gross caries and fractured #18
6/5/2015	19	fract--	#19 - fractured restoration
6/5/2015	19	fract-amalgam-	Amalgam filling fracture tooth #19, tooth has been symptomatic for several days.
6/5/2015	29	broke--	broken teeth #29

Date	Tooth	Key-No-Yes	phrase
6/5/2015	29	broke--	Broken #29
6/5/2015	31	fract--	Fractured #31.
6/8/2015	13	fract--	Fractured #13, causing discomfort
6/8/2015	13	fract--	Fractured #13
6/8/2015	13	fract--	Tooth #13 fractured 2-3 months ago when eating a sandwich.
6/8/2015	13	fract--	Discomfort in fractured #13
6/8/2015	5	fract--	Grossly decayed, fractured #5
6/9/2015	15	fx--	close to #15 which has caries discused possible tooth fx
6/9/2015	18	broke-elevat-root	#18 elevated and delivered with cowhorn forceps, Buccal root broke and delivered with root tip pick
6/9/2015	18	fract--	patient states that #18 fractured 1 month ago and pain has gotten progressively worse, no spontaneous pain, pain/sensitivity during drinking and chewing
6/9/2015	31	fract--	#31 fractured, sensitive to percussion
6/9/2015	31	fract--	dental - fractured #29, #31
6/9/2015	31	fract--root	dental - #31 fracture, caries, restorable, explained cost and process of restoration (root canal, crown) patient decided to have tooth extracted.
6/9/2015	4	fract--root	#4 retained root tip, #5 fractured lingual cusp, #6 buccal and distal caries
6/10/2015	14	crack--	Teeth #14, #23, #24, #25, #26 are cracked
6/10/2015	18	fract--	Fractured #3, Grossly decayed #18
6/10/2015	29	fract--	52 yo F referred for evaluation and extraction of fractured, non-restorable tooth #29.

Date	Tooth	Key-No-Yes	phrase
6/10/2015	29	fract--root	PA: Tooth #29 with fracture and loss of coronal tooth structure with retained roots.
6/10/2015	29	fract--	Fractured, non-restorable, symptomatic tooth #29.
6/10/2015	3	crack--	#3 cracked DL
6/10/2015	3	broke--	Broke leg in 2013, Spiral fracture 4 places has a full titanium rod in ankle
6/10/2015	5	broke--	#3, 5 & 6 broken down and carious
6/11/2015	19	fract--vertical	It was determined that #19 was endo treatment earlier in private practice, later apicectomy was done and then developed vertical fracture.
6/11/2015	29	fract--	#29 D Fracture with gross caries.
6/11/2015	29	fract--	#29 D fracture due to gross caries.
6/11/2015	30	broke--	#30 brokent tooth with a slight lingual cusp tip present.
6/11/2015	30	broke--	#30 Broken tooth with apical radiolucency.
6/11/2015	31	fract--root	#31 has a large threaded post and PA from 1/30/12 shows evidence of possible D root fracture.
6/11/2015	5	fract--root	#4 retained root tip, #5 fractured lingual cusp, #6 buccal and distal caries
6/11/2015	5	fract--	#5 lingual cusp fracture
6/11/2015	5	fract-amalgam-	#5 MOD amalgam with fractured lingual cusp and exposed dentin,
6/12/2015	15	fx--	#15-fxt crown, nonrestorable
6/12/2015	29	fract--	#29 fractured - non restorable
6/12/2015	4	fract--	Referred from Screening for generalized PD 4-7mm, supra/subgingival calculus, fractured teeth

Date	Tooth	Key-No-Yes	phrase
6/15/2015	30	fract--	1.) CBCT to confirm possibility of fracture at MB line angle #30.
6/15/2015	30	crack--	Axial: Tooth #30 Possible crack visualized at ML canal.
6/16/2015	13	fract--	Fractured #13
6/16/2015	19	fract--	Gross caries/fracture #19- restorable w/ endo/crown, pt elects to ext
6/16/2015	3	fract--	Fractured crowns: #4, 6, 8, 9, 11, 19, 20, 30
6/16/2015	4	fract--	Fractured crowns: #4, 6, 8, 9, 11, 19, 20, 30
6/17/2015	14	fract--	Significant finding: fractured buccal cusp #14, no evidence of abscess/suppurative drainage, no pain on percussion or palpation.
6/18/2015	19	fract--	Fractured #19
6/18/2015	19	fract--	Cariou fracture #19
6/18/2015	28	broke--	#28 broke and pain presented as constant throbbing for 1 week.
6/18/2015	28	fract--	gross caries/fractured #28
6/18/2015	5	fract--	Dr evaluated previously treated endo tooth #5 which had a large fracture MD to bone (10mm probing depths on M and D).
6/19/2015	18	broke--	A: Broken ML cusp of 18.
6/19/2015	18	fract--	Diagnosis fractured ML cusp of 18.
6/19/2015	18	fract--	HPI: Fracture restoration on #18
6/19/2015	18	fract-amalgam-	Intraoral hard tissue: Occlusal fracture on amalgam restoration #18
6/19/2015	18	broke--	Pt points to lower left molar (#18) and states it is broken and painful.

Date	Tooth	Key-No-Yes	phrase
6/19/2015	19	fract--	ORIF of pelvic fractures in 1998
6/19/2015	28	fract-elevat-	Elevated small FTMP on buccal of teeth #6,11,28 as the crowns fractured off in attempted elevation.
6/19/2015	30	fract--	#30 fractured distal marginal ridge
6/22/2015	14	fract--	Fractured #14 DL, SAP
6/22/2015	14	fract--	#14 - fractured distal lingual cusp, sensitive to percussion, PARL.
6/22/2015	14	fract--	#14 - fractured DL cusp, sensitive to percussion
6/22/2015	14	crack--	Pt states #14 cracked in March 2014.
6/22/2015	15	fract--	fractured tooth #15 that is tender to percussion
6/22/2015	15	fract--	Patient was referred by grad endo due to fractured tooth #15 that is non-restorable.
6/22/2015	15	fract--	Fractured, non-restorable tooth #15 referred by VCU Endo for extraction.
6/22/2015	20	fract--	#20 fracture to gingiva; multiple teeth fractured, mandibular tori
6/22/2015	20	fract--root	#20 root canal treated, crown fractured off
6/22/2015	20	fract--	Dental: #20 crown fractured
6/22/2015	30	fract--	#30: fractured distal.
6/22/2015	4	fract--	S: PPTC for problem-focused exam of fractured tooth #4.
6/23/2015	19	crack--	PPTC referred from UG w/ cc: I was eating pork chops and cracked my tooth. Pt points to #19.
6/23/2015	2	broke--	broken crown on #2
6/23/2015	5	fract--	Fractured #5 Mesiodistally
6/23/2015	5	fract--	Dental findings: Fractured #5

Date	Tooth	Key-No-Yes	phrase
6/23/2015	5	fract--	Fractured, non restorable #5
6/23/2015	5	fract--	#5 fractured mesiodistally and determined non-restorable.
6/24/2015	14	fract--	fractured tooth 14.
6/24/2015	18	fract--	#18, 19 fractured crown
6/24/2015	18	fract--	Fractured #18,19
6/24/2015	19	fract--	#18, 19 fractured crown
6/24/2015	19	fract--	Fractured #18,19
6/24/2015	19	broke--	grossly broken down #19 which was previously endo treated about 6 years ago.
6/24/2015	19	broke--	broken #19 multiple resorations.
6/24/2015	19	broke-forcep-root	#19 was grossly broken down.Remaining part of the crown broke down after application of forceps.Contrangle handpiece with straight burr was used to section the roots and trim the interceptal bone.Root
6/25/2015	13	fract--	#13 fractured.
6/25/2015	15	fract-amalgam-	A: #15-DO Amalgam w/ recurrent decay and buccal cusp fractured off.
6/25/2015	15	fract-amalgam-	15 amalgam fractured on distal.
6/25/2015	18	fract--	Slightly fractured restoration #18
6/25/2015	2	fx--	O: CompExm / MedDentHxReviewed / 131/72=81 / FMX / Perio Charting / #8 is CI3 mobile without pain / #12 lingual cusp Fx gross decay / Generalized sub gingival calc / Heavy coffee staining
6/25/2015	30	fract--	Hard tissue exam Abfraction #20-F, Crown margin defect #30-D and MB, Check 5-L and 7-F composite margins.

Date	Tooth	Key-No-Yes	phrase
6/25/2015	31	fract--	Fractured: #13, #31
6/25/2015	31	fract--	Grossly carious and fractured #31
6/25/2015	31	fract--	Dental findings: Fractured #14 and #31
6/25/2015	31	fract--	Fractured #13 and #31
6/25/2015	31	fract--	dental: #31, gross caries, fracture, SAP, necrotic pulp
6/25/2015	31	fract--	#18 and #31 gross caires and fractures, generalized calculus, B, M impacted #32
6/25/2015	31	fract--	#31, non restorable, fractured
6/26/2015	20	fract--root	-lower left tooth (#20) has fractured crown with only root tips left giving spontaneous pain, traps food, swelling over the weekend
6/26/2015	30	fract--	#30 crown fractured, no other findings
6/26/2015	30	fract--	#30 previously endo treated, with fractured crown into the pulp.
6/26/2015	30	fract--	#30 crown fractured to pulp, is non restorable as caries are below bone level
6/29/2015	13	fract--	#4 1nd 13 fractured subgingivally.
6/29/2015	14	fract--	#14 DO caries/fracture.
6/29/2015	18	fract--	Extraction un-eventful but carious distal portion of #18 fractured during procedure.
6/29/2015	19	broke--	S:PPTC for operative CC: part of my tooth broke off- patient reports #19 fractured further 10 days ago
6/29/2015	31	fract--root	RL around roots #31 consistent with fracture
6/29/2015	31	fract--	Fracture #31
6/29/2015	31	fract--root	#31 root fracture.

Date	Tooth	Key-No-Yes	phrase
6/29/2015	31	fract--	Fracture #31: EXT
6/29/2015	4	crack--	Additional Narrative #14 Potential crack on Distal or missed MB2, #12 and 15 endo testing inconclusive due to calcified pulp space.
6/29/2015	4	fract--	#4 1nd 13 fractured subgingivally.
6/29/2015	4	fract--	Fractured #3 and #14 below the gumline
6/30/2015	12	fract--	#12: Fractured crown.
6/30/2015	12	fract--	#12 Fractured crown & 4mmx4mm PARL
6/30/2015	3	fract--	gross decay #3 with fractured crown
6/30/2015	3	fract--	fractured crown with gross decay #3
6/30/2015	3	fract--	dent: gross decay with fractured crown #3
6/30/2015	30	fract--	Fractured #30
6/30/2015	30	fract--	Fractured #30, RCT tx
6/30/2015	30	fract--	#30 fractured.
7/1/2015	14	broke--	Broken #4,, Carious #14, #19
7/1/2015	14	broke--	Broken #14, Broken #19
7/1/2015	14	fract--	Fractured #14, carious #19, possible PAP #30
7/1/2015	14	fract--root	#14 Fractured crown, retained root tips, non-restorable
7/1/2015	14	fract--root	#14 Fractured crown, retained root tips, non-restorable - simple ext
7/1/2015	14	fract--root	Retained root tips noted at site #14 and mesial crown fracture noted on #19.
7/1/2015	15	fract--	Fractured tooth#15w/ caries, discussed need for EXT since tooth is non-restorable and supra-erupted.

Date	Tooth	Key-No-Yes	phrase
7/2/2015	12	fract--	fractured crowns #6-12
7/2/2015	13	fx--	O: CompExm / MedDentHxReviewed / 131/72=81 / FMX / Perio Charting / #8 is CI3 mobile without pain / #12 lingual cusp Fx gross decay / Generalized sub gingival calc / Heavy coffee staining
7/2/2015	2	fract--	fractured crowns #6-12
7/6/2015	14	fract--	O: BP - 143/95, Pulse 69, acrylic temporary in place, no fractures, distal post space prepared by grad endo
7/6/2015	15	fract--	Dental- palatal abscess with fractured, non restorable #15, #16 highly mobile and swollen as well. Pain around both teeth
7/6/2015	15	fract--	Pt indicates tooth fractured in April of 2015 and was asymptomatic, tooth fractured again a few days ago and has been painful since
7/6/2015	18	fract--	gross decay on #18, lesion on mesial of #17 noted as well as fractured cusp on #3
7/6/2015	19	fract-amalgam-	A: Existing extensive amalgam restoration on #19 with fractured cusp, existing amalgam restoration on #18
7/6/2015	31	fract--	Dental: Grossly carious #17 (symptomatic), Grossly carious/fractured #31 (asymptomatic)
7/6/2015	31	fract--	Grossly carious #31 (fractured crown)
7/6/2015	31	fract--	Grossly carious (and fractured #31).
7/6/2015	5	fract--	#5 fractured
7/6/2015	5	broke--root	Tooth #5 broke off, root is still present
7/7/2015	12	fract--	Grossly decayed and fractured #7, #9, and #12
7/7/2015	14	fract--root	Fractured #14 , root tip #3.

Date	Tooth	Key-No-Yes	phrase
7/7/2015	14	fract--	Fractured #14.
7/7/2015	14	fract--	Tooth #14 has no crown, is possibly fractured.
7/7/2015	18	broke--	#18 broken crown
7/7/2015	18	broke--	broken crown/ gross caries #18
7/7/2015	19	fract--	Fractured crowns: #4, 6, 8, 9, 11, 19, 20, 30
7/7/2015	19	fract--	#19 caries/fracture non-restorable
7/7/2015	19	fract--	Dental - #19 fractured, non restorable
7/7/2015	19	fract--	#19 fractured, non-restorable
7/7/2015	19	fract--	Pt reports that tooth #19 fractured about a year ago and has been causing him pain on and off for about 8 months.
7/7/2015	20	fract--	Fractured crowns: #4, 6, 8, 9, 11, 19, 20, 30
7/7/2015	20	fract--	Fractured tooth #20 at gingiva that is tender to percussion and palpation -- no erythema, edema, or drainage.
7/7/2015	20	fract--	Return to clinic for incisional biopsy of anterior mandibular lesion and extraction of fractured and symptomatic tooth #20
7/7/2015	28	broke--	#27,#28 broken crowns
7/7/2015	29	fract--	fracture crown and gross decay on #28,29,6
7/7/2015	29	fract--	fracture crown with gross decay: #28,29,6
7/7/2015	3	fract--root	Fractured #14 , root tip #3.
7/7/2015	3	crack--	Teeth #14, #23, #24, #25, #26 are cracked
7/7/2015	30	fract--	Fractured crowns: #4, 6, 8, 9, 11, 19, 20, 30
7/7/2015	31	broke--	#31 DB cusp broken off
7/7/2015	31	broke--	#31- DB cusp broken

Date	Tooth	Key-No-Yes	phrase
7/7/2015	4	crack--	Teeth #14, #23, #24, #25, #26 are cracked
7/8/2015	12	fract--	Tooth #12 fractured
7/8/2015	15	broke--	#15 missing most of crown, broke off about 6 months ago and pt reports pain of 4/10 and pain has started four days ago after another little piece of tooth broke off
7/8/2015	19	fract--	#19 is fractured
7/8/2015	19	fract--	Fractured nonrestorable #19
7/8/2015	2	fract--	Gross decay/ fractured crown on #2
7/8/2015	2	fract--	Gross decay and fractured crown on #2
7/8/2015	3	fract--	Gross Caries #3 and fractured crown
7/8/2015	4	fract--	Pt fractured tooth #4 recently and interested in ext #5 with implant in the future.
7/8/2015	4	fract--	Fractured tooth #4
7/9/2015	13	fract--	#13 Fractured restoration
7/9/2015	13	fract--	#13 and #20 fractured restorations
7/9/2015	13	fract--	#2, 13, 20, 30 fractured teeth
7/9/2015	13	fract--	#13 and #20 fractured restoration
7/9/2015	20	fract--	#20 fractured distally - very sensitive to palpation and percussion
7/9/2015	20	fract--	#20 fractured distally - PARL
7/9/2015	20	fract--	#20 fractured
7/9/2015	20	fract--	#20 fractured, pt elected EXT
7/9/2015	30	fract--	Dental: #30- fracture, possibly restorable with NSRCT, crwn legthening, core-build up, crown.
7/9/2015	30	fract--	#30 - fracture

Date	Tooth	Key-No-Yes	phrase
7/9/2015	30	fract--	#30- fracture
7/9/2015	30	fract--	Fractured tooth #30
7/9/2015	4	fract--	Gross Caries, Fractured Lingual Cusp, SAP #4
7/10/2015	18	fract--root	#1, 3, 6, 7, 8, 9, 10, 11, 13, 14, 15, 16, 17, 18, 19, 22 fractured/root tips/caries
7/10/2015	19	fract--root	#1, 3, 6, 7, 8, 9, 10, 11, 13, 14, 15, 16, 17, 18, 19, 22 fractured/root tips/caries
7/10/2015	2	fract--	#2-5 PFM bridge fractured
7/10/2015	3	fract--	#13 crown grossly fractured
7/10/2015	30	fract--	#30 fractured/caries, PAP
7/10/2015	30	fract--	#30 fractured/caries, sensitive to percussion and palpation
7/13/2015	12	broke--	Joint Replacement (right thumb) 2012, Broken leg, Appendectomy all with no complications
7/13/2015	14	fract--	Dental: Grossly fractured, non-restorable teeth #s 5 and 14.
7/13/2015	14	fract--	Tooth #14 grossly fractured to gumline
7/13/2015	14	fract--	Grossly fractured (to gumline) #s 5 and 14 (#14 previously RCT'ed)
7/13/2015	18	fract--	Crown of tooth #18 fractured off about two months ago.
7/13/2015	3	crack--	A: patient has had extensive work done in the past, there are some areas of reccurant decay and a cracked cusp #3
7/13/2015	3	crack--	#3 is non restorable due to a crack on the DL that extends beyond gingiva.
7/13/2015	3	fract--	#3 fractured and nonrestorable.

Date	Tooth	Key-No-Yes	phrase
7/13/2015	3	crack--	#3 non restorable due to crack on DL that extends below the gingiva.
7/13/2015	3	fract--	Fractured #3
7/13/2015	30	fract--	#30-DL fracture
7/13/2015	30	fract--	#30-DL crown fracture
7/13/2015	5	fract--	Dental: Grossly fractured, non-restorable teeth #s 5 and 14.
7/13/2015	5	fract--	Tooth #5 grossly fractured to gumline
7/13/2015	5	fract--	Grossly fractured (to gumline) #s 5 and 14 (#14 previously RCT'ed)
7/14/2015	14	fract--	Grossly carious teeth #'s 14,15, fractured #17
7/14/2015	14	fract--	Grossly carious teeth #'s 14,15, fractured 17
7/14/2015	2	fract--	fractured crown, tooth 2
7/14/2015	2	fract--	Fractured cusp on tooth 2 with associated pain
7/14/2015	31	broke--	Broken down and decayed #3, 5, 19, 31.
7/14/2015	31	fract--	#18, 19, 31 crown fracture
7/14/2015	31	fract--	#18,19, 31 crown fracture
7/14/2015	31	fract--	#18, 19, 31 fractured crowns due to carious lesions.
7/14/2015	4	broke--	1984- broken right ankle
7/14/2015	4	fract--	#4 fractured crown and caries extending to the pulp, PARL
7/14/2015	4	fract--	#4 gross caries and fractured crown
7/14/2015	4	fract--	#14- decay and fractured DB cusp
7/14/2015	4	fract--	#4 caries and crown fracture

Date	Tooth	Key-No-Yes	phrase
7/14/2015	5	broke--	Broken down and decayed #3, 5, 19, 31.
7/15/2015	12	fract--	A: Fractured #12, Grossly carious #15, Leukoplakia on lateral border of the tongue, Defective margin on #30, Cavitated les
7/15/2015	13	fract--	PA - #13 grossly fractured
7/15/2015	13	fract--	1) Grossly fractured #13
7/15/2015	13	fract--	#13 grossly fractured to gumline
7/15/2015	13	fract--	78 YOF with history of HTN, Colon surgery 2012 referred by AEGD (Dr) for grossly carious, fractured #13.
7/15/2015	13	fract--	Grossly fractured #13
7/15/2015	13	fract--	#13 - MMR fracture with underlying caries and SAP
7/15/2015	13	fract--	#13 gross caries, MMR fracture, SAP
7/15/2015	3	fract--	#2, 3, 15- fractured cusps
7/15/2015	3	fract--	Dental: Gross Decay and several fractured crowns- 2, 3, 15, 18
7/15/2015	31	fract--	Dental - #31 MO fractured restoration, gross caries, positive to percussion (#30 negative to percussion)
7/15/2015	31	fract--	#31 fractured MO restoration, SAP, gross caries on MO, generalized demineralization/caries
7/15/2015	31	fract--	#31 caries, fractured crown, PARL
7/15/2015	31	fract--	#31 - caries and fractured crown, PARL
7/15/2015	31	fract--	#31 - caries and fractured crown
7/15/2015	31	fract--	#31 - caries and fracture crown
7/16/2015	21	fract--	gross caries #21 with fractured crown

Date	Tooth	Key-No-Yes	phrase
7/16/2015	21	fract--	#21 fractured crown, SAP
7/16/2015	30	fract-forcep-root	EXT #30- forceps extraction, Mesial root fractured and wa
7/17/2015	19	fract--	Fractured cusp 19, SAP
7/17/2015	19	fract--	Fractured Crown 19 and 30
7/17/2015	19	fract--	Fractured cusps, gross decay, PARL 19
7/17/2015	3	fract--	#3 fractured about two months ago.
7/17/2015	3	fract--	Fractured #3 requiring extraction
7/17/2015	3	fract--	Fractured #3 with caries to the pulp.
7/17/2015	31	fract--	31yo A/A male presents to clinic with insignificant med hx, Grossly carious #31 with a DL fracture and severe pain.
7/17/2015	31	fract-elevat-	#31 was elevated, luxated, crown fractured.
7/17/2015	31	fract--	Gross decay #31 with a distal lingual fracture, SAP, #12 malpositioned palatally
7/17/2015	31	fract--	#31 crown fracture 1 year ago, pain started 2 days ago 9/10 VAS, Pt taken Ibuprofen & Tylenol the past 2 days.
7/17/2015	31	fract--	#31 fracture, gross caries - unrestorable
7/17/2015	31	fract--	#31 fracture, gross caries
7/17/2015	31	fract--	#31 crown fracture, gross caries - unrestorable
7/17/2015	31	fract-elevat-root	LA administered, elevated #31, crown fractured off, sectioned roots with handpiece, delivered roots with elevators
7/20/2015	12	fract--	fracture #12, gross caries, symptomatic apical periodontitis
7/20/2015	14	fract--	14 started to hurt since last month, fractured tooth

Date	Tooth	Key-No-Yes	phrase
7/20/2015	14	fract--	fracture tooth #14
7/20/2015	28	fract--	grossly carious #28, fractured crown
7/20/2015	28	fract-elevat-	Tooth #28 elevated, crown fractured and delivered w/ forcep.
7/20/2015	30	fract-elevat-	Buccal exostoses adjacent to tooth #30 reduced using fissure bur to score, and straight elevator to luxate and fracture off exostoses.
7/20/2015	4	broke-amalgam-	#4: positive to percussion , broken DO amalgam, negative to palpation
7/20/2015	4	broke-amalgam-	Dental: #4: positive to percussion , broken DO amalgam, negative to palpation.
7/21/2015	18	fract--	mesial cusp fracture tooth #18
7/21/2015	19	fract--root	#19,31 - Fractured crown, retained roots
7/21/2015	19	fract--root	Dental: #19,30,31 - Fractured crown, retained roots
7/21/2015	28	fract-elevat-	Tooth #28 elevated, crown fractured and delivered w/ forcep.
7/21/2015	31	fract--root	#19,31 - Fractured crown, retained roots
7/21/2015	31	fract--root	Dental: #19,30,31 - Fractured crown, retained roots
7/21/2015	31	fract--	has been a long time since the crown on #31 fractured off.
7/21/2015	4	broke--	consult for broken non restorable 4, reievew med hx.
7/21/2015	5	fract--	Fractured cusp, Gross decay #5
7/21/2015	5	fract--	Dental: Fractured cusp and decay on #5
7/22/2015	15	fract--	gross decay & fracture of #15

Date	Tooth	Key-No-Yes	phrase
7/22/2015	15	fract--	gross decay & fracture #15
7/22/2015	15	fract--	dental: gross decay & fracture of #15
7/22/2015	15	fract--	#15 Fractured crown and gross decay
7/22/2015	15	fract--	#15 fractured crown and gross decay
7/22/2015	15	fract--	Dental: #15 and 31 fractured crown and gross decay
7/22/2015	15	fract--	#15 Gross decay and fractured crown
7/22/2015	3	fract--	#3 RCT and large restoration, occlusal decay present, deep fracture on lingual, percussion and palpation sensitive (Symptomatic Apical Periodontitis)
7/22/2015	3	fract--	Symp Apical Periodontitis, fracture #3
7/22/2015	30	fract--	large fractured retoration on #30
7/23/2015	13	fract--	#13: Gross decay w/ fractured cusp subgingival
7/23/2015	13	fract--	#13: Gross decay w/ fractured cusp
7/23/2015	13	fract--	Gross decay w/ fractured cusp #13
7/23/2015	14	fx--	Symptomatic Apical Perio, fx/decay #14
7/23/2015	14	fract--	Gross decay/fracture #14
7/23/2015	18	broke--	19 yo F states that the tooth(#18) broke last year , saw a dentist and was told that the options are either endo or ext.
7/23/2015	18	fract--	fracture tooth #18 symptomatic upon percussion ++
7/23/2015	19	fract--	#19 fractured crown
7/23/2015	19	fract--	#19 gross decay w/ fractured lingual cusps
7/23/2015	19	fract--	#19 fractured L cusp

Date	Tooth	Key-No-Yes	phrase
7/23/2015	19	fract--	Fractured #19 with caries
7/23/2015	3	fract--	#3 - recurrent decay, fractured crown
7/23/2015	3	fract--	#3 - fractured restoration on distal, recurrent decay
7/23/2015	3	fract--	Dental: #3 - fractured restoration, recurrent decay, explained to the pt that the tooth may be saved by RCT.
7/24/2015	18	fract--	#18 Crown Fracture
7/24/2015	18	fract--	#18 Crown Fracture-Positive to percussion
7/27/2015	2	fract--	h/o ECT for refractory depression (2012)
7/27/2015	3	crack--root	Unable to confirm today if #3 has a cracked root, or has some persistent apical disease or has some periodontal etiologies.
7/27/2015	30	fract-forcep-	Forceps used and crown fractured tooth #30.
7/28/2015	12	fract--	Caries on #6, #15, gross decay and fractured cusp on #12
7/28/2015	14	broke--	Dental History Patient has had 2 reported endodontic retreats on #14 at VCU since the original treatment in Greece in 1999 and reports a file was broken in this tooth and left.
7/28/2015	14	broke--	Additional Narrative Given the history of this tooth of multiple retreats and a broken file, endo retreat is not favorable and an apicoectomy may be indicated in order to treat #14.
7/28/2015	18	broke--	Pt reports #18 broke approx a month ago, pain began yesterday.
7/28/2015	2	fract--vertical	O: #13 non-restorable due to a lingual vertical fracture involving 1/2 of root surface.
7/28/2015	28	fract--	#28 Fractured with gross caries

Date	Tooth	Key-No-Yes	phrase
7/28/2015	28	fract--	Dental: #28 fractured and symptomatic
7/28/2015	31	crack--	#31 Caries and cracked on lingual
7/28/2015	31	crack--	Caries #31 and cracked on the lingual, symptomatic
7/28/2015	31	fract--	Fractured tooth and gross caries #31
7/29/2015	15	fract--root	#15 crown fractured, root sectioned and removed with east/west and rongeurs.
7/29/2015	18	broke--	#18 broken DL cusp
7/29/2015	18	broke--	Broken DL cusp #18
7/29/2015	18	broke--root	#18 broken DL cusp and PAP distal root
7/29/2015	19	fract--	#19 fractured crown with surrounding edematous gingiva
7/29/2015	19	fract--	#19 crown fracture.
7/29/2015	30	fract--	Pt states that tooth #30 fractured ~2 years ago, and reports intermittent pain/swell
7/29/2015	30	fract--	Fractured, previously endo tx tooth #30
7/29/2015	30	fract--	Grossly carious/fractured tooth #30
7/30/2015	13	broke--	Broken filling/lingual cusp #13
7/30/2015	13	broke--	caries, broken cusp/filling #13
7/30/2015	13	broke--	Broken filling/ lingual cusp #13 with symptomatic apical periodontitis.
7/30/2015	14	fract--	caries, fractured tooth #14
7/30/2015	15	fract--	#15 has gross caries and is fractured on the distal buccal
7/30/2015	15	fract--	Fractured #15 with gross decay

Date	Tooth	Key-No-Yes	phrase
7/30/2015	15	fract--	Extraction of fractured and decayed tooth #15 to alleviate pain and prevent infection
7/30/2015	15	fract--	#15 fractured 6 months ago and started hurting for the past month or 2.
7/30/2015	15	broke--	Tooth in my upper left broke (#15)
7/30/2015	2	fract--	dental: #2 fractured ML cusp
7/30/2015	2	fract--	#2 fractures ML cusp
7/30/2015	29	fract--	#29 Crown fractured off, previous endo
7/30/2015	29	fract--	Fractured Crown #12, #13, #29
7/31/2015	18	fract--	#18 gross decay, distal cusp fracture
7/31/2015	18	fract--	Large cavitated caries/ crown fracture #18,
7/31/2015	19	fract--	#19 D fracture and type 2 mobile
7/31/2015	2	fract--	caries: #2 (fractured crown due to caries)
7/31/2015	2	fract--	Cariou lesion #2, fractured crown due to caries,
7/31/2015	2	fract--	#19 D fracture and type 2 mobile
7/31/2015	2	fract--	#2 Fractured, gross decay
7/31/2015	2	fract--	#2 Gross caries and fracture
7/31/2015	2	broke--	Tooth has been broken and decayed for 3 or more months and has been causing him pain for the past 2 weeks.
7/31/2015	28	fract--	Pt presents with pain and fractured crown on #28.
7/31/2015	29	fract--	Fractured non restorable teeth 4, 10, 28, 29.
7/31/2015	29	fract--	Fractured crowns: #4, 10, 29, 32
8/3/2015	18	fract--	A: #18 fractured and

Date	Tooth	Key-No-Yes	phrase
8/3/2015	18	fract--	2x3 mm traumatic ulceration left lateral tongue (adjacent to fractured #18), white coated tongue
8/3/2015	18	fract--	#18 Defective Restoration/Fracture, Carious-Positive to percussion
8/3/2015	18	fract--	#18 Defective Restoration/Fracture
8/3/2015	19	fract--	Dental History PPTC with fractured tooth #19
8/3/2015	19	fract--	Dental History #19 - history of pain 4-5 months ago, 10/10 pain at the time, tooth fractu
8/3/2015	19	broke--	"Bottom left tooth broke (#19) and it hu
8/3/2015	19	crack--	#19- Reviewed treatment options with patient (do nothing, endo crown), Possible cracked teeth.
8/3/2015	2	fract--	2x3 mm traumatic ulceration left lateral tongue (adjacent to fractured #18), white coated tongue
8/3/2015	31	fract--	Non restorable tooth 31/ fractured cusp
8/3/2015	31	fract--	fractured distal cusp on 31,
8/4/2015	12	broke--	Grossly carious and broken down #12 and 31.
8/4/2015	12	broke--	#12 and 31 are broken down carious.
8/4/2015	13	fract-elevat-	#13: Fractured crown off with attempted elevation.
8/4/2015	13	fract--root	Fracture line extending through the root of tooth #13.
8/4/2015	13	fx--vertical	#13: vertical fx.
8/4/2015	13	fx--vertical	#13: vertical fx through center of the crown.
8/4/2015	18	fract--	Fractured cusp, gross decay on 18
8/4/2015	19	broke--	my tooth broke pt points to #19.
8/4/2015	19	fract--	Diagnosis Fractured ML and DL cusps #19

Date	Tooth	Key-No-Yes	phrase
8/4/2015	19	fract--	The tooth that had given the patient pain last night was #19 which had fractured ML and DL cusps and pulp was exposed.
8/4/2015	19	fract--	ML and DL cusps fractured and pulp exposure #19
8/4/2015	19	fract--	#19 has been fractured for roughly 2 years and only occasionally symptomatic, pulp exposed
8/4/2015	2	broke--	tooth #2 broke while eating 3 months ago
8/4/2015	20	fract--horizontal	#20 horizontal crown fracture with post and bridge attached.
8/4/2015	20	fract--horizontal	#20 Horizontal crown fracture held in place by a post.
8/4/2015	3	fract--	Fractured tooth non-restorable #3
8/4/2015	30	fract--	DE: Dr: Buccal portion of #14 fractured, #30 remains severely fractured, please evaluate both teeth for restorative or replacement, #3 DF decay
8/4/2015	30	broke--	Pt also has severely broken down crown on #30.
8/4/2015	30	broke--	#30 is broken off at gingival.
8/4/2015	30	fract--	#30 was crowned but fractured and then decayed
8/4/2015	31	broke--	Grossly carious and broken down #12 and 31.
8/4/2015	31	broke--	#12 and 31 are broken down carious.
8/4/2015	5	fract--vertical	#5, fractured crown off, caries, root exposure, vertical defect, #24,25, vertical defect, root exposure.
8/4/2015	5	crack--	#5, 1.5 weeks ago, bit into a cracker and it started hurting.
8/5/2015	13	fract--	Fractured and painful #13
8/5/2015	13	fract--	26 Yo M w/ fractured #13 and pain

Date	Tooth	Key-No-Yes	phrase
8/5/2015	13	fract--	Fractured #13
8/5/2015	21	fract--	teeth 21 and 27 fractured 1 month ago
8/5/2015	21	fract--	fractured 21 and 27
8/5/2015	21	fract--	fractured #21 and 27
8/6/2015	18	fract--	Buccal Cusp Fracture #18
8/7/2015	14	fract--	Gross decay to pulp from fracture of #14
8/7/2015	14	fract--	#14 fractured and pain has been present around 2-3 months.
8/7/2015	14	fract-elevat-	Fractured crown tooth #14 with elevator.
8/10/2015	18	split--	Split thickness incision into mucosa to laterally position mucosal tissue away from buccal surface of #18 and to extend vestibular fornix.
8/10/2015	18	split--	Split thickness flap has healed very well and has allowed significantly better cleansability in the area buccal of #18.
8/10/2015	18	split--	Split thickness incision into mucosa to laterally position mucosal tissue away from buccal surface of #18 and to extend vestibular fornix.
8/10/2015	18	fract--	#18 clinical crown fracture
8/10/2015	29	broke--	#29 Broken off crown close to the gum line.
8/11/2015	15	fract--	Fractured #2, 15, and displaced #4
8/11/2015	15	fract--	fractured #1, 2, 4, 15 with PAP
8/11/2015	15	fract--root	Tooth#1 severely decayed, #2 and 15 show larged cusp fractures and symptomatic apical periodontitis, #4 is retained root- all non restorable
8/11/2015	15	fract--	#15-MOB fracture and gross decay

Date	Tooth	Key-No-Yes	phrase
8/11/2015	29	fract--root	#29 Non-restorable: vert root fracture
8/11/2015	29	fract--vertical	#29 vertical root fracture on distolingual.
8/11/2015	3	fract--	O: BP: 136/92, Pulse: 56, small fracture on buccal of #3PFM, generalized calculus, slight inflammation around gingival margins, see axium
8/11/2015	4	fract--	Fractured #2, 15, and displaced #4
8/11/2015	4	fract--	fractured #1, 2, 4, 15 with PAP
8/11/2015	4	fract--root	Tooth#1 severely decayed, #2 and 15 show larged cusp fractures and symptomatic apical periodontitis, #4 is retained root- all non restorable
8/12/2015	20	fract--	#20 occlusal wear and D fracture
8/12/2015	20	fract--	Fractured #4,15,18,20,29
8/12/2015	20	fract--	Asymptomatic Fractured #15,20,29
8/12/2015	30	fract--	#30 - fractured
8/12/2015	30	fract--	#30 non restorable with buccal fracture and fistula.
8/12/2015	30	fract-forcep-	Attempted forceps ext and fractured crown #30.
8/13/2015	12	fract--	clinical crwon fracture #12
8/13/2015	12	fract--	#12 fractured around 6-7 months ago.
8/14/2015	18	fract--	#18 Fractured clinical crown, gross decay
8/14/2015	18	fract--	#18 RL, fractured coronal structure
8/14/2015	18	fract--	#18 Fractured clinical crown
8/14/2015	18	fract--	fractured crown #18
8/14/2015	3	fract--	fractured #3
8/17/2015	12	fract--	fractured, non-restorable #12- ext/SoD

Date	Tooth	Key-No-Yes	phrase
8/17/2015	12	fract--	fractured, non-restorable #12
8/17/2015	15	fract--	fractured and decayed #15, non restorable
8/17/2015	15	fract--	Gross decay and fractured #15, left maxillary sinus more opaque than R
8/17/2015	15	fract--	#15 fracture and has gross decay
8/17/2015	18	fract--	#18- fractured class I silver amalgam with large mesial decay - tender on percussion, slightly mobile
8/17/2015	18	fract-amalgam-	#18- fractured class I silver amalgam with large mesial decay- tender on percussion, slightly mobile.
8/17/2015	29	fract--	Fractured cusp and gross decay on #29
8/17/2015	29	fract--	tooth #29 fractured cusp and gross decay
8/17/2015	29	fract--	#29 cuspal fracture
8/17/2015	3	fract--	Dental: Fractured tooth #3: symptomatic apical periodontitis
8/17/2015	3	fract--	A: fractured crown on #3
8/17/2015	3	fract--	Dental:#3 fractured crown non restorable
8/17/2015	3	broke--	#3 broken crown
8/17/2015	4	broke--	#4 -- badly broken down.
8/18/2015	29	fract--	A: Tooth and crown on #29 were completely fractured off.
8/18/2015	29	fract--	#29 is the distal abutment tooth for patient Mandibular RPD and patient can no longer wear RPD because of the tooth/crown fracture.
8/18/2015	29	fract--	#29 fractured
8/18/2015	3	fract--	3 days prior, tooth fractured .

Date	Tooth	Key-No-Yes	phrase
8/18/2015	3	fract--	gross decay tooth #3 fractured crown, tenderness to palpation and percussion.
8/18/2015	4	fract--	Tooth (#4) fractured two months prior and started hurting 2 weeks ago.
8/18/2015	4	fract--	#4 D fracture and carious cavitation
8/19/2015	14	fract--	Tooth #14-D fractured off.
8/19/2015	14	fract--	#14 - fractured restoration on D w/ recurrent decay
8/19/2015	14	fract-amalgam-	PhD amalgam, contoured, checked interproximal contact, no interproximal contact established due to fractured DMR on #14, finished with a bur.
8/19/2015	14	fract-amalgam-	A: #14 - D fractured amalgam, recurrent caries under D margin
8/19/2015	14	fract--	S: PPTC with fractured crown #14.
8/19/2015	14	fract--root	- #14 fractured to gumline w/ retained roots
8/19/2015	14	broke--	Patient reports that #14 (previously RCT'ed) crown broke off ~3 mos ago and he is now experiencing pain.
8/19/2015	14	fract--root	#14 fractured to gumline (retained roots)
8/19/2015	14	fract--	#14 tooth fractured, caries (RCT, post and core treated)
8/19/2015	14	fract--	Dental- Caries #14, tooth fracture
8/19/2015	2	fract--	#2 caries and fractured restoration, sensitive to palpation and percussion
8/19/2015	29	fract--	Fractured restoration #29
8/19/2015	29	fract--	#29 distal recurrent caries, fractured restoration
8/19/2015	29	fract--	#29 fractured, tender on percussion

Date	Tooth	Key-No-Yes	phrase
8/19/2015	29	fract--	-#29 fractured crown with periapical radiolucency
8/19/2015	29	fract--	-#29 fractured crown, non restorable
8/19/2015	29	fract--	#29 fractured with vestibular abscess
8/19/2015	3	fract--	#3 grossly carious and fractured
8/20/2015	13	fract--	Since her last visit #13 crown was fractured.
8/20/2015	13	fract--	A: Fractured #13 crown.
8/20/2015	13	fract--	A: fractured #13 (part of abutment for FP) decay present on the margin
8/20/2015	13	fract--	Extraoral/Intraoral soft tissue examination: #13 crown fractured that was part of bridge: not enough ferrule effect.
8/20/2015	13	fract--	also reviewed #13 fracture crown.
8/20/2015	13	fract--	Fractured tooth #13
8/20/2015	13	fract--	A: fractured crown #13 w/ previously txed RCT
8/20/2015	5	fract--	#5 fractured and symptomatic
8/21/2015	12	fract--	#3, #12-16, and #28-30 fractured crowns.
8/21/2015	21	fract--	Fractured #21
8/21/2015	28	fract--	#3, #12-16, and #28-30 fractured crowns.
8/21/2015	3	fract--	#3, #12-16, and #28-30 fractured crowns.
8/21/2015	30	fract--	#3, #12-16, and #28-30 fractured crowns.
8/24/2015	12	broke--	#7,9,12 have been broken for over a year now
8/24/2015	30	fract--	Distal fracture on tooth #30, not associated w/ swelling and active drainage.
8/24/2015	5	fract--	Decay #19,21,28 Fractured #5, missing crown #15,29,18

Date	Tooth	Key-No-Yes	phrase
8/24/2015	5	fract--	Fractured #5,18 crown missing from both.
8/25/2015	29	fract--	#29 fractured tooth, no pain involved with it.
8/25/2015	29	fract--	Fractured #29, apical radiolucency.
8/25/2015	29	fract--	Dental: fractured #29, nonrestorable, generalized plaque and calculus.
8/25/2015	29	fract--	A slight pain in lower right tooth #29, fractured off a couple of weeks ago, no swelling involved.
8/25/2015	30	fract--	Fractured and carious #30
8/25/2015	4	fract--	gross decay and fractured crown on #4
8/26/2015	14	fract--	Clinical exam reveals #14 crown prep with fractured restoration and fistula on adjacent buccal gingival.
8/26/2015	14	fract--	parulis on buccal ging over #14 (fractured restoration)
8/26/2015	14	fract--	Sharp edge of fractured #14 smoothed for Pt Pt left satisfied and ambulatory.
8/26/2015	14	fract--	#14 - fractured, caries, non-restorable (PA taken and shows PAP) discussed indication for extraction with pt and offered to extract the tooth today.
8/26/2015	2	fract--	- Grossly carious/fractured #s 15, 20,
8/26/2015	29	fract--	#29 fractured to gingival, carious
8/26/2015	29	fract--	- Grossly carious/fractured #s 15, 18, 20, 29, 30
8/26/2015	29	fract--	generalized decay, generalized calculus/plaque, fractured 29 where patient report pain is coming from.
8/26/2015	29	fract--	Dental: Fractured 29, generalized decay, generalized calculus/plaque

Date	Tooth	Key-No-Yes	phrase
8/26/2015	30	fract--	- Grossly carious/fractured #s 15, 18, 20, 29, 30
8/26/2015	30	fract--	Caries/fracture on the mesial of #30.
8/26/2015	30	fract--	Fractured #30
8/26/2015	4	broke--	A: #24 is broken
8/26/2015	5	fract--	- Grossly carious/fractured #s 15, 18, 20, 29, 30
8/26/2015	5	fract--	- Grossly carious/fractured #s 15, 20,
8/27/2015	18	fract--	#18 fractured to pulp with recurrent decay, PARL approx 15 x 10 mm
8/27/2015	18	fract--	#18 fractured and carious tooth with PARL
8/27/2015	18	fract--	#18 fractured, decayed with PARL
8/28/2015	15	fract--	Fractured Cusp #15
8/28/2015	15	fract--	#15 Fractured L cusps and pos percussion sensi
8/28/2015	15	fract--	#15 Fractured L cusps w/ extensive decay radiographically
8/28/2015	4	fract--	#4 fractured and gross decay
8/31/2015	18	fract--	Previous RCT on #18, crown is fractured and tooth is not restorable.
8/31/2015	18	fract--	#18 distolingual cusp fractured, gross caries
8/31/2015	2	fract--	#1,2 fractured, carious, tender on percussion
8/31/2015	28	broke--	#28 broken tooth, no restorable
8/31/2015	28	broke--	#28 broken crown
8/31/2015	28	broke--	#28 crown broken/ not restorable
8/31/2015	28	broke--	#28 broken crown/ caries/ no restorable
9/1/2015	14	fract--	Tooth #2 and 14 fractured about 1 month ago.
9/1/2015	2	fract--	Tooth #2 and 14 fractured about 1 month ago.

Date	Tooth	Key-No-Yes	phrase
9/1/2015	3	fract--	O: BP - 143/95, Pulse 69, acrylic temporary in place, no fractures, distal post space prepared by grad endo
9/1/2015	3	fract-amalgam-	O: BP 136/93, Pulse 74, IOE - #21 - existing DO amalgam w/ fractured enamel along DL, open contact between #21 and 20.
9/1/2015	3	fract--vertical	ntal diagnosis: localized severe chronic perio with generalized mild chronic, suspected vertical root fracture mesial 3
9/1/2015	3	fract--vertical	A: #3 possible vertical root fracture as determined by grad perio.
9/1/2015	3	fract--vertical	P: Discussed possibility of #3 having a vertical root fracture and being extracted in graduate perio.
9/1/2015	3	fract--	Slight abfraction noted on teeth 5,6, 12, 13, 20, 21, 28, 29.
9/1/2015	3	broke--	alking to the Pt about the long-term risks, and benefits of whether to treat the carious lesion on #30D or to keep monitoring it, it was decided that keeping an eye on that lesion during recalls would
9/1/2015	3	fract--root	Moreover #3 had bony defect at the MB root, and possibility of it having a root fracture was discussed with the patient.
9/1/2015	3	fract--	Tooth #3 MOB fracture will decide after radiographs if able to save or needs to be Ext.
9/1/2015	30	fract--	#30 D Gross caries and fractured cusp.
9/1/2015	30	fract--	#30 D Gross caries and fractured cusp
9/1/2015	30	fract--	Gross caries and fracture on #30
9/1/2015	31	fract--	#31 gross caries, fractured

Date	Tooth	Key-No-Yes	phrase
9/1/2015	31	fract--	#31 fractured buccal cusps with caries
9/1/2015	31	fract--	#31 fractured with gross caries
9/1/2015	5	broke--	#5 has broken off further on 7/17
9/1/2015	5	fract--	#5 fractured cusp
9/2/2015	18	fract--	#18 fractured tooth and grossly carious
9/2/2015	19	broke--	#19 broken tooth
9/2/2015	19	broke--	#19 broken tooth with buccal gingival sinus.
9/2/2015	21	fract--	#19, 21-decayed and fractured
9/2/2015	3	broke--	A: #3 broken on lingual to tissue.
9/2/2015	3	fract--	Consultation * Diagnoses Fractured crown on #3
9/2/2015	3	broke--	Additional Narrative PPTC for evaluation of tooth #3; patient was in a car accident on March 21, 2015 and broke the crown off of the tooth.
9/2/2015	3	fract--	Fractured #3
9/2/2015	3	fract--	Dental: Fractured #3
9/2/2015	5	broke--	Pt present with ref frm her dentist and sch herself for eval of #5 which was previously RC and is now broken.
9/2/2015	5	fract--	70 yo F with PMhx of controlled HTN and DM (HgA1C=7.9) present to clinic with fractured and non restorable RCT #5
9/2/2015	5	fract--horizontal	RTC #5 with horizontal fracture of the crown at CEJ
9/2/2015	5	fract--	Fracture crown #5 with class III mobility of crown attached to palatal soft tissues only.
9/3/2015	18	fract--	#18 has gross caries and an occlusal fracture.

Date	Tooth	Key-No-Yes	phrase
9/3/2015	19	fract--	Fractured #19 M-D
9/3/2015	2	fract--	Diagnosis #2 fractured restoration
9/3/2015	2	fract--	PPTC on 7/9/15 due to #2 fractured restoration.
9/3/2015	3	fract--	Large MO filling on #3 has fractured and fallen out, significant caries.
9/3/2015	5	fract--	#5 grossly carious with large fracture
9/3/2015	5	fract--	#5 fractured and grossly carious
9/3/2015	5	fract--	gross caries and large fracture on #5
9/8/2015	20	fract--	#20 fractured crown.
9/8/2015	28	broke-denture-	itted to her insurance.Tx Plan is as follows:1- Making impressions of upper arch where she had many broken teeth, many of them mobile.2- Having an immediate upper complete denture to be fabricated.3-T
9/8/2015	28	fract--	Fractured non restorable teeth 1, 11, 12, 13, 15, 20, 21, 28, 29.
9/8/2015	30	fract--	fracture and PA RA around #30
9/8/2015	30	fract--	Decay and fractured tooth #30
9/8/2015	30	fract--	Dental: Decay and fractured #30 - PAP
9/8/2015	31	fract-elevat-	NOTE: Upon luxation/elevation of #31, distal crown of carious #30 fractured/crumbled off in pieces.
9/8/2015	31	fract--	Fractured crowns on 18,18,20, 30,31
9/8/2015	4	fract--	Fractured restoration on 29 and radiographic decay on 29 14 and 13.
9/8/2015	4	fract--	S: CC: UR tooth fractured (points #4)

Date	Tooth	Key-No-Yes	phrase
9/8/2015	4	fract--	Clinical presentation - #4 fractured to gingival line, w/ caries
9/8/2015	5	crack--	Illicit drugs stopped using 5 years ago (crack cocaine)
9/9/2015	21	fract--	Pain around area of #21-22, where #22 fractured off about two months ago.
9/9/2015	21	broke--	Grossly carious and broken down #'s 5,6,8,9,10,11,21,22,23,26,27,28.
9/9/2015	21	broke--	Grossly carious and broken down #'s 5,6,8,9,10,11,21,22,23,26,27,28
9/9/2015	28	broke--	Grossly carious and broken down #'s 5,6,8,9,10,11,21,22,23,26,27,28.
9/9/2015	28	broke--	Grossly carious and broken down #'s 5,6,8,9,10,11,21,22,23,26,27,28
9/9/2015	3	fract--	#3 fractured a year ago.
9/9/2015	30	broke--	S: Patient self-referred with C.C.: My tooth on the lower right broke 20 years ago (#30) and has not hurt for many.
9/10/2015	12	fract--	Fractured and carious 2, 3, 4,5, 12, 13, 16, 31, 32.
9/10/2015	12	fract--vertical	#12 vertical fracture and class 3 mobility
9/10/2015	13	broke-amalgam-	Removed broken down area of #13 MOD amalgam on mesial only.
9/10/2015	13	fract--	Hard tissue exam (Findings) Dr - caries found on 28D, 13D, 21D, 2DB, 19B, overhang #29D, fracture line on 5D
9/10/2015	13	fract--	S: PPTC with fractured #31 and #13
9/10/2015	13	broke--	Additonal Narrative PPTC for broken filling #13.

Date	Tooth	Key-No-Yes	phrase
9/10/2015	13	fract--	Clinical Exam: #13 - large restoration, remaining tooth structure fractured off.
9/10/2015	13	fract--	#13 fractured, #19 infection/caries
9/10/2015	13	fract--	Fractured and carious 2, 3, 4,5, 12, 13, 16, 31, 32.
9/10/2015	14	fract--	Fractured #14
9/10/2015	14	fract--	#14 fractured, sensitivity to percussion.
9/10/2015	14	fract--	PARL #14 and fractured crown
9/10/2015	19	fract--	A: #19ML has fractured.
9/10/2015	19	fract--	Hard tissue exam (Findings) Dr - caries found on 28D, 13D, 21D, 2DB, 19B, overhang #29D, fracture line on 5D
9/10/2015	19	fract--	#13 fractured, #19 infection/caries
9/10/2015	2	fract--	Fractured and carious 2, 3, 4,5, 12, 13, 16, 31, 32.
9/10/2015	31	fract--	Fractured and carious 2, 3, 4,5, 12, 13, 16, 31, 32.
9/10/2015	4	fract--	Fractured and carious 2, 3, 4,5, 12, 13, 16, 31, 32.
9/10/2015	5	fract--	Fractured and carious 2, 3, 4,5, 12, 13, 16, 31, 32.
9/11/2015	30	fract--	#30- fractured Mesio-distally
9/11/2015	30	fract--	-#30 previously endo treated, fractured crown mesial distally w/ tenderness to palpation and percussion.
9/11/2015	30	fract--	Discussed wiht pt about possibility of fracture of #31 during extraction of #30 along with other risks associated with extractions.
9/11/2015	30	fract--	fractured #30, restorable,pt elects ext
9/11/2015	4	fract--vertical	#4- vertical fracture to bone.
9/11/2015	4	fract--vertical	#4 vertical fracture non-restorable

Date	Tooth	Key-No-Yes	phrase
9/11/2015	4	crack--	One week ago #4 cracked.
9/11/2015	4	fract--root	#8: Fracture eliss: 4/through root
9/14/2015	12	fract--root	Crown fracture #12, root tip retained.
9/14/2015	12	fract--root	Crown fracture and root tip retained #12
9/14/2015	12	fract--root	Fracture crown, root tip retained #12
9/14/2015	18	broke--	#18 Grossly broken down
9/14/2015	2	fract--	#2 fractured
9/14/2015	3	fract--	Grossly carious #s 3 (fractured), 4 (fractured), 5, 6
9/14/2015	3	fract--root	Fractured (retained root) #13
9/14/2015	3	fract--	Grossly carious #s 3 (fractured), 4 (fractured), 5, 6 (with temporary filling in place).
9/14/2015	30	fract--	Gross decay/fracture #30
9/14/2015	30	fract--	Fractured #30, 31
9/14/2015	4	fract--	Grossly carious #s 3 (fractured), 4 (fractured), 5, 6
9/14/2015	4	fract--	Grossly carious #s 3 (fractured), 4 (fractured), 5, 6 (with temporary filling in place).
9/14/2015	4	broke--	#4 broken crown
9/14/2015	5	fract--	Grossly carious #s 3 (fractured), 4 (fractured), 5, 6
9/14/2015	5	fract--	Grossly carious #s 3 (fractured), 4 (fractured), 5, 6 (with temporary filling in place).
9/15/2015	13	fract--	Lingual cusp fracture #13.
9/15/2015	13	fract--	fracture #13.

Date	Tooth	Key-No-Yes	phrase
9/15/2015	15	fract--root	- Grossly fractured to gumline (retained roots): #s 3-11, 15
9/15/2015	15	fract--	Grossly carious/fractured #s 3-11, 15
9/16/2015	18	fract--vertical	They found a vertical root fracture on Distal root of #18 and deemed non-restorable.
9/16/2015	19	broke--	#19 Tooth broke over a year ago.
9/16/2015	20	fract--vertical	#20 vertical and horizontal crown fracture
9/16/2015	20	fract--horizontal	#20 vertical/horizontal crown fracture
9/16/2015	20	fract--horizontal	#20 horizontal RL line through crown (fracture)
9/16/2015	20	fract--vertical	Vertical crown fracture #20
9/16/2015	3	fract--root	#3 fractured with crown and roots 1/3 apically.
9/17/2015	18	fract--	#18 w/ fractured filling and cusp on lingual side.
9/17/2015	2	broke--	S: Patient self-referred with C.C.: My tooth on the lower right broke 20 years ago (#30) and has not hurt for many.
9/17/2015	3	broke--	S: Patient self-referred with C.C.: My tooth on the lower right broke 20 years ago (#30) and has not hurt for many.
9/17/2015	30	fract--	fractured crown #30 and #19
9/17/2015	31	crack--	A: Pt has a cracked tooth on #31.
9/18/2015	12	fract--root	#12: fracture crown, retained root tip
9/28/2015	15	fract--	#15 - Gross Decay, Fractured mesial marginal ridge
9/28/2015	3	fract--	Gross caries #3, Fracture buccal cusp #12
9/28/2015	5	broke--	Pt was brought to OS clinic after dental student attempted to ext #5 and broke crown off
9/28/2015	5	fx--	clinical exam showed #5 fx at bone level

Date	Tooth	Key-No-Yes	phrase
9/29/2015	30	fract--	#30 fractured at the level of the gingiva.
9/29/2015	30	fract--	Fractured #30 at the gumline
9/29/2015	4	fx--	#14 fx crown, gross caries- nonrestorable
9/30/2015	14	fract--	#14 fractured
9/30/2015	14	fract--	PRL #14 + fractured crown
9/30/2015	14	fract--	#14 - fractured crown
9/30/2015	14	fract--root	#14 has DL fracture with PAP on mesial root(s).
9/30/2015	14	fract--	Hard tissue exam Fractured #1, 14
10/1/2015	19	fract-porcelain-	#19- crown with failing margins and fractured porcelain
10/1/2015	3	broke--	#3 broke about 4-5 months ago, sinus tract present.
10/1/2015	30	broke--	Dental: broken #30
10/1/2015	30	broke--	Broken #30 - in half through facial and lingual
10/2/2015	19	fract--root	Fractured root #20 /PAP #19,20,21
10/2/2015	19	fx--	#19,20,21,26 PAP wtih #20 fx at middle third
10/2/2015	19	fract--	Fractured #19 missing crown #2
10/2/2015	19	fract--	RL on max anterior #22, and fractured #2 and #19
10/2/2015	2	fract--	Fractured #19 missing crown #2
10/2/2015	2	broke--	Surgery for broken wrist and dislocated elbow June/July 2014
10/2/2015	20	fract--root	Fractured root #20 /PAP #19,20,21
10/2/2015	20	fx--	#19,20,21,26 PAP wtih #20 fx at middle third
10/2/2015	20	fract--root	fractured root #20

Date	Tooth	Key-No-Yes	phrase
10/2/2015	21	fract--root	Fractured root #20 /PAP #19,20,21
10/2/2015	21	fx--	#19,20,21,26 PAP with #20 fx at middle third
10/2/2015	5	broke--	A: multiple broken down teeth, missing #8 and #25.
10/5/2015	15	fract--	Cariou fractured 15.
10/5/2015	2	fract--root	Informed patient about #2 root tips, and fractured #4.
10/5/2015	29	fract--	#29, 30 fractured teeth
10/5/2015	3	fract-amalgam-	Fractured amalgam #3
10/5/2015	3	fract-amalgam-	Dental: #3 fractured amalgam
10/5/2015	3	fract-amalgam-	#3 fractured amalgam
10/5/2015	30	fract--	47y/o female present forextraction of fractured and non restorable #1,16,17,18,30,32.
10/5/2015	30	fract--	#29, 30 fractured teeth
10/5/2015	4	fract--root	Informed patient about #2 root tips, and fractured #4.
10/6/2015	14	fract--	#14, 15, 29 - Non-restorable (fractured)
10/6/2015	14	fract--	#14, 28, 29 - Non-restorable (fractured)
10/6/2015	18	fract--	fractured crown of #18
10/6/2015	18	fract--	fractured crown #18
10/6/2015	2	broke--	Pt states #2 broke a few days ago and has been a 10/10 pain since then.
10/6/2015	20	fract--	A: Pt has fractured teeth #5, 20, 21, 30.
10/6/2015	20	fract--	Fractured #5, 20, 21, 30
10/6/2015	20	fract--	Fractured #5, 20, 21, 30.

Date	Tooth	Key-No-Yes	phrase
10/6/2015	20	fract--	Fecal Transplant 8/2015 for refractory C.
10/6/2015	21	fract--	A: Pt has fractured teeth #5, 20, 21, 30.
10/6/2015	21	fract--	Fractured #5, 20, 21, 30
10/6/2015	21	fract--	Fractured #5, 20, 21, 30.
10/6/2015	29	fract--	#14, 15, 29 - Non-restorable (fractured)
10/6/2015	29	fract--	#14, 28, 29 - Non-restorable (fractured)
10/6/2015	3	fract--	fractured and carious #30, periodontally involved
10/6/2015	30	fract--	fractured and carious #30, periodontally involved
10/6/2015	30	fract--	Fractured #30 Necrotic Pulp
10/6/2015	30	broke--	#30 Broken crown w/ Chronic Apical Abscess, Necrotic Pulp
10/6/2015	30	fract--	A: Pt has fractured teeth #5, 20, 21, 30.
10/6/2015	30	fract--	Fractured #5, 20, 21, 30
10/6/2015	30	fract--	Fractured #5, 20, 21, 30.
10/6/2015	5	fract--	Clinical evaluation showed #5 fractured through the central groove with parulis present on buccal gingiva between #4 and #5.
10/6/2015	5	fract--	A: Pt has fractured teeth #5, 20, 21, 30.
10/6/2015	5	fract--	Fractured #5, 20, 21, 30
10/6/2015	5	fract--	Fractured #5, 20, 21, 30.
10/6/2015	5	fract--	Fecal Transplant 8/2015 for refractory C.
10/7/2015	18	crack--	Significant dental findings:dry cracked lip, sensitive, generalized heavy calculus, gross decay #1 and #18, generalzed bleeding and 4-7 probing depths, generalized class 1 mobility

Date	Tooth	Key-No-Yes	phrase
10/7/2015	18	crack--	Significant dental findings: gross decay #1,18, dry cracked lip, generalized heavy calculus and BOP with 4-7mm PDs, generalized class I mobility
10/7/2015	19	fract--	#19 - DB Fractured
10/7/2015	3	fract--	#3-ML fracture
10/7/2015	3	fract--	10/13- Fractured cusp
10/7/2015	3	crack--	36 yo healthy male presents c/o a cracked tooth on the upper right.
10/8/2015	18	fract--	#18 crown grossly fractured.
10/8/2015	18	fract--	Fractured/non-restorable tooth #18
10/8/2015	2	fract--	#2 presents fractured below gumline.
10/8/2015	3	fract--	Decayed, fractured #3 and 4
10/8/2015	3	fract--	Fractured bridge/canteliver on #3
10/8/2015	4	fract--	Decayed, fractured #3 and 4
10/9/2015	12	fract--	#12 fractured L cusp
10/9/2015	13	broke--	Two ankles broken December 2013 - no complications
10/9/2015	13	broke--	Two ankles broken December 2013 - no complications
10/12/2015	19	fract--	#19 - tooth fracture
10/13/2015	12	fract--	Fractured #12
10/13/2015	12	fract--	Fractured #12 (non-restorable per patient's student dentist)
10/13/2015	13	fract--root	Fractured (retained root) #13
10/13/2015	3	fract--	HPI: Pt reports tooth #3 fractured approx 4 months ago and has become symptomatic.

Date	Tooth	Key-No-Yes	phrase
10/13/2015	3	fract-amalgam-	Dental History #3 MO amalgam, fractured MB and DB cusps
10/13/2015	3	fract--	Clinical Exam: #3 fractured buccal cusps with pressure and cold sensitivity
10/13/2015	3	fract--	Radiograph Findings #3 fractured tooth with abfraction lesion, no periapical pathology evident
10/14/2015	13	broke-porcelain-	P: Pt states the porcelain on the front surface of the crown on #13 broke off last week.
10/14/2015	13	fract--	watch abfraction lesions on B of #12-13
10/14/2015	13	broke--	Also, crown on tooth #13 has broken off, and is non-restorable.
10/14/2015	19	fx--	#19 fx.
10/14/2015	19	fx--	#19 crown fx.
10/14/2015	2	fract--	Gross fracture of #7, 19, 20
10/14/2015	2	fract--	Gross coronal fracture of #7, 19, 20
10/14/2015	2	fract--	Gross coronal fracture of #7, 19, 20 - non-restorable
10/14/2015	2	broke--	broken teeth #7, 19, 20
10/14/2015	2	broke--	2 teeth broke while pt was at the dentist.
10/14/2015	30	fract--	#30 fractured distal lingual cusp, caries, symptomatic apical periodontitis
10/14/2015	30	fract--	#30 fracture distal lingual cusp, symptomatic palpation on lingual and percussion
10/14/2015	30	crack--	Patient cracked/fractured distal lingual cusp #30 about 3.5 months ago.
10/15/2015	15	fract-partial-	A portion of the buccal plate adjacent to tooth #15 was fractured during the extraction; however, it was only partially fractured and

Date	Tooth	Key-No-Yes	phrase
10/15/2015	19	fract--	#19 Fractured crown
10/15/2015	19	fract--	#19 fractured crown, widened PDL
10/15/2015	3	fract--	Intra oral: #9- Extruded 2-XXX, DL caries, #10- fractured till CEJ, #19, 30-PFM crown, open crown margins in #30.
10/15/2015	3	fract--	Carious/fractured 3, 5, 6.
10/15/2015	3	fract--	Fractured teeth 3, 5.
10/15/2015	31	fract--	#31 has a cusp fracture and according to Dr Aaron needs endo to save or extract and replace with implant.
10/15/2015	31	fract--	#31-M, D caries, fractured MB cusp with secondary caries, furcation involvement
10/15/2015	4	fract--	#4 fractured with NRC
10/15/2015	4	fract--	#4 gross caries, some fractured pieces
10/15/2015	4	fract--	NRC and fracture #1 and #4
10/15/2015	5	fract--	Carious/fractured 3, 5, 6.
10/15/2015	5	fract--	Fractured teeth 3, 5.
10/16/2015	13	fract--	#13 fractured off.
10/16/2015	18	fract--	fractured crown #27, 26, 22, 19, 18 ,17
10/16/2015	19	fract--	fractured crown #27, 26, 22, 19, 18 ,17
10/16/2015	30	broke--	The crown of #30 broke off during the procedure handpiece was used to reduce the interdenta
10/16/2015	31	split--	Split tooth #31
10/16/2015	31	split--	split tooth #31
10/19/2015	18	fract--	#18 fractured in pt's sleep.
10/19/2015	18	fract--	#18 ML fracture

Date	Tooth	Key-No-Yes	phrase
10/19/2015	18	fract--	#18ML fracture, #31DL fracture
10/19/2015	18	broke--	Broken teeth #18 & 31
10/19/2015	20	broke--	plan to ext #20 and gain attachment on #18 after broken bridge is removed.
10/19/2015	3	fract--	recession, abfraction #3 - very sensitive to percussion
10/19/2015	3	fract--root	#14 Root tips, #3 recession and abfraction sensitive to percussion, #29 crown attrition with post
10/19/2015	31	fract--	#31 DL fractuer
10/19/2015	31	fract--	#18ML fracture, #31DL fracture
10/19/2015	31	broke--	Broken teeth #18 & 31
10/20/2015	13	fract--	#5, 13, 31 - Fractured teeth
10/20/2015	13	fract--	Fractured teeth #5, 13, 31
10/20/2015	18	fract-elevat-root	#18 elevated and cow-horn used to deliver tooth buccally(distal root delivered and mesial root fractured during use).
10/20/2015	18	fract--	#18 Clinical crown fracture and carious
10/20/2015	18	fract--	#18: Clinical crown fractured off (soft tissue/gingival overgrowth over fractured crown.
10/20/2015	18	fract--	#18: fractured clinical crown and grossly carious
10/20/2015	18	fract--	Dental findings: #18 fractured clinical crown with soft tissue/gingival overgrowth.
10/20/2015	19	fract--root	Fractured crown, retained roots #19 (previous NSRCT)
10/20/2015	19	fract--	Extensively decayed fractures status post-RCT #19, non-restorable.

Date	Tooth	Key-No-Yes	phrase
10/20/2015	19	broke--	Broken crown #19 (previous NSRCT)
10/20/2015	19	fract--	Fractured crown, SAP, status post-RCT#19
10/20/2015	3	broke--	33 YOM broke tooth #3 off while opening a beer bottle with his teeth.
10/20/2015	3	broke--	I Broke my tooth off #3
10/20/2015	31	fract--	#5, 13, 31 - Fractured teeth
10/20/2015	31	fract--	Fractured teeth #5, 13, 31
10/20/2015	31	fract--	Fractured DL cusp #31
10/20/2015	31	fract--	DL cusp fractured #31
10/20/2015	31	fract--	Fractured cusp #31
10/20/2015	5	fract--	#5, 13, 31 - Fractured teeth
10/20/2015	5	fract--	Fractured teeth #5, 13, 31
10/21/2015	12	broke--	42 y/o healthy patient with no previous medical history with broken crown #12
10/21/2015	12	broke--	Broken crown #5,12
10/21/2015	12	fract--	Abfraction #12
10/21/2015	13	fract--	Tooth #13 gross caries, fractured one week ago.
10/21/2015	13	broke--	#13 Gross caries with broken crown.
10/21/2015	20	fract--	Patient present with a big abfraction #20 that is painful.
10/21/2015	20	fract--	Large abfraction #20
10/21/2015	20	fract--	Dental: Large symptomatic abfraction #20
10/21/2015	20	broke--	gross decay and broken #20

Date	Tooth	Key-No-Yes	phrase
10/22/2015	18	fract--	O: BP 108/80 HR 72R Pt uses chewing tobacco, PSR 4,1,12,2,2, perio charting, fractured restoration 18-O
10/22/2015	18	fract--	Additonal Narrative pt PPTC with pain in lower left to chewing, determined fractured cusp with caries on #18D, restored to function
10/22/2015	19	fract-forcep-	Fractured crown #19 using forcep.
10/22/2015	19	fract--	#19 fracture on the distal.
10/22/2015	3	fract--root	A:#3 fractured, palatal root in clos
10/22/2015	3	fract--root	A:#3 fractured, palatal root in clos
10/23/2015	19	fract--root	Diagnosis: Generalized mild periodontitis #19 M PARL/root fracture Miller Class I recession #8, 9, 21, 28-30
10/23/2015	19	fract--vertical	Etiology: Bacterial biofilm/calculus #19 vertical root fracture/iatrogenic Thin biotype/toothbrush abrasion
10/23/2015	19	fract--root	Pt desires to replace #19 that has a root fracture on the mesial root with an implant.
10/23/2015	30	fract--root	root tip from fractured crown #30
10/26/2015	19	fract--	Dental: #19 MO Fracture with Periapical radiolucency
10/26/2015	19	fract--	#19: MO fracture, Periapical radiolucency
10/26/2015	19	fract--	#19 sensitive to percussion and palpation, fractured MO
10/26/2015	31	fract--	Fractured crown #31
10/27/2015	14	fract--root	- Retained/fractured roots #s 3, 6, 14, 16, 17, 31
10/27/2015	18	fract--	Crown #18 fractured further.
10/27/2015	18	fract--	#18 has a distal fracture.

Date	Tooth	Key-No-Yes	phrase
10/27/2015	18	fract--	#18 fractured on the distal.
10/27/2015	31	fract--root	- Retained/fractured roots #s 3, 6, 14, 16, 17, 31
10/28/2015	15	fract--	Pt reported at begining of appt a soreness on #15 "QUOTE" We checked pocket depths with nothing over 3mm and no tactile fractures, but noticed a Class III mobility.
10/28/2015	18	fract--	33 y/o male with no PMH, fractured non-restorable crowns #18,30.
10/28/2015	18	fract--	Fractured crown #18
10/28/2015	18	fract--	#18 fractured crown,gross decay
10/28/2015	30	fract--	Grossly carious #30 with large fractured area of crown.
10/28/2015	30	fract--	33 y/o male with no PMH, fractured non-restorable crowns #18,30.
10/28/2015	30	fract--	Fractured crown, gross decay #30
10/28/2015	30	fract--root	#30 fractured crown with retained roots
10/28/2015	31	fract-forcep-	Fractured crown of tooth #31 with forcep.
10/29/2015	20	fract--root	#20 - crown fractured off, only root remains
10/29/2015	3	fract--	gross decay/fractured #3
10/29/2015	3	fract--	fractured #3
10/29/2015	3	fract--	#3 fractured / gross caries - sensitive to percussion.
10/29/2015	30	fract--	#30 fractured enamel and caries.
10/29/2015	30	fract--	Pain comes from tooth #30 which has fractured enamel and caries present.
10/29/2015	30	crack--	30 had a large restoration that cracked a year ago and started producing symptoms.

Date	Tooth	Key-No-Yes	phrase
10/29/2015	30	fract--	Fractured MB and DB cusp #30 with pulp exposure.
10/29/2015	30	fract--	Fractured MB and DB cusp #30
10/29/2015	30	fract--	Buccal of tooth #30 fractured 2 days ago 1mm above the gum line.
10/29/2015	5	fract--vertical	tooth #5 RCT with crown, tooth has a vertical root fracture.
10/30/2015	15	fract--	A: Fractured DL cusp #15.
10/30/2015	30	fract--	S: PPTC for fractured #30
10/30/2015	30	crack--	tooth cracked 7/30 while eating a sandwich.
10/30/2015	30	fract--	#30 fractured crown
10/30/2015	30	fract--	#30 - fractured
11/2/2015	12	fract--	Fractured Crown #12, #13, #29
11/2/2015	13	fract--	Fractured Crown #12, #13, #29
11/2/2015	18	broke--	gross caries #18, broken tooth #21
11/2/2015	18	broke--	gross caries on #18, broken tooth#21
11/2/2015	18	fract--	47y/o female present forextraction of fractured and non restorable #1,16,17,18,30,32.
11/2/2015	18	fract--root	#18 crown fracture and cryer used to remove roots.
11/2/2015	18	fract--	Dental: Fractured crown #1, 18, 31
11/2/2015	18	fract--	fractured/missing crown on #1, 18, 31
11/2/2015	18	fract--	fractured crown #1, 18, 31.
11/2/2015	2	fract--	Fractured #30, Missing 1, 16, 17-19, 31-32.
11/2/2015	30	fract--	Gross decay #30, Traumatic fracture #14

Date	Tooth	Key-No-Yes	phrase
11/2/2015	30	crack--	cracked #30, missing crown, previous NSRCT
11/2/2015	31	crack--	Tooth #31 is cracked and has a poor prognosis endodontically and will need to be extracted.
11/2/2015	31	fract--	Dental: Fractured crown #1, 18, 31
11/2/2015	31	fract--	fractured/missing crown on #1, 18, 31
11/2/2015	31	fract--	fractured crown #1, 18, 31.
11/3/2015	18	fract--	28 yof Healthy Tooth #18 fractured 2 months ago, pain started 1 week ago
11/3/2015	18	fract--	Carious/non-restorable tooth #18 (fractured to osseous level)
11/3/2015	4	fract--	Fractured lingual cusp of #4
11/4/2015	13	broke--	Broken down carious #13
11/4/2015	13	fract--	Fractured off Lingual Cusp of #13
11/4/2015	14	fract-elevat-	Upon attempted elevator and forceps extraction of #14, crown fractured off.
11/4/2015	19	fract-forcep-root	Ext of 19, tooth crown fractured off, delivered crown with 151 forceps, delivered roots with crane pick.
11/4/2015	2	fract--	Fractured crown/restoration #2ML.
11/4/2015	29	fract--root	Root tip/fractured crown, #7, #10, #29
11/4/2015	4	fract-elevat-	Upon attempted elevator and forceps extraction of #14, crown fractured off.
11/5/2015	12	fract--	Fracture #12 buccal cusp
11/5/2015	12	fract--	Gross caries #3, Fracture buccal cusp #12
11/5/2015	12	fract--	#12- complicated crown fracture (includes pulp)
11/5/2015	12	fract--	Fracture #12

Date	Tooth	Key-No-Yes	phrase
11/5/2015	12	fract--	#12 complicated crown fracture
11/5/2015	12	fract--	#12, #13, #14 with gross decay, fractured crown, non-restorable
11/5/2015	12	fract--	dental: gross decay and fractured crown on 12, 13 and 14 with questionable resorability.
11/5/2015	12	fract--	Fractured crown on 12,13,14.
11/5/2015	13	fract--	#12, #13, #14 with gross decay, fractured crown, non-restorable
11/5/2015	13	fract--	dental: gross decay and fractured crown on 12, 13 and 14 with questionable resorability.
11/5/2015	13	fract--	Fractured crown on 12,13,14.
11/5/2015	14	fract--	#12, #13, #14 with gross decay, fractured crown, non-restorable
11/5/2015	14	fract--	dental: gross decay and fractured crown on 12, 13 and 14 with questionable resorability.
11/5/2015	14	fract--	Fractured crown on 12,13,14.
11/5/2015	14	fract--	#14 gross decay, fractured crown, non-restorable
11/5/2015	14	fract--	Dental: gross decay, fractured, non-restorable #14
11/5/2015	14	fract--	#14 caries, fractured, non-restorable
11/5/2015	18	broke--	Broken Crown #1, 2,16, 17, 18, 31, 32
11/5/2015	30	broke--	Dental: 3, 19, 30 broke and has severe caries
11/5/2015	30	fract--vertical	Vertical root fracture #30
11/6/2015	14	fract--	#14 gross-decay, fractured crown, non-restorable
11/6/2015	18	fract--	#18 decayed and fractured on lingual, sensitive to percussion
11/6/2015	18	broke--	Carious, broken #18

Date	Tooth	Key-No-Yes	phrase
11/6/2015	2	fract--	2013 Hand surgery to repair fracture
11/6/2015	2	fract--	#20 fractured and carious
11/6/2015	2	fract--	Tooth #2: distal fracture to bone and recurrent caries approximating pulp (endo diagnosis: symptomatic irreversible pulpitis with normal apical tissue)
11/6/2015	2	fract--	#2 gross decay and fracture
11/6/2015	4	fract--	#4 Non restorable/ fractured
11/6/2015	4	fract--	Tooth #4 crown fracture and non restorable
11/6/2015	5	fract--	Fractured #5
11/10/2015	15	broke--	#1,15,16 Gross Carious teeth, broken crowns.
11/10/2015	19	broke--	#19 crown broken off, gross caries.
11/10/2015	19	broke--	#19 Defective restoration, crown broken off.
11/10/2015	19	broke--	#19 Crown broken off, gross caries.
11/10/2015	30	broke--	Caries and broken #30 very tender to percussion.
11/10/2015	4	fract--vertical	4 vertical BWs were taken: Pt's bone levels were WNL, but every tooth had gross decay or fractured crown.
11/11/2015	19	broke--root	Dental: Broken down root tips #3, 19, 29
11/11/2015	19	broke--root	Broken down root tips #3, 19, 29
11/11/2015	19	broke--	1987- surgery for broken leg
11/11/2015	29	broke--root	Dental: Broken down root tips #3, 19, 29
11/11/2015	29	broke--root	Broken down root tips #3, 19, 29
11/11/2015	3	broke--root	Dental: Broken down root tips #3, 19, 29
11/11/2015	3	broke--root	Broken down root tips #3, 19, 29

Date	Tooth	Key-No-Yes	phrase
11/11/2015	30	broke--	Pt says #30 broke Dec 2014 and that it got an abscess in Feb 2015.
11/11/2015	5	fract--	Carious, fractured, non-restorable #5 extracted atraumatically.
11/12/2015	13	fract--vertical	Anterior open bite, #13 tooth with vertical fracture, pulp polyp and fistula around the apical area.
11/12/2015	15	fract--root	Fractured crown #15, RCT treated, root tips remaining
11/12/2015	15	fract--root	Pt fractured crown of #15 RCT treated, root tips remaining.
11/12/2015	21	broke--	multiple broken down teeth due to caries 5,6,7,8,9,10,11,12,13, 15, 21,22,23,24,25,26,27,28, 30
11/12/2015	28	broke--	multiple broken down teeth due to caries 5,6,7,8,9,10,11,12,13, 15, 21,22,23,24,25,26,27,28, 30
11/12/2015	29	fract--	#29 fractured lingual cusp
11/12/2015	29	fract--	#29 fractured DL crown
11/12/2015	29	fract--	#5 and 29 fractured carious teeth
11/12/2015	3	broke--	Findings: #3 broken down with caries, CBCT presented that site will need
11/12/2015	30	broke--	multiple broken down teeth due to caries 5,6,7,8,9,10,11,12,13, 15, 21,22,23,24,25,26,27,28, 30
11/12/2015	31	fract--	More of #31 fractured off.
11/12/2015	31	fract--	31-distal marginal ridge fractured off, L caries subging.
11/12/2015	31	fract--root	31- fractured restoration, L root caries

Date	Tooth	Key-No-Yes	phrase
11/12/2015	4	fract--	#14 has a fractured distal marginal ridge with recurrent decay
11/12/2015	4	broke--	#4,5 crown broke off 2-3 months ago.
11/12/2015	5	broke--	#4,5 crown broke off 2-3 months ago.
11/12/2015	5	fract--	Fractured #12 and fractured restoration #5
11/12/2015	5	fract--	Fractured restoration mesial #5
11/12/2015	5	fract-amalgam-	#5 fractured existing amalgam
11/12/2015	5	fract--	#5 fractured crown
11/12/2015	5	fract--	#5 and 29 fractured carious teeth
11/12/2015	5	fract--	A: Tooth 5 asymptomatic, fractured down to gumline.
11/13/2015	15	fract--	#15 gross caries and fractured, sensitive to percussion
11/13/2015	15	fract--	#15 Gross caries, fractured
11/13/2015	18	fract--	grossly carious, fractured #18 with periapical radiolucency, gross caries also teeth #14,16
11/13/2015	18	fract--	grossly carious, fractured #18 with associated buccal vestibular soft edema.
11/13/2015	19	broke--	gross decay, multiple broken down teeth 5-11,13,19-30.
11/13/2015	2	broke--	#2 - broken off crown.
11/13/2015	2	broke--	The crown of the tooth broke off 1 -2 months ago.
11/13/2015	3	fract--	#3 fractured, nonrestorable.
11/13/2015	3	broke--	#3 broken, mobile.

Date	Tooth	Key-No-Yes	phrase
11/13/2015	3	broke--root	Pt have broken teeth with retained root tips, pointed teeth #3,4,5,12,13, Pain on tooth#3 since yesterday.
11/13/2015	30	broke--	gross decay, multiple broken down teeth 5-11,13,19-30.
11/16/2015	12	fract--	Tooth 12 fractured
11/16/2015	12	fract--	tooth fracture of tooth 12,
11/16/2015	12	broke--	#12 has been broken down for a few months.
11/16/2015	12	fract--	Dental: Crown fracture on #12
11/16/2015	12	fract--	recurrent decay/ tooth fracture of 12
11/16/2015	13	fract--	Dental: Fractured #13, sensitive to percussion
11/16/2015	13	fract--	Fractured #13, decay under crown margin #14
11/16/2015	13	fract--	RL around crown of fractured #13
11/16/2015	13	fract--	Gross caries/fracture #13
11/16/2015	14	fract--	#14 - grossly decayed/fractured
11/16/2015	2	crack-amalgam-	HT- #2-D amalgam dislodged during localized scaling, #14 large DOL/MO composites, crack line on B, recommend crown, no caries noted on BW
11/16/2015	2	fract--	Fractured crown #2
11/16/2015	3	crack--	#3 cracked and non restorable
11/16/2015	3	fract--	#3 fractured and non-restorable
11/16/2015	3	crack--	My tooth cracked Pt points to #3
11/16/2015	30	fract-partial-	Crown #30 partially fractured
11/16/2015	31	fract--	grossly carious and fractured #31 with associated buccal swelling

Date	Tooth	Key-No-Yes	phrase
11/16/2015	31	broke--	PPTC with broken #31.
11/16/2015	31	crack--	Pt reports #31 breaking approx 2 days ago, but reports that tooth has been cracked for 1 month.
11/17/2015	13	fract--	Dental - #13 fractured at gumline.
11/17/2015	13	fract--	fractured tooth #13
11/17/2015	13	fract--	#13 fractured at gumline.
11/17/2015	13	fract--	#13 fractured - previous RCT tx
11/17/2015	18	broke--	Broken DL and DB cusps on both #18 and #31.
11/17/2015	18	broke--	Dental: Broken DL and DB cusps on both #18 and #31.
11/17/2015	18	fract--	Fractured tooth 18.
11/17/2015	30	fract--	tooth #30 fractured to osseous level.
11/17/2015	31	broke--	Broken DL and DB cusps on both #18 and #31.
11/17/2015	31	broke--	Dental: Broken DL and DB cusps on both #18 and #31.
11/18/2015	18	fract--	Dental History #18 ML cusp fractured off and has decay
11/18/2015	30	fract--	Fractured DB/DL cusps #30, space in location of missing #11, pt reports losing primary tooth 6mo ago
11/18/2015	30	fract--	fractured D cusp #30
11/18/2015	30	fract--	Fractured #30.
11/18/2015	31	broke--	cept for a 7mm nodular, corugated mass on the right tongue lateral side that is associated with the broken sharp tooth #31.
11/18/2015	31	fx--	Tooth #31 had a temp filling on it since 7/2015 and not sharp any more, and the lesion on the

Date	Tooth	Key-No-Yes	phrase
			tongue did not resolve, which was thought to be irritation from fx #31.
11/18/2015	31	fract--root	-->Tooth #31 decayed/ fractured to osseous level with associated PARL on the distal root
11/18/2015	31	fract--	Tooth #31 fractured/decayed to osseous level.
11/18/2015	5	broke--	57 yof presents today for evaluation of broken teeth for extraction, does not see general dentist.
11/18/2015	5	fx--	Tooth #31 had a temp filling on it since 7/2015 and not sharp any more, and the lesion on the tongue did not resolve, which was thought to be irritation from fx #31.
11/19/2015	21	fract-elevat-	#21 extracted with elevators and forceps, crown fractured and was converted to surgical extraction.
11/19/2015	3	fract--vertical	#3 vertical root fracture
11/20/2015	19	fract--	#19 Lingual wall fractured, held on by gingva.
11/20/2015	19	fract--	#19 caries to pulp with D crown fracture
11/20/2015	30	fract--	S:PPTC for emergency on #30 which had fractured.
11/20/2015	30	fract--	Pt had had #30 repaired multiple times, but it had fractured for the 3rd time now and just wanted it pulled
11/20/2015	30	fract--	A: #30-DO fracture, which was repairable and did not require an extraction.
11/20/2015	30	fract-amalgam-	A: #30-MODBL amalgam fractured on the distal.
11/20/2015	31	fract--vertical	#31 suspected vertical root fracture
11/20/2015	31	fract--root	Large RL associated w/ buccal root #31, most likely due to root fracture.

Date	Tooth	Key-No-Yes	phrase
11/23/2015	19	crack--	Pain started yesterday after tooth 19 was cracked then it turned into a big swelling.
11/23/2015	19	broke--	#19 broken cusps and PAP.
11/23/2015	19	broke--	#19 broken cusps and PAP
11/23/2015	19	fract--	19 fractured L cusps
11/24/2015	15	fract--	#15 D coronal fracture
11/24/2015	15	fract--vertical	Dental: Vertical root fracture on 15
11/24/2015	15	broke--	Dental: broken down and carious #2 and 15
11/24/2015	15	broke--	Broken down and decayed #2 and 15
11/24/2015	15	broke--	Broken down and carious #2 and 15
11/24/2015	20	fract--	When you presented on 3-20-12, the tooth #5 was fractured, and found to be non-restorable as you were informed.
11/24/2015	20	broke--	Pt called and stated that the crown came off of #20 and the tooth broke.
11/24/2015	20	fract--	Fractured distal surface #20.
11/24/2015	21	fract--	Grossly carious/fractured #21.
11/24/2015	21	fract--	Grossly carious and fractured #21.
11/24/2015	30	fract--	#30 fractured ML and MB cusp, +++ percussion, + palpation
11/25/2015	12	fract--	#12 & #13 fractured to gingiva, #14 grossly decayed.
11/25/2015	13	fract--	#13 had a crown that fractured and the tooth structured came with it.
11/25/2015	13	fract--	#12 & #13 fractured to gingiva, #14 grossly decayed.

Date	Tooth	Key-No-Yes	phrase
11/25/2015	14	fract--	#12 & #13 fractured to gingiva, #14 grossly decayed.
11/25/2015	19	broke--	Tooth broken since two weeks (tooth 19)
11/25/2015	2	broke--	and these 2 teeth are broken (patient points to #2,#3) and these teeth broke off completely (pt points to multiple mandibular anterior teeth)
11/25/2015	21	fract--	Fractured 2, 3, 21, 23, 25.
11/25/2015	21	fract--	Fractured carious 2, 3, 21, 23, 25.
11/25/2015	3	broke--	and these 2 teeth are broken (patient points to #2,#3) and these teeth broke off completely (pt points to multiple mandibular anterior teeth)
11/25/2015	3	fract--	Fractured 2, 3, 21, 23, 25.
11/25/2015	3	fract--	Fractured carious 2, 3, 21, 23, 25.
11/30/2015	18	fract--	#18 fractured about one month ago
11/30/2015	18	fract--	#18 grossly decayed, buccal fracture, buccal swelling
11/30/2015	18	broke--	#18 broken crown
11/30/2015	18	fract--	fractured tooth 9, 18 w/ no ttp
11/30/2015	19	fract--	#19 fractured
11/30/2015	28	fract--	#28- B restoration, fractured crown, sensitive to percussion
11/30/2015	28	fract--	#28- B restoration, fractured crown, sensitive to percussion, PAP
11/30/2015	29	fract--	#29- fractured
11/30/2015	30	fract--	Gross decay, fractured #30
11/30/2015	30	broke--	Broken restorations on 3,14,19,29,30
11/30/2015	31	fract--	fractured #31

Date	Tooth	Key-No-Yes	phrase
11/30/2015	31	fract--	Dental: fractured #31, no other carious lesion noted, several restorations present
12/1/2015	19	fract-amalgam-	#19 D fracture, #30 large MLB amalgam with M and D fractures.
12/1/2015	19	fract--	#19 fractured a year ago.
12/1/2015	29	fract--	Fractured #29, Periapical RL
12/1/2015	31	fract--	A: #31 has a mesio distal fracture.
12/1/2015	31	fract--	On Transillumination the fracture line was observed mesio distal on#31.
12/1/2015	31	fract--	The prognosis for restoring #31 with fracture was not favourable.
12/1/2015	31	crack--	Consultation * Diagnoses Cracked #31 with PAP
12/1/2015	31	crack--	Hard Tissue DX cracked #31,
12/2/2015	18	fract--vertical	Vertical root fracture #18
12/2/2015	18	fract--vertical	the diagnosis for #18 is a vertical root fracture.
12/2/2015	18	fract--vertical	The options for the patient are to extract #18, or to open the tooth through the crown and verify if a vertical root fracture is present, and if not, initiate a re-tx of #18 due to the short fills of
12/2/2015	18	fract--vertical	vertical root fracture #18
12/2/2015	30	fract--	#30 fractured, gross decay, pulp involvement
12/2/2015	30	fract--	dental: fractured #30, gross decay with pulp involvement
12/2/2015	4	fract--	Distal fracture #4
12/2/2015	4	fract--	Dental: Crown #7, Fracture #4

Date	Tooth	Key-No-Yes	phrase
12/3/2015	13	fract--	Patient presents with concern also that #13 existing restoration fractured.
12/3/2015	13	fract-amalgam-	Dental History #13 existing fractured amalgam was replaced in August 2015
12/3/2015	13	fract-amalgam-	HPI Pt had large amalgam restoration fracture on tooth #13 in Aug 2015.
12/3/2015	14	fract--	-#14: tooth fracture, non-restorable.
12/3/2015	14	split--	#14: Split fracture, non-restorable
12/3/2015	14	fract--	70 y/o F presented to clinic with fractured tooth #14.
12/3/2015	14	fract--root	Pt presented to GP clinic this morning for further evaluation, but the tooth #14 was found out to be non-restorable due to root fracture.Pt endorses pain from chewing.
12/3/2015	19	fract--	#19: caries/fracture approximating pulp
12/3/2015	19	fract--	#19: fractured carious mesial
12/3/2015	2	fract--	Dental: #2 recurrent caries fractured restoration, non-restorable - patient opts to EXT
12/3/2015	2	fract--	#2 recurrent caries, fractured restoration
12/4/2015	14	fract--	#14 fractured with secondary decay, localized ulceration on buccal gingiva
12/4/2015	14	fract--	#14 Crown fracture
12/4/2015	14	fract--	Dental: #14 Crown Fracture
12/4/2015	14	fract--	#14 Fracture
12/4/2015	18	fract--	fractured #18
12/4/2015	18	fract--	#18 fractured/gross decay
12/4/2015	18	fract--	dental: fractured #18, decay involving pulp

Date	Tooth	Key-No-Yes	phrase
12/4/2015	2	fract--	Dental: #2-MB Fracture
12/4/2015	2	fract--	#2-MB Fracture
12/4/2015	20	fract--	Fractured tooth 20, 21, 22, 23.
12/4/2015	21	fract--	Fractured tooth 20, 21, 22, 23.
12/4/2015	3	fract--	#3 Cuspal fracture/caries
12/4/2015	3	fract--	#3 fractured on DL
12/4/2015	30	broke--	#19, 20, 30, 31 broken crown
12/4/2015	31	fract--	Hard tissue exam (Findings) distal and mesial fracture lines #31, general 5 mm overjet, class II occlusion.
12/7/2015	28	fract--	Grossly carious/fractured crown #28 with PARL
12/7/2015	28	fract--	#28 grossly fractured down to gumline.
12/7/2015	28	fract--	- Grossly carious/fractured #28 with PARL
12/8/2015	12	fract--	Fractured and non-restorable #10 and 12
12/8/2015	3	fract--	#3 crown fracture
12/8/2015	3	fract--	#3 fractured restoration
12/8/2015	3	fract--	40 yom with HIV and HTN presents today for evaluation of #3 for extraction, says it fractured 2 days ago when patient was in car accident.
12/8/2015	5	fract--	Fracture #5 into pulp
12/8/2015	5	fract--	#5 Complicated fracture w/ pulpal involvement
12/9/2015	15	fract--	Fractured/rampant decay non-restorable teeth: #1, 15, 32
12/9/2015	15	fract--	Tooth #15 has a non-restorable fracture and bacterial pulpal involvement.
12/9/2015	15	fract--	#15 distal crown fracture

Date	Tooth	Key-No-Yes	phrase
12/9/2015	15	fract--	#15 distal fracture
12/9/2015	18	fract--	fractured tooth 18
12/9/2015	18	fract--	Fractured #18
12/9/2015	18	fract--	Dental: fracture of tooth 18
12/9/2015	3	fract--root	Retained root #3 and fractured #4 extracted without complication.
12/9/2015	4	fract--	Grossly carious/fractured #4
12/9/2015	4	fract--root	Retained root #3 and fractured #4 extracted without complication.
12/10/2015	14	fx--	decay, #4M watch, #5F possible overhang, #11F recurrent decay, #12 MD decay, #13 recurrent decay, #14D recurrent decay, #19D recurrent decay, #20 O fx restoration.
12/10/2015	19	fract--	Exam reveals Tooth #19 fractured through from mesial to distal Non Restorable
12/10/2015	3	fract--	Dental History Tooth #3 - crown fractured about 1.5 Months ago
12/10/2015	5	fract--	Dental History Tooth #3 - crown fractured about 1.5 Months ago
12/11/2015	14	fract--	#14 fractured a couple months ago.
12/11/2015	14	fract--	Dental: Fractured #14
12/11/2015	14	fract--	Fractured #14
12/11/2015	19	fract--	D fracture #19
12/11/2015	19	fract--	#19 crown fracture
12/11/2015	19	fract--	#19 crown completely fractured of
12/11/2015	20	fx--	1.gross caries #20, fx at bone level
12/11/2015	20	fract--	fractured bridge 18-21 with nonrestorable #20

Date	Tooth	Key-No-Yes	phrase
12/11/2015	20	fract--	surgery for leg fracture in 2000
12/11/2015	29	fract--	#29 - fractured, hopeless
12/11/2015	29	fract--	#29 fractured
12/11/2015	3	fract--	Fractured #2, 3, 6, 7, 8, 9, 10, 28.
12/11/2015	3	fract--	fractured/gross decay #3
12/11/2015	3	fract--	Fractured crown #3 and #4
12/11/2015	3	fract--	Dental: Fractured crown #3, #4
12/11/2015	3	fract--	Fractured crown #3, #4
12/11/2015	3	fract--	#3 fractured restoration, decay
12/11/2015	4	fract--	Fractured crown #3 and #4
12/11/2015	4	fract--	Dental: Fractured crown #3, #4
12/11/2015	4	fract--	Fractured crown #3, #4
12/14/2015	14	fract--	#14 fractured DL cusp, gross decay, percussion sensitive
12/14/2015	14	fract--	teeth #4 & 14 fractured about 3 months ago while eating candy, current pain level 10/10, pt denies hx sinusitis, change of vision, swelling, or fever.
12/14/2015	19	fract-elevat-	#19 crown elevated and fractured.
12/14/2015	19	fract-forcep-	Attempted forceps extraction tooth #19 and fractured crown.
12/14/2015	3	fract--	#30 fractured at the level of the gingiva.
12/14/2015	3	fract--	Fractured #30 at the gumline
12/14/2015	4	fract--	#4Fractured lingual cusp, gross decay, percussion and palpation sensitive
12/14/2015	4	fract--	#14 fractured DL cusp, gross decay, percussion sensitive

Date	Tooth	Key-No-Yes	phrase
12/14/2015	4	fract--	#4 gross decay, fractured crown, PARL present
12/14/2015	4	fract--	teeth #4 & 14 fractured about 3 months ago while eating candy, current pain level 10/10, pt denies hx sinusitis, change of vision, swelling, or fever.
12/15/2015	14	broke--	Dental History dental caries and broken restoration #14
12/15/2015	14	fract--	NSRCT+ P&C and crown option given to patient for fractured #14.
12/15/2015	14	fract--	Fractured #14
12/15/2015	14	fx--	#14 fx 4 mo ago while eating.
12/15/2015	14	fx--	#3 Fx MB cusp, #14 Fx M half of tooth.
12/15/2015	3	fx--	#3 fx 1 yr ago spontaneously.
12/15/2015	3	fx--	#3 Fx MB cusp, #14 Fx M half of tooth.
12/16/2015	12	broke--	multiple broken down teeth due to caries 5,6,7,8,9,10,11,12,13, 15, 21,22,23,24,25,26,27,28, 30
12/16/2015	13	broke--	multiple broken down teeth due to caries 5,6,7,8,9,10,11,12,13, 15, 21,22,23,24,25,26,27,28, 30
12/16/2015	14	fract-elevat-	Upon elevation of tooth #14, a carious portion of tooth #13 fractured.
12/16/2015	14	fract--	#14 gross decay, non-restorable, fractured to osseous level on the mesial.
12/16/2015	14	fract--	#14 gross decay, non-restorable, fractured to osseous level on the mesial
12/16/2015	14	fract--	Large fracture of restoration on RCT #14
12/16/2015	14	fract--	Fracture and recurrent caries on NSRCT #14
12/16/2015	14	fract--	Dental: Fractured #14 NSRCT previously treated

Date	Tooth	Key-No-Yes	phrase
12/16/2015	15	broke--	multiple broken down teeth due to caries 5,6,7,8,9,10,11,12,13, 15, 21,22,23,24,25,26,27,28, 30
12/16/2015	19	fract--	#19 fractured buccal cusp, gross decay, tender cto percussion
12/16/2015	30	fract--	pain has been getting worse over the past couple months since filling fractured on tooth #30 - pain is 10/10 wakes him up out of his sleep.
12/16/2015	5	broke--	multiple broken down teeth due to caries 5,6,7,8,9,10,11,12,13, 15, 21,22,23,24,25,26,27,28, 30
12/17/2015	2	broke--	2, 18, 31, 32 severely broken down
12/17/2015	4	fract--	39 yom presents today for evaluation of #4, fractured and hurting
12/17/2015	4	fract--	tooth #4- fractured, carious
12/18/2015	14	fract--	Explained to pt there is a possiblity for a crown #14 due to large restoration and fracture found.
12/18/2015	18	fx--	#18 fx.
12/18/2015	19	fx--	#19 fx.
12/18/2015	20	fract--	Abfraction #21 - B, recurrent caries #20-DB.
12/18/2015	20	fract-partial-	Pt diagnosed with:Generalized severe chronic periodontitis (Refractory), secondary OT (#4,5,28,29,12,13,20,21), partial edentulism, nicotine stomatitis.
12/18/2015	20	fract--	Diagnosis #20 fractured, #13D caries
12/18/2015	20	fract--	#20 facial fractured.
12/18/2015	20	fract--	Diagnosis #20 Facial fracture
12/18/2015	20	fract--	Diagnosis #20 Facial fracture

Date	Tooth	Key-No-Yes	phrase
1/4/2016	20	broke--	tooth (#20) has been broken for more than a year, started hurting 3 days ago, pt noticed swelling, fever, & ear aches.
1/4/2016	20	fract--	#20 fractured to gum line
1/5/2016	15	fract--	#15 fractured at level of crestal bone.
1/5/2016	15	fract--	non restorable crown fracture #15
1/5/2016	15	fract--	#15 fractured at crestal bone level, no restorable
1/5/2016	19	fract--	#19 symptomatic (very sensitive to percussion and palpation) and carious w/ crown fracture.
1/5/2016	19	fract--	Tooth #19 (fractured) became symptomatic about a month ago with pain that pt describes as consistent nagging pain with episodes of sharp pain.
1/5/2016	2	fract--	61 males PPTC CC assoc with UR tooth (#2) sensitive to cold for past 6 month since tooth fractured.
1/5/2016	31	crack--	#31 cracked - nonrestorable
1/6/2016	13	fract--	Fractured crown tooth #13.
1/6/2016	18	fract--	Pt reports fracturing #18 and #4 in Oct 2015.
1/6/2016	4	fract--	#4 - fractured, gross decay
1/6/2016	4	fract--	Pt reports fracturing #18 and #4 in Oct 2015.
1/7/2016	29	fract--	#29 DO fracture.
1/7/2016	29	fract--	Fracture #29 D.
1/8/2016	13	fract--	#13 - fractured
1/8/2016	13	fract--	#13 - fracture, percussion sensitive, non-restorable
1/8/2016	13	fract--	#13 - fractured, very percussion sensitive

Date	Tooth	Key-No-Yes	phrase
1/8/2016	2	fract--	- Grossly carious and fractured #2
1/8/2016	29	fract--	Gross caries/ fractured crowns - #3,13,19,22, 29, 31
1/8/2016	29	fract--	Gross caries/ fractured crowns - #3,13,19,22, 29, 30, 31
1/8/2016	3	fract--	#13 - fractured
1/8/2016	3	fract--	#13 - fracture, percussion sensitive, non-restorable
1/8/2016	3	fract--	#13 - fractured, very percussion sensitive
1/8/2016	31	fract--	#19, 20, 31 fractured crown
1/11/2016	12	fract--	Fractured crowns on #12,13,15
1/11/2016	12	fract--	Fractured #11 and 12
1/11/2016	12	fract--	Bridge fellout, fractured crowns #11 and #12
1/11/2016	12	fract--	Fractured #11 and #12
1/11/2016	13	fract--	Fractured crowns on #12,13,15
1/11/2016	14	fract--	#14 gross decay and fractured, palpation sensitive, negative to percussion
1/11/2016	14	fract--	Gross caries, fractured crown #14
1/11/2016	15	fract--	Fractured crowns on #12,13,15
1/12/2016	12	fract--	#12 - fractured
1/12/2016	12	fract--	#12 - fractured, NSRCT treated
1/12/2016	12	fract--	#12 fractured
1/12/2016	2	fract--vertical	PARL #2 (chronic apical abscess with necrotic pulp), with likely vertical root fracture
1/12/2016	4	broke--	S: PPTC for IOE and tx plan CC: I have a broken down tooth that hurts sometimes HPI: pt reports

Date	Tooth	Key-No-Yes	phrase
			#4 had a previous restoration and fractured several months ago.
1/12/2016	4	fract--	Tooth #4 presents as fractured below the
1/12/2016	4	fract--	34 Yom with h/o lower jaw fracture as well as dental trauma 1-2 years ago.
1/12/2016	4	fract--	carious/fractured #4
1/12/2016	4	fract--	carious/fractured #4- likely needs RCT, crown
1/13/2016	15	fract-elevat-	#15: Attempted elevator and forceps extraction, however, crown fractured off to gumline.
1/13/2016	15	fract--	Pt states that she was eating a piece of bread yesterday and #15 tooth fractured.
1/13/2016	15	fract--	Grossly carious/fractured #2, #15.
1/13/2016	15	fract--	Grossly carious #s 2 (fractured to gumline) and #15.
1/13/2016	19	fract--	#19 gross caries, fractured crown
1/13/2016	19	fract--	#19 gross caries, PARL, fractured crown
1/13/2016	19	fract--	gross caries, fractured crown #19
1/13/2016	2	fract--	Grossly carious/fractured #2, #15.
1/13/2016	2	fract--	Grossly carious #s 2 (fractured to gumline) and #15.
1/13/2016	29	fract--	PPTC with fractured restoration #29.
1/14/2016	19	broke--	Broken down restoration #19
1/14/2016	2	broke--	2003 - broken left hand, no complications
1/14/2016	30	fract--	Dental: severe fracture/decay #30
1/15/2016	15	fract--	#15 - caries, #19 - fractured
1/15/2016	19	fract--	Fractured crown #19

Date	Tooth	Key-No-Yes	phrase
1/15/2016	19	fract--root	#19: Crown fractured off, root tips remaining, bone loss
1/15/2016	19	fract--	#19 fractured off a few weeks ago.
1/15/2016	19	fract--	#15 - caries, #19 - fractured
1/15/2016	19	fract--	#19- Gross caries, #30-fractured crown
1/15/2016	20	fract--	#20 fractured crown- nonrestorable
1/15/2016	29	fract--	fractured #29
1/15/2016	29	fract--	swelling mandibular anterior fractured 29
1/15/2016	29	fract--	fractured #29 fractured procelain on bridge
1/15/2016	29	fract--	Pain associated with fractured #29
1/15/2016	3	fract--	#1 caries, #3 fractured crown and caries
1/15/2016	3	fract--	#1 caries, #3 fractured crown and caries,
1/15/2016	3	fract--	#3 - fractured and carious
1/15/2016	30	fract--	Fractured Crown 19 and 30
1/15/2016	30	fract--	Fractured crown- 30
1/15/2016	30	fract--	#19- Gross caries, #30-fractured crown
1/15/2016	30	fract--	#30 - negative to palpation, fractured
1/15/2016	30	fract--	#30 fractured crown
1/15/2016	30	fract--	#30 fractured
1/19/2016	18	fract--	#18-L fractured
1/19/2016	30	crack--	updated med hx, 4bwx, 1PA #30 (pt complained of pain when chewing) hne, h/s, rcp, floss, ohi, exam (Dr talked to pt about the possible issues going on with #30, He thinks that the tooth could

Date	Tooth	Key-No-Yes	phrase
1/19/2016	30	crack--	- #30 had symptoms of cracked tooth (see Dr note from 9/30) and a crack present on the distal marginal ridge.
1/19/2016	30	crack--	consult for 30, tooth crack and pt having some pain but manageable.
1/19/2016	31	fract--	#31-B fractured
1/20/2016	19	fract--	#19 fracture and caries, sensitive to percussion and palpation
1/20/2016	19	fract--	dental: #19 symptomatic apical periodontitis, caries, fracture.
1/20/2016	30	fract--	30 - SSC w/ endo and previous apico, fractured crown retained w/ OTC Crown Cement by the pt - non-restorable
1/20/2016	4	fract--	fractured #4
1/20/2016	4	fract--	fractured #4 due to GD
1/20/2016	4	fract--	Fractured #4,20
1/20/2016	4	fract--	fractured#4 with sym apical perio
1/21/2016	18	fract--	grossly decayed and fractured #2, 14, 18
1/21/2016	3	fract--	Decay #13, Fractured #14
1/27/2016	20	fract--root	Grossly carious/fractured #9 (previously RCT'ed), Retained root #12, Grossly carious #14, Carious/fractured #20, Grossly carious #31
1/27/2016	20	fract--	#20-fractured at gumline.
1/27/2016	3	fract-porcelain-	TX: Tx plan presented to pt for mand nesbit replacing #30 and was signed by Pt Explained to patient the risk of making rest-preps through existing crowns (Possibility of porcelain fracture of preppin

Date	Tooth	Key-No-Yes	phrase
1/27/2016	31	fract--root	Grossly carious/fractured #9 (previously RCT'ed), Retained root #12, Grossly carious #14, Carious/fractured #20, Grossly carious #31
1/28/2016	15	fract--	Grossly carious/fractured remaining maxillary and mandibular teeth: #s 2-15, 19-31
1/28/2016	15	fract--	Grossly carious/fractured remaining maxillary and mandibular teeth: #s 2-15, 18-31
1/28/2016	19	fract--	Grossly carious/fractured remaining maxillary and mandibular teeth: #s 2-15, 19-31
1/28/2016	2	fract--	Grossly carious/fractured remaining maxillary and mandibular teeth: #s 2-15, 19-31
1/28/2016	2	fract--	Grossly carious/fractured remaining maxillary and mandibular teeth: #s 2-15, 18-31
1/28/2016	28	fract-elevat-	Tooth #28 crown fractured off upon luxation with forceps - minimal buccal and lingual flaps elevated and forceps placed
1/28/2016	30	fract--	PT reports #30 buccal fractured in 2014.
1/28/2016	31	fract--	Examination of #31 revealed fractured alloy.
1/28/2016	31	fract--	Prob: Fractured alloy #31
1/28/2016	31	fract--	Prob: Fractured restoration #31 -- asymptomatic
1/28/2016	31	fract--	fractured crown of #31
1/28/2016	31	fract-elevat-	Tooth #31 elevated, crown fractured/delivered w/ forcep.
1/28/2016	31	fract--	Grossly carious/fractured remaining maxillary and mandibular teeth: #s 2-15, 19-31
1/28/2016	31	fract--	Grossly carious/fractured remaining maxillary and mandibular teeth: #s 2-15, 18-31
1/28/2016	4	fract--	Grossly carious teeth #'s 14,15, fractured #17

Date	Tooth	Key-No-Yes	phrase
1/28/2016	4	fract--	Grossly carious teeth #'s 14,15, fractured 17
1/28/2016	5	fract--	Grossly carious/fractured remaining maxillary and mandibular teeth: #s 2-15, 19-31
1/28/2016	5	fract--	Grossly carious/fractured remaining maxillary and mandibular teeth: #s 2-15, 18-31
1/29/2016	13	broke--	gross decay, multiple broken down teeth 5-11,13,19-30.
1/29/2016	19	fract--	fractured crown on #19
1/29/2016	19	fract--	A: Fractured PFM crown 19
1/29/2016	21	broke--	Dental History D portion of crown of #21 broke 3-4 weeks ago.
1/29/2016	5	broke--	gross decay, multiple broken down teeth 5-11,13,19-30.
2/1/2016	13	fract--	gross caries 13, fractured off crown
2/1/2016	13	broke--root	multiple broken down teeth, 13 root tip
2/1/2016	13	fract--	coronal fracture 13
2/1/2016	18	fract--	fractured #18 d/t caries
2/1/2016	18	fract--	fractured teeth #18, 20
2/1/2016	18	fract--	fractured teeth #18,20
2/1/2016	31	fract--root	Fractured/non-restorable #31 (retained roots).
2/1/2016	31	fract--root	Fractured and retained root #31.
2/1/2016	31	fract--	Fractured/non-restorable #31.
2/1/2016	5	fract--	13+mm probing m-5, possible mesial marginal ridge fracture.
2/1/2016	5	fract-forcep-root	#5 delivered with forceps and M root tip fractured during delivery.

Date	Tooth	Key-No-Yes	phrase
2/2/2016	2	fract--	Carious Fracture #2
2/2/2016	30	fract--root	tooth #30 w/ fracture down to root on disto-lingual region
2/3/2016	19	fract--	#19 non-restorable fractured and carious
2/3/2016	19	fract--	Fractured DB cusp #19
2/3/2016	19	fract--	Fractured #19, symptomatic
2/3/2016	19	fract--	#19 fractured one year ago and the distal portion fell out a few months ago.
2/3/2016	3	broke--	Remaining Maxillary teeth #3-13, heavily restored, #11 broken crown restoration.
2/3/2016	31	fract--	Crown fracture #21, #31
2/3/2016	31	fract--	#31- fractured crown.
2/3/2016	4	fract--	Fractured #4,
2/4/2016	19	broke--	Broken crown #20 and caries around restoration margin #19
2/4/2016	19	fract--	Fractured #20 and caries #19, with buccal abfraction
2/4/2016	19	fract--	A: #5 Fracture lingual cusp on, #19 presen
2/4/2016	20	fract--	Fractured #20
2/4/2016	20	broke--	Broken crown #20 and caries around restoration margin #19
2/4/2016	20	fract--	Fractured #20 and caries #19, with buccal abfraction
2/4/2016	20	fract--	#20 fractured crown summer 2015.
2/4/2016	31	fract--	fractured crown #30 &31, B tender to palation
2/4/2016	31	fract--	fractured crown #30 &31--ext

Date	Tooth	Key-No-Yes	phrase
2/5/2016	18	fract--	O: BP 140/93 pulse is 55 , missing crown on #18 , fractured cusp on #3,
2/5/2016	2	fract--	#2 coronal fracture
2/5/2016	20	fract--root	Fractured/decayed #17, #16 and #20 root tips, decayed #32.
2/5/2016	20	fract--root	Fractured/decayed #17, #16 and #20 root tips, decayed #32
2/5/2016	20	fract--	#20 has been fractured for about 4 months, spontaneously causing pain that keeps the patient awak at night, currently a 3 out of 10 when ranking pain.
2/5/2016	20	fract--	Fractured crown #20
2/5/2016	20	fract--	Fractured crown #20, PAP #20
2/5/2016	3	fract--	Fractured #3
2/5/2016	31	fract--	#31 Fractured crown large carious lesion
2/5/2016	31	fract--	Carious lesions on #31 and 19 with part of crown fractured off.
2/8/2016	13	fract--	#13 - fractured cusp, percussion sensitive.
2/8/2016	13	fract--	#13 - fractured cusp
2/8/2016	13	fract--	#13 - fractured cusp, symptomatic periapical periodontitis, irreversible symptomatic pulpitis.
2/8/2016	14	fract--	#14 - fractured cusp, restorable with crown lengthening, NSRCT, core-build up, and crown.
2/8/2016	14	fract--	#14 - gross caries, fractured cusp
2/8/2016	14	fract--	#14 - fractured tooth
2/8/2016	31	fract--	#31 coronal fracture

Date	Tooth	Key-No-Yes	phrase
2/9/2016	20	fract--	Dental History PPTC with crown fractured off tooth #20, previously RCT treated.
2/9/2016	28	fract--	gross caries and fracture 28
2/9/2016	5	broke-bracket-	During extraction of tooth #5, bracket on tooth #7 broke off.
2/10/2016	4	fract--	49 yo healthy male PTC w/ fractured #4, asymptomatic.
2/10/2016	4	fract--	#4 - fractured
2/11/2016	19	fract--	23 yo M presents with complaints of fractured tooth 19.
2/11/2016	19	fract--	FRactured 19.
2/11/2016	19	fract--	Fractured tooth 19.
2/11/2016	2	broke--	2 - broken and non-restorable
2/11/2016	5	broke--	5-10 - broken and non-restorable
2/12/2016	12	fract--	#12 coronal fracture & decay
2/12/2016	13	fract--	1) #13 grossly carious, crown fractured off.
2/12/2016	2	fract--	#20 fractured crown with distal decay
2/12/2016	2	broke--	#20 broken crown with decay.
2/12/2016	20	fract--	#20 fractured crown with distal decay
2/12/2016	20	broke--	#20 broken crown with decay.
2/16/2016	2	broke--	The patient noticed this tooth has been broken from past 2 yrs.
2/16/2016	29	fract--	Fractured #29
2/16/2016	4	fract--	Fractured tooth #4
2/16/2016	4	fract--	#4 fractured and non-re

Date	Tooth	Key-No-Yes	phrase
2/17/2016	19	fract--	#19 fractured for a month
2/17/2016	19	fract--	Fractured #19
2/17/2016	19	fract--	fractured #19
2/17/2016	19	fract--	PAP distal #19, fractured #19
2/17/2016	3	fract--	#3-fractured crown with gross caries
2/17/2016	3	fract--	#3-fractured crown w/ caries, PAP
2/17/2016	3	fract--	Tooth #3 fractured 1 year ago and pt experiences occasional pain and inflammation.
2/17/2016	4	fract--	Grossly carious, fractured tooth #4.
2/17/2016	4	fract--	Carious/fractured tooth #4
2/17/2016	4	fract--	Pt states tooth #4 fractured ~3 weeks ago while on a trip to Tennessee.
2/18/2016	13	fract-deliver-root	#13 Buccal root fractured, delivered the root tip with ronguer
2/18/2016	14	fract--	DB fracture and gross decay on #14
2/18/2016	29	fract--	carious #29- with fractured distal crown
2/18/2016	3	fract--	S: pptic for fractured tooth #3
2/18/2016	3	crack-amalgam-	A: cracked MO amalgam restoration with recurrent caries tooth #3
2/18/2016	3	crack--	#3 MO amalgam, DMR crack, DI cusp crack, P groove crack, transillumination + (see pics)
2/18/2016	3	crack--	Several cracks present on #3 crown
2/18/2016	3	crack--	Recommended accessing #3 and microscopically examine for intrapulpal cracks.
2/18/2016	3	fract--vertical	#3: Vertical fracture.

Date	Tooth	Key-No-Yes	phrase
2/18/2016	3	fract--vertical	Pt has been seen in Grad Endo - dx: vertical root fracture #3
2/18/2016	3	fract--vertical	#3- vertical root fracture, endo access covered with IRM
2/18/2016	3	fract--vertical	#3: Vertical root fracture.
2/18/2016	3	fract-deliver-root	#13 Buccal root fractured, delivered the root tip with ronguer
2/18/2016	3	fract--	#3 fractured restoration
2/18/2016	3	fract--	#3 & 4 fractured
2/18/2016	4	fract--	#4 fractured tooth
2/18/2016	4	fract--	#3 & 4 fractured
2/19/2016	29	broke--	A: #29 broken tooth
2/19/2016	4	fract--	Dental History Gross carious, fractured crown #14
2/22/2016	13	fract--	#13- d fracture
2/22/2016	13	fract--	-#13-d fracture, d gross caries, apical periodontitis
2/22/2016	13	fract--	Fractured crown #13
2/22/2016	13	fract--	#13- fractured crown
2/22/2016	20	fract--	Recurrent decay and fractured tooth #20
2/22/2016	29	fract--	-#29 coronal fracture
2/22/2016	30	fract--	52 yo healthy but naxious M with symptomatic and fractured tooth #30 as well as carious #19
2/22/2016	30	fract--	Symptomatic fractured tooth #30 that is severely tender to palpation and to percussion.
2/22/2016	31	fract--	#31 Fractured crown and gross decay

Date	Tooth	Key-No-Yes	phrase
2/22/2016	31	fract--	#31 fractured crown and gross decay
2/22/2016	31	fract--	Dental: #15 and 31 fractured crown and gross decay
2/22/2016	31	fract--	#31-mb fracture
2/22/2016	31	fract--	-#31-mb fracture, MO recurrent caries, apical periodontitis
2/23/2016	12	fract--root	Upon clinical examination #12 has complete coronal fracture and root is remaining.
2/23/2016	12	fract--	#12 complete coronal fracture
2/23/2016	12	broke--	Patient reports that she broke #12 in september.
2/23/2016	12	fract--	Dental: #12 complete coronal fracture
2/23/2016	15	fract--	Gross decay #2, #15, nonrestorable, both severely fractured
2/23/2016	2	fract-amalgam-	#2: Fractured amalgam restoration
2/23/2016	2	fract--	Fractured#2
2/23/2016	2	fract--	Fractured teeth #2
2/23/2016	29	broke--	Pt presents with broken crown #29.
2/23/2016	29	fract--	#29 Fractured to gingival magrin--nonrestorable.
2/23/2016	29	fract--	PPTC (grad perio) for implant for fractured tooth in site #29
2/23/2016	29	fract-partial-	Diagnosis: Generalized gingivitis//Partial Edentulism//Bruxism//Fractured #29
2/23/2016	31	fract--	#31 symptomatic and fractured w/ severe periodontitis
2/23/2016	31	fract--	#31 fractured, periodontally involved
2/23/2016	4	fract--	Fractured non restorable teeth 4, 10, 28, 29.

Date	Tooth	Key-No-Yes	phrase
2/23/2016	4	fract--	Fractured crowns: #4, 10, 29, 32
2/23/2016	4	fract--	Crown fracture #4
2/24/2016	12	fract--root	Grossly carious/fractured #9 (previously RCT'ed), Retained root #12, Grossly carious #14, Carious/fractured #20, Grossly carious #31
2/24/2016	12	fract--root	- Grossly carious/fractured #9 (previously RCT'ed), Retained root #12, Grossly carious #14, Car
2/24/2016	14	fract--root	Grossly carious/fractured #9 (previously RCT'ed), Retained root #12, Grossly carious #14, Carious/fractured #20, Grossly carious #31
2/24/2016	14	fract--root	- Grossly carious/fractured #9 (previously RCT'ed), Retained root #12, Grossly carious #14, Car
2/24/2016	15	fract-elevat-root	ext #15- crown fractured off, roots elevated and delivered separately.
2/24/2016	2	fract--root	Grossly carious/fractured #9 (previously RCT'ed), Retained root #12, Grossly carious #14, Carious/fractured #20, Grossly carious #31
2/24/2016	2	fract--root	- Grossly carious/fractured #9 (previously RCT'ed), Retained root #12, Grossly carious #14, Car
2/24/2016	4	fract--root	Grossly carious/fractured #9 (previously RCT'ed), Retained root #12, Grossly carious #14, Carious/fractured #20, Grossly carious #31
2/24/2016	4	fract--root	- Grossly carious/fractured #9 (previously RCT'ed), Retained root #12, Grossly carious #14, Car
2/24/2016	5	fract-elevat-root	ext #15- crown fractured off, roots elevated and delivered separately.
2/25/2016	18	fract--	#18 fractured cusp and caries

Date	Tooth	Key-No-Yes	phrase
2/25/2016	18	fract--	#18 fractured with caries
2/25/2016	28	fract-forcep-	Crown of tooth #28 fractured, delivered w/ forcep.
2/25/2016	3	fract--	Fractured restoration #2, 13, 29
2/25/2016	3	fract--	Dental History #13 crown fracture over a year ago.
2/25/2016	30	fract--	#30- fracture on distal
2/25/2016	5	fract-forcep-root	Palatal root tip fractured on #5 during delivery with forceps.
2/26/2016	15	fract--	Large fracture on mesial marginal ridge #15
2/26/2016	19	fx--	O: ProbFocEx / 120/83=75 / Panx + 4BWx + 1PA #31 and 1PA #19 / #19 Fx -DB w.out pain exudate #31 M-D Fx with pain to percussion / patient is afebrile there is no mobility patterns
2/26/2016	31	fx--	O: ProbFocEx / 120/83=75 / Panx + 4BWx + 1PA #31 and 1PA #19 / #19 Fx -DB w.out pain exudate #31 M-D Fx with pain to percussion / patient is afebrile there is no mobility patterns
2/26/2016	31	fract-elevat-	Attempted elevation #31 and fractured crown.
2/29/2016	19	fract--	#19-fractured distal cusp, patient informed that #19 may be restorable with NSRCT, full-cuspal coverage but patient declined restorative treatment due to costs.
2/29/2016	19	fract--	Fractured #19
2/29/2016	19	fract--	#19-fractured
2/29/2016	20	fract--	Caries/Fractured #20 (symptomatic)
2/29/2016	20	fract--	#20: mesial fracture, carious
2/29/2016	5	broke--	Grossly carious and broken down #'s 5,6,8,9,10,11,21,22,23,26,27,28.

Date	Tooth	Key-No-Yes	phrase
2/29/2016	5	broke--	Grossly carious and broken down #'s 5,6,8,9,10,11,21,22,23,26,27,28
3/1/2016	3	fract--	- Fractured restoration and PARL associated with #3.
3/1/2016	3	fract--	- Fractured restoration #3 - Symptomatic
3/1/2016	31	fract--	Frurther examination of #31 shows a buccolingual fracture across the mesial tooth with dis
3/1/2016	4	fract--	#4 fractured crown RCT treated
3/1/2016	4	fract--	#4 Fractured Rct treated tooth
3/2/2016	12	fract--root	Root tips fractured at #'s 5, 12.
3/2/2016	2	fract-elevat-	#2: Fractured crown #2 with attempted elevation.
3/2/2016	31	fract-elevat-	Tooth #31 elevated, crown fractured/delivered w/ forcep.
3/2/2016	5	fract--	Fractured #15
3/2/2016	5	fract--	Fractured #15-unrestorable, recommended ext
3/2/2016	5	fract--	Fractured #15-extr
3/2/2016	5	fract--root	Root tips fractured at #'s 5, 12.
3/3/2016	12	split--	New Caries: #12 Ext-split, #2D, #3 furcation, #20D
3/3/2016	12	split--	e and is aware-Pt does not want treatment other than 4mth cleanings-Pt reported today with pain in #12-tooth is mobile and split-discussed avoiding eating on that side until tooth was ext- Dr d
3/3/2016	19	fract--	fractured #19
3/3/2016	19	fract--	Fractured #19

Date	Tooth	Key-No-Yes	phrase
3/3/2016	30	fract--	ney 12 years ago presents with a CC re dental pain stemming LR quad that is associated with carious/fractured/?restorable tooth #30.
3/3/2016	30	fx--root	Tooth #30-->distal fx extending to distal pulp horn with +caries-->+percussion/palpation with pain that lingers:PARL on distal root
3/3/2016	30	fx--	Tooth #30-->distal fx extending to distal pulp horn with +caries-->+percussion/palpation with pain that lingers
3/3/2016	4	fract--	Gross decay #4 with fractured cusp
3/3/2016	4	broke--	#4 broken lingual cusp to the gingival margin
3/4/2016	12	fract--root	A: findings: crown fractured #10, 28, root tip remained #12, missing molars Mx/Mand
3/4/2016	19	fract-amalgam-	fractured amalgam restoration in #19 with irreversible pulpitis
3/4/2016	28	fract--root	A: findings: crown fractured #10, 28, root tip remained #12, missing molars Mx/Mand
3/4/2016	3	fract--	S: PPTC for emergency with #3 fractured at the gingival level.
3/4/2016	3	fract--	#3 (previously endo treated) fractured at gum line.
3/4/2016	3	fract--	fractured, grossly carious tooth #3
3/4/2016	3	fract--	fractured, grossly carious #3
3/7/2016	13	fract--	dental: #13 fracture palatal cusp, caries
3/7/2016	13	fract--	Fractured #13
3/7/2016	13	fract--	Patient points to #13, tooth lingual cusp is fractured off to gingiva
3/7/2016	13	fract--	#13 fractured palatal cusp, sensitive to percussion and palpation

Date	Tooth	Key-No-Yes	phrase
3/7/2016	15	fract--	#15- MO fracture
3/7/2016	4	fract--	HIV+, COPD, fractured #1,4, caries
3/7/2016	4	fract--	inflammation around #1,4 fractures
3/7/2016	4	fract--	fractured crowns #1,4
3/7/2016	4	fract--	#1 & 4 crown fractures years ago, symptomatic upon chewing
3/7/2016	4	fract--	Fractured crowns #1,4
3/7/2016	5	broke--	#5 broken cusp
3/7/2016	5	broke--	Pt reports tooth crown broke 5 days ago.
3/8/2016	12	fract-elevat-	- Attempted forceps and elevator extraction of tooth #12, however crown fractured off below gumline.
3/8/2016	14	broke--	My upper L tooth broke - indicates #14
3/8/2016	31	fract--	#31 - fracture cusp
3/9/2016	14	fract--	Dental: #4 gross decay, (nonrestorable) #14 fracture (nonrestorable)
3/9/2016	14	fract--	#4 PARL, gross decay, #14 fracture (RCT)
3/9/2016	18	fract--	#18- Fractured enamel, Necrotic pulp
3/9/2016	28	fract--	A: Fractured abutment on #29 bridge came off, #28 lost crown.
3/9/2016	28	broke--	A: #28 SSC broken off near gingiva.
3/9/2016	28	broke--	S: PPTC with CC of #28 temporary crown having broken off
3/9/2016	28	broke--	A: #28 temporary crown broken off, temporary crown originally placed 6-7 months ago.
3/9/2016	28	fract--	A - #28 temp crown fractured due to occlusion

Date	Tooth	Key-No-Yes	phrase
3/9/2016	29	fract--	A: Fractured abutment on #29 bridge came off, #28 lost crown.
3/9/2016	29	broke--	P: Upon exam, bridge on teeth #31, 30, 29 cannot be restored due to the broken abutment on #29.
3/9/2016	31	broke--	P: Upon exam, bridge on teeth #31, 30, 29 cannot be restored due to the broken abutment on #29.
3/9/2016	4	fract--	Dental: #4 gross decay, (nonrestorable) #14 fracture (nonrestorable)
3/9/2016	4	fract--	#4 PARL, gross decay, #14 fracture (RCT)
3/10/2016	12	fract--vertical	PFM crown #12 with anticipated vertical root fracture
3/10/2016	12	fract--vertical	dental: #12 vertical fracture
3/10/2016	13	fract--root	#2 - fractured root, 3-6 grossly carious, 7-9 retained carious roots, 10, 11, 13 grossly carious.
3/10/2016	13	fract--	Grossly carious and/or fractured #s 2-13, 15, 18, 20-22, 26-29
3/10/2016	13	fract--	#13 Gross decay with fractured cusp
3/10/2016	13	fract--	#13 fractured cusp
3/10/2016	13	fract--	#13 fractured cusp with gross decay
3/10/2016	13	fract--	#13 fractured crown with gross decay
3/10/2016	14	fract--	fractured #14 and #15
3/10/2016	15	fract--	fractured #14 and #15
3/10/2016	15	fract--	Grossly carious and/or fractured #s 2-13, 15, 18, 20-22, 26-29
3/10/2016	18	fract--	Grossly carious and/or fractured #s 2-13, 15, 18, 20-22, 26-29

Date	Tooth	Key-No-Yes	phrase
3/10/2016	19	broke--	A: #19 with broken filling and exposed gutta perch bordering on non-restorability, no pain, no hard or soft tissue infection noted.
3/10/2016	19	fract--root	Fractured #19 (retained roots)
3/10/2016	19	fract--root	- Fractured roots #19
3/10/2016	19	fract--	60 yom presents today for evaluation of #19 for extraction, fractured, non restorable.
3/10/2016	2	fract--root	#2 - fractured root, 3-6 grossly carious, 7-9 retained carious roots, 10, 11, 13 grossly carious.
3/10/2016	2	fract--root	Fractured #2, Root tips #15,30
3/10/2016	2	fract--	Dental: Fractured #2
3/10/2016	2	fract--	Fractured #2
3/10/2016	2	fract--	Pt indicates #2 fracture, constant pain 9.5/10 VAS 1 mo
3/10/2016	2	fract--	Elbow fracture with screws (2007)
3/10/2016	29	fract--	Grossly carious and/or fractured #s 2-13, 15, 18, 20-22, 26-29
3/10/2016	3	fract--root	#2 - fractured root, 3-6 grossly carious, 7-9 retained carious roots, 10, 11, 13 grossly carious.
3/10/2016	3	fract--	Grossly carious and/or fractured #s 2-13, 15, 18, 20-22, 26-29
3/10/2016	30	fract--	#30 - nonvital, deep carious, fractured
3/10/2016	30	fract--	Fractured #30
3/10/2016	30	fract--	Gross caries, fractured crown #30
3/10/2016	5	fract--	59 y/o F with h/o TTP, depression, anxiety, and recent bowel surgery for displaced lap band presents for re-eval due to dental pain at teeth #9 and 11 after fracture of bridge recently.

Date	Tooth	Key-No-Yes	phrase
3/10/2016	5	fract--	Grossly carious and/or fractured #s 2-13, 15, 18, 20-22, 26-29
3/11/2016	15	fract--	#15 - fractured crown, deep caries, symptomatic irreversible pulpitis
3/11/2016	18	fract--	Fractured restorations and non restorable 18 and 31.
3/11/2016	18	fract--	Fractured 18 and 31.
3/11/2016	18	fract--	#18 - gross caries with fractured crown
3/11/2016	18	fract--	Patient says #18 fractured off over a year ago but became symptomatic 2 weeks ago.
3/11/2016	18	fract--	#18 Grossly decayed and crown fracture
3/11/2016	18	fract--	Patient says #18 fractured off over a year ago but became symptomatic 2 weeks ago.
3/11/2016	19	fract--	Fractured/carious #19 (sensitive to percussion), multiple other carious teeth
3/11/2016	19	fract--	Fractured/carious #19
3/11/2016	19	fract--	Dental: Fractured/carious #19 with sensitivity to percussion, multiple other carious teeth, PARL #20
3/11/2016	2	fract--	Dental: #2 fractured/gross caries, #30 gross caries, multiple other carious teeth
3/11/2016	2	fract--root	#2 fractured/gross caries, roots approximating sinus
3/11/2016	2	fract--	#2, grossly carious/fractured
3/11/2016	31	crack--	#31 crack along buccal extending subgingival
3/11/2016	31	fract--	#31 hx of pain, fracture, and sinus tract
3/11/2016	31	fract--	#31 fracture, sinus tract

Date	Tooth	Key-No-Yes	phrase
3/11/2016	31	fract--	Fractured restorations and non restorable 18 and 31.
3/11/2016	31	fract--	Fractured 18 and 31.
3/14/2016	13	fract--	#4, 13 fracture
3/14/2016	13	fract--	#13 - carious, fractured, nonrestorable
3/14/2016	14	fract-elevat-	Crown #14 fractured off when pressure applied to elevate.
3/15/2016	12	fract--	PA was obtained on #12 due to fractured tooth and will be addressed next visit after a diagnosis is made.
3/15/2016	15	fract--	#15- crown has fractured off.
3/15/2016	18	fract--	Disto-ligual cusp of #18 is fractured.
3/15/2016	19	fract--	Pt was seen at the hospital on Dec 19,2015 for a mandible fracture, condile fractures, due to falling.
3/15/2016	19	fract--	endo Tx fractured #19 with periapical abscess
3/15/2016	19	fract--	Diagnosed with a fracture of tooth #19 from previous dentist, when he was performing endo as a result of the PARL on #19.
3/15/2016	19	fract--	fractured #19
3/15/2016	19	fract--	full dentition accept #30, generalized attrition, large occlusal composite #19, fractured #19 ttp
3/15/2016	30	fract--	consult for 30, review xrays, hx endo x2, large apical lesion, possible fracture, failed endo.
3/15/2016	4	broke--	decayed and broken down #3 , Decayed margin around tooth #14
3/15/2016	4	broke--	A:tooth #4 core was broken down and you could see through the orifice of the canal

Date	Tooth	Key-No-Yes	phrase
3/15/2016	4	broke--	S: PPTC with bridge 2-4 out of mouth, core for #4 broken in bridge.
3/15/2016	4	broke--	Patient broke bridge from 2-4 while eating.
3/15/2016	4	fract--	Fractured tooth #4
3/15/2016	5	fract--	Fractured crown #5.
3/16/2016	15	fract--	#15- fracture, non-restorable
3/17/2016	13	split--root	Recommended treatment Recommended extraction of tooth #13 due to split root and history of recurring infection; extraction of tooth #32 due to limited restorability given extent of caries.
3/17/2016	15	fract-amalgam-	ML portion of marginal ridge of existing MODL amalgam #15 fractured slightly.
3/17/2016	15	broke--	Additional Narrative Patient presents for recall hygiene apPt Pt CC of broken tooth #15.
3/17/2016	19	fract--	Additonal Narrative At next appt, patient will need endo consult #19 and #2MOD caries excavation and assess for fracture.
3/17/2016	19	broke--	#19 broken cusp with extensive decay, panoramic radiograph not very diagnostic periapically
3/18/2016	15	fract--	PPTC on 7/9/15 due to #2 fractured restoration.
3/18/2016	30	fract--	#14, #30 - fractured off crowns
3/18/2016	31	fract--	#31: M coronal radiolucency, clinically fractured ML cusp with sharp margins adjacent to tongue
3/18/2016	31	fract--	#31L ML fracture cusp extending towards pulp
3/21/2016	12	fract--	Fractured non-restorable tooth (#12)
3/21/2016	12	fract--	#12: DL subgingival fracture, nonrestorable
3/21/2016	19	fract--	Lingual cusps of #19 fractured off at gumline

Date	Tooth	Key-No-Yes	phrase
3/21/2016	19	fract--	Decayed and fractured tooth #19
3/21/2016	29	fract--	#29- pain on percussion, distal half fractured off
3/22/2016	5	fract--	PPTC #5 Buccal cusp fractured.
3/22/2016	5	broke--	#5 broken off to bone level.
3/23/2016	12	fract--	Hard Tissue: #3 MB cusp fracture, #4B abrasion#6B abrasion #9I fracture, #10B abrasion, #11B abrasion, #12B abrasion, #12L cusp fracture with exposed pulp (asymptomatic), #16M decay, #20,21,28 B abra
3/23/2016	12	fract--	#12 has PAP with fractured crown and moderate bone loss.
3/23/2016	12	broke--	#12 broken crown with PAP - nonrestorable
3/23/2016	12	broke--	#12 broken crown with decay
3/23/2016	12	broke--	#12 broken crown with decay and PAP
3/23/2016	19	fract--	D crown fracture on #19 with hot/cold sensitivity
3/23/2016	2	fract--	#12 has PAP with fractured crown and moderate bone loss.
3/23/2016	2	broke--	#12 broken crown with PAP - nonrestorable
3/23/2016	2	broke--	#12 broken crown with decay
3/23/2016	2	broke--	#12 broken crown with decay and PAP
3/23/2016	5	fract--	#5 crown fracture affecting nerve
3/23/2016	5	fract--	mobile #5 crown with evidence of crown fracture
3/24/2016	12	fract--	she also fractured #12, 29 in the meanwhile and would not like any restorative treatments on them.
3/24/2016	12	fract--	New panorex obtained which showed fractured #12, 29 to gingival level.

Date	Tooth	Key-No-Yes	phrase
3/24/2016	12	fract--	#12 fractured upon simple extraction, sectioned using hand piece and fissure bur.
3/24/2016	12	fract--	PPTC for repair of fractured #12.
3/24/2016	15	fract--	Dental: Caries and fracture of #1, caries #15
3/24/2016	15	fract--	#15 - gross decay, crown fracture
3/24/2016	15	fract-partial-	#15 - DO decay reaching the pulp, partial crown fracture
3/24/2016	15	fract--	#15 - DO decay, crown fracture
3/24/2016	15	fract--	#15 - hole/fracture started 1 month ago, pain has been on and off ever since
3/24/2016	15	fx--	GCNR tooth #s 5, 15, & 30 fx'd at the FGM/osseous level
3/24/2016	18	fract--root	#18, 19, 29, 30 - crowns fractured off/only root tips remaining with PARLs
3/24/2016	19	fract--root	#18, 19, 29, 30 - crowns fractured off/only root tips remaining with PARLs
3/24/2016	21	fract--	Fractured #21
3/24/2016	29	fract--	Hard tissue exam (Findings) watche lingual of #3, Restore fracture on #29 and take PA's of #3 and #6 for evals
3/24/2016	29	fract--	Next Appointment Restore fracture on #29 and take PA #3 for eval and #6 for eval of recurrent caries
3/24/2016	29	fract--	A: #29 MODB fractured filling, recurrent caries
3/24/2016	29	fract--	Diagnosis Fractured #29
3/24/2016	29	fract--	#29 determined to be fractured, DO prepared for retention.

Date	Tooth	Key-No-Yes	phrase
3/24/2016	29	fract--	she also fractured #12, 29 in the meanwhile and would not like any restorative treatments on them.
3/24/2016	29	fract--	New panorex obtained which showed fractured #12, 29 to gingival level.
3/24/2016	5	fract--	Dental History Tooth #5 chipped (large mesial fracture)
3/24/2016	5	fract--	Clinical Exam: Large mesial fracture of tooth #5
3/24/2016	5	crack--	A: Mesial portion of #5 has broken off below the gumline and has cracked mesial-distally.
3/24/2016	5	fract--	Panorex obtained: Grossly fractured #5.
3/24/2016	5	fract--	Fractured #5.
3/24/2016	5	broke--	59 yo female presents for an evaluation to possibly have her broken tooth extracted.
3/25/2016	19	fract--root	Due to isolated probing depths on M root of #19 tooth determine to be fractures and recommended extraction with discussion on tooth replacement options
3/25/2016	19	fract--	#19 - fractured crown, recurrent decay
3/25/2016	2	broke--	P: Pt presented with broken MB cusp of #2, no symptoms, heavy plaque build up, Pt would like to take care of it today.
3/25/2016	3	fract--	#3 palatal crown fracture with gingival overgrowth
3/25/2016	3	fract--	Pt reports that #3 fracture two weeks ago
3/25/2016	30	fract--	#30 fractured crown
3/25/2016	31	crack--	Dental: #31-cracked tooth and caries, non restorable
3/25/2016	31	crack--	#31-cracked tooth/caries, non restorable

Date	Tooth	Key-No-Yes	phrase
3/25/2016	31	crack--	#31-cracked tooth and caries, non restorable
3/28/2016	18	fract--	Fractured #18
3/28/2016	18	fract--	Dental: #18 fractured, #19 missing, #30 missing
3/28/2016	18	fract--	Fractured #18
3/28/2016	18	fract--	Fractured #18 with gross caries
3/28/2016	18	fract--	#18 fractured, #19 missing, #30 missing
3/28/2016	30	broke--	no significant medical findings, bady broken down crown on #30
3/28/2016	5	fract--root	fractured #5, impacted #17, retained roots #32
3/28/2016	5	fract--	Fractured #5
3/28/2016	5	fract--root	Dental: fractured #5,, impacted #17, retained roots #32
3/29/2016	14	fract--	Simple extraction of #14 attempted crown fractured.
3/29/2016	14	crack--	Pt states that the filling on #14 cracked off about a year ago and the tooth has been breaking ever since
3/29/2016	14	fract--	fractured #14.
3/29/2016	15	broke--	She states #15 has been broken for awhile.
3/29/2016	4	fract--	Significant dental findings: Midlothian dentist referred to periodontiist, #4 lingual fracture w/ carries, subginival calculus, 4-8 mm PD, separation #9 facial, BOP, separation b/w #17-18, 31-32 inter
3/29/2016	4	fract--	Fractured tooth/restoration: #4
3/29/2016	4	fract--	#4 fractured and deemed non-restorable, discussed potential replacement with implant

Date	Tooth	Key-No-Yes	phrase
			given existng FPD #5-7, missing #2, and potential EXT.
3/29/2016	4	fract--	UR- Ext #1 (periodontally hopeless) and #4 ext with site preservation (fractured nonrestorable)
3/29/2016	4	fract--	Generalized caries, periodontal disease, #4 fractured tooth
3/29/2016	4	fract--	Fractured tooth #4 UR.
3/29/2016	4	fract--	Fracture tooth #4
3/30/2016	15	fract--	#15-fractured crown, #30-fractured crown
3/30/2016	18	fract--	#18: carious fracture with missing tooth structure on distal of clinical crown, extreme and lingering response to cold, negative to percussion and palpation
3/30/2016	19	fract--	EO exam WNL, IO exam WNL: Clinical exam showed #19 to be fractured at the gumline.
3/31/2016	14	fract--	#14 fractured crown with sensitivity to percussion and palpation
3/31/2016	2	fract--	#2: caries, non-restorable, fractured crown
3/31/2016	30	fract--	#30 caries on fractured mesial cusp
3/31/2016	4	fract--	#4 fractured
3/31/2016	4	fract--	Fractured #4, mesial extend to the alveolar ridge
3/31/2016	4	fract--	#4 crown fracture to gingiva
3/31/2016	4	fract--	#4 fractured 2 weeks ago from eating.
4/1/2016	12	broke--	A: Temp Bridge was removed and the build-up on tooth 12 along with some tooth structure broke and came out with the temp.
4/1/2016	14	fract--	grossly carious, fractured #18 with periapical radiolucency, gross caries also teeth #14,16

Date	Tooth	Key-No-Yes	phrase
4/1/2016	14	fract--	Fractured #14, 16
4/1/2016	14	fract--	#14 and 16 fractured
4/1/2016	18	fract--	fractured #18
4/1/2016	18	fract--	Pt reports pain started 2 weeks ago, when #18 fractured.
4/1/2016	19	fract--	#19 fractured DL cusp
4/1/2016	19	fract--	#19 caries and fracture cusp
4/1/2016	3	fract--	#3 - fractured tooth, endo treated tooth
4/1/2016	3	fract--	#30 - fractured tooth, endo treated toot
4/1/2016	3	fract--	Fractured #3, 30
4/1/2016	30	fract--	#30 - fractured tooth, endo treated toot
4/1/2016	30	fract--	Fractured #3, 30
4/1/2016	30	fract--	Fractured tooth #30
4/4/2016	18	fract--	#18-Fractured crown-gross caries
4/4/2016	18	fract--	Dental:#18 Gross caries, fractured crown
4/4/2016	3	fract-forcep-	Attempted forceps extraction #3 and fractured crown.
4/4/2016	3	broke--	2003 - broken left hand, no complications
4/4/2016	3	fract-amalgam-	#3 - existing MODB amalgam with fractured DL cusp an
4/4/2016	31	fract--	Fractured crown #31
4/4/2016	4	fract--	Patient states approx two months ago she fractured the crown of #15 which her dentist, attempted to place a restoration without success due to li

Date	Tooth	Key-No-Yes	phrase
4/4/2016	4	fx--	PDL expansion evident on #4 c/w active periodontal infection/inflammation 2/2 fx
4/4/2016	4	fract--	Tooth #4 with fractured palatal cusp extending beyond the FGM and at or below osseous level.
4/4/2016	4	fract--	present to the OMFS clinic with a CC re acute dental pain stemming from the UR quad associated with fractured/non-restorable tooth #4.
4/4/2016	5	fract--	Mobile #9 and #5-abfraction
4/4/2016	5	fract--	#5 - Class II mobility, large abfraction approximating pulp
4/5/2016	30	crack--	Cracked tooth #30
4/5/2016	30	fract--vertical	Severe TTP #30, ? vertical fracture.
4/5/2016	30	fract--vertical	Acute periapical periodontitis #30 likely from vertical fracture
4/5/2016	4	fract--root	Hard tissue exam #4 class 1 mobile, #9 and 10 defective F restoration, #23-26 class 1 mobility, #23-25 abfraction on root surfaces, evidence of bruxism on all teeth
4/5/2016	4	fract--	#4 fractured buccal cusp with pulp exposed.
4/5/2016	4	fract--	#4 buccal cusp fractured last week.
4/5/2016	5	fract--	-Fractured #5 and caries- Non-Restorable
4/6/2016	12	fract--	Teeth 4, 5, 12-15, 17, 30, 31, 32 fractured to gumline.
4/6/2016	12	fract--	Teeth 4, 5, 12-15, 17, 30, 31, 32 fractured to gumline.
4/6/2016	13	fract-amalgam-	#13-fractured amalgam restoration
4/6/2016	14	fract--	#14 and #15 fractured.
4/6/2016	14	fract--	#14 and #15 fractured, sensitive to percussion

Date	Tooth	Key-No-Yes	phrase
4/6/2016	15	fract--	Teeth 4, 5, 12-15, 17, 30, 31, 32 fractured to gumline.
4/6/2016	15	fract--	Teeth 4, 5, 12-15, 17, 30, 31, 32 fractured to gumline.
4/6/2016	15	fract--	#14 and #15 fractured.
4/6/2016	15	fract--	#14 and #15 fractured, sensitive to percussion
4/6/2016	18	fract--	Fractured, non-restorable tooth #18
4/6/2016	18	fract--	fractured tooth #18, periapical radiolucency
4/6/2016	18	fract--	Fractured tooth #18, tender to percussion
4/6/2016	18	crack--	68 yo F presents for evaluation for extraction and possible socket preservation of cracked tooth #18.
4/6/2016	30	fract--	Teeth 4, 5, 12-15, 17, 30, 31, 32 fractured to gumline.
4/6/2016	30	fract--	Teeth 4, 5, 12-15, 17, 30, 31, 32 fractured to gumline.
4/6/2016	31	fract--	Teeth 4, 5, 12-15, 17, 30, 31, 32 fractured to gumline.
4/6/2016	31	fract--	Teeth 4, 5, 12-15, 17, 30, 31, 32 fractured to gumline.
4/6/2016	31	fract-elevat-	EXT #31: Attempted elevator and forceps extraction, however tooth crown fractured down to gumline.
4/6/2016	4	fract--	Hand fracture surgery - 1994
4/6/2016	4	fract--	Teeth 4, 5, 12-15, 17, 30, 31, 32 fractured to gumline.
4/6/2016	4	fract--	Teeth 4, 5, 12-15, 17, 30, 31, 32 fractured to gumline.

Date	Tooth	Key-No-Yes	phrase
4/7/2016	13	fract--	#13 Fractured below gingiva
4/7/2016	13	fract--	-#13 fractured slight PARL and Caries
4/7/2016	13	fract--	- fractured #13 below gingiva
4/7/2016	13	crack--	#13 has been hurting for about a month and cracked, but cracked in half a few days ago.
4/7/2016	14	fract--	Dental History #14 fractured last summer
4/7/2016	14	fract--	#2 and #14 fractured with gross decay
4/7/2016	14	fract--	#14 fractured with gross decay
4/7/2016	19	fract--	grossly carious and fractured #19
4/7/2016	2	fract--	#2MOD caries excavation and evaluate for fracture
4/7/2016	2	fract--	Additional Narrative At next appt, patient will need endo consult #19 and #2MOD caries excavation and assess for fracture.
4/7/2016	2	fract--	During cleaning discovered large fracture/missing filling in #2 which will need to be extracted.
4/7/2016	2	fract--	Fractured ML cusp of #2
4/7/2016	2	fract--	fractured MO restoration #2
4/7/2016	2	fract--	Fractured and non-restorable #2
4/7/2016	21	fract--	Crown fracture #21
4/8/2016	15	fract--	Carious fracture of distal of crown #15
4/8/2016	15	fract--	Fractured crown #15
4/8/2016	15	fract--	Pt reports tooth (points to #15) fractured 3-4 weeks ago and he started having pain.
4/8/2016	19	fract--	Fractured crown #19

Date	Tooth	Key-No-Yes	phrase
4/8/2016	21	broke--	lmr to cxl all appts-per IA due to broken appts- DO NOT RSC/tma ae Per, pt can call in Nov when things settle down at work and we will revisit about her returning
4/8/2016	31	fract--	#31 - gross caries, fractured crown and non-restorable
4/8/2016	31	fx--	#31 - fx'd crown with gross caries
4/11/2016	18	fract--	Dental History #18 fractured approximately 3 months
4/11/2016	29	broke--	Grossly carious and broken down crown #6, #7, #29
4/11/2016	30	fract--	Fractured #30
4/12/2016	19	fract-forcep-root	Retained roots (fractured) #s 4, 10, 11, 19 extracted in a routine manner and all delivered with forceps.
4/12/2016	19	fract--root	- Retained roots (fractured) #s 4, 10, 11, 19
4/12/2016	19	fract--root	Retained roots (fractured) #s 4, 10, 11, 19
4/12/2016	3	fract--	O: #30 has large DO decay and tooth fractured.
4/12/2016	30	fract--	O: #30 has large DO decay and tooth fractured.
4/12/2016	30	crack--	A: Cracked tooth #30- DL cusp
4/12/2016	30	crack--	P: #30- crack removal, restore with composite and crown prep planned today.
4/12/2016	30	crack--	#30- became symptomatic 1 year ago, irreversible pulpitis, inability to attain profound anesthesia, crack visible on pulpal floor
4/12/2016	30	crack--	Dental: #30 cracked tooth
4/12/2016	30	crack--	#30- cracked tooth
4/12/2016	30	crack--	cracked tooth #30, pt elects to ext

Date	Tooth	Key-No-Yes	phrase
4/12/2016	31	fract-amalgam-	#31-amalgam fracture, gross caries
4/12/2016	4	fract-forcep-root	Retained roots (fractured) #s 4, 10, 11, 19 extracted in a routine manner and all delivered with forceps.
4/12/2016	4	fract--root	- Retained roots (fractured) #s 4, 10, 11, 19
4/12/2016	4	fract--root	Retained roots (fractured) #s 4, 10, 11, 19
4/12/2016	5	fract--root	Radiolucency #5 consistent with root fracture that Pt's DDS referred him to the school to be EXT, no other bony pathology seen
4/12/2016	5	fract--	and heart stent placement, DM II, HTN, fractured non-restorable #5
4/12/2016	5	fract--	fracture Lingual cusp on #5, #5 tender to percussion, generalized plaque and no other grossly decayed teeth
4/12/2016	5	fract--	Lingual cusp fracture irrestorable #5
4/13/2016	12	fract--	Tooth 12 fractured to gumline.
4/13/2016	12	fract--root	Previous RCT 12 fractured root tip.
4/13/2016	19	fract--	A: #19 crown fractured a
4/13/2016	19	fract-elevat-	-Elevated fractured #19 with osteotome series.
4/13/2016	19	broke--	Broken leg, 1996, no complications
4/13/2016	19	fract--	#18, 19, 30 fractured crowns,
4/13/2016	2	fract--	#2-symptomatic, fractured with caries
4/13/2016	2	fract--	#2-symptomatic, fracture
4/13/2016	2	fract--	#2-fractured crown with caries
4/14/2016	14	fract--root	Teeth extracted in multiple segments one root at a time after coronal segment of #14 fractured.
4/14/2016	29	fract--	Panorex reviewed - fractured #29

Date	Tooth	Key-No-Yes	phrase
4/14/2016	29	fract--	Fractured #29.
4/14/2016	29	fract--	Dental - Fractured #29, Suprarrupting #1, 16
4/15/2016	13	fract--	Additional Narrative Informed the patient that #13 prognosis is unfavorable due Class 3 mobility and possible fracture.
4/15/2016	13	fract-forcep-vertical	Ext and socket pres #13: Forceps ext #13, Of note it was vertically fractured.
4/15/2016	18	fract--	Rampant decay/fractured crown #1-16, 18,19,20,
4/15/2016	18	fract--	Dental - rampant decay/fractured crown #1~16, 18, 19, 20,
4/15/2016	18	fract--	Rampant decay/fractured teeth 1-16, 18, 19, 20
4/15/2016	18	fract--	#1, 15, 18 fractured crown w/ gross caries, nonrestorable
4/15/2016	18	fract--	#1, 15, 18 fractured crown
4/15/2016	19	broke--	Broken leg, fracutred pelvic, broken arm, broken ribs 1998,
4/15/2016	19	fract--	Rampant decay/fractured crown #1-16, 18,19,20,
4/15/2016	19	fract--	Dental - rampant decay/fractured crown #1~16, 18, 19, 20,
4/15/2016	19	fract--	Rampant decay/fractured teeth 1-16, 18, 19, 20
4/15/2016	20	fract--	fractured tooth #20 asymptomatic with retained buccal cusp.
4/15/2016	20	fract--	pt has fractured tooth #20 asymmptomatic.
4/15/2016	20	fract--	Rampant decay/fractured crown #1-16, 18,19,20,
4/15/2016	20	fract--	Dental - rampant decay/fractured crown #1~16, 18, 19, 20,
4/15/2016	20	fract--	Rampant decay/fractured teeth 1-16, 18, 19, 20

Date	Tooth	Key-No-Yes	phrase
4/15/2016	20	fract--	#20 grossly carious and fractured crown
4/15/2016	5	fract-partial-	Pt diagnosed with:Generalized severe chronic periodontitis (Refractory), secondary OT (#4,5,28,29,12,13,20,21), partial edentulism, nicotine stomatitis.
4/15/2016	5	crack--	Cracked tooth #5, facial swelling
4/15/2016	5	crack--	#5 cracked tooth, substantial facial swelling
4/15/2016	5	crack--	#5 cracked tooth
4/18/2016	14	fract--	Gross caries #14, Fractured #9
4/18/2016	14	fract--	Asthma, Fractured #14
4/18/2016	3	fract--	PPTC with grossly carious and fractured #3.
4/18/2016	3	fract--	Fractured/unrestorable #3
4/18/2016	3	fract--	Grossly decayed and fractured #3
4/18/2016	30	fract-forcep-	Attempted forceps extraction of tooth #30 and crown fractured.
4/18/2016	4	broke--	Broken off 10 months, been bothering him for 3-4 days.
4/18/2016	4	fract--	Tooth #4 Fractured clinical crown to gum line w/ existing post present
4/18/2016	4	fract--	Fractured tooth #4 w/ previously NSRCT and post
4/18/2016	4	fract--	Dental: Fractured tooth #4 (deemed non-restorable) w/ pre-existing metal post
4/19/2016	18	fract--	#18-gross caries and fractured crown, nonrestorable
4/19/2016	19	crack--	Recommended treatment Recommended extraction of tooth #19 due to likely presence of

Date	Tooth	Key-No-Yes	phrase
			crack/fracture, Discussed Risks/Benefits of Tx Options, Prognosis, and Financial Obligation.
4/19/2016	19	fract--	- Informed patient of all clinical findings, including previous chart note of incomplete endo of #19 due to fracture.
4/19/2016	19	fract--vertical	Dental - Vertical root fracture #19 - will require extraction.
4/19/2016	19	fract--	#19 fractured/carious
4/19/2016	19	fract--	#19 fractured one month ago, pain began a week ago.
4/19/2016	19	fract--	Fractured #19 at gumline, not sensitive to palpation or percussion
4/19/2016	19	fract--	Gross caries #19, fractured #18, tender to percussion #19, discoloration on #8 PA area from RCT
4/19/2016	2	fract-amalgam-	defective #2 amalgam restoration with sensitivity, fractured #15 amalgam
4/19/2016	20	fract--	Fractured #20
4/19/2016	20	fract--	Fractured #20 sensitive to percussion
4/19/2016	20	fract--	Fractured/gross caries #20
4/19/2016	31	fract--	Fractured/carious #31, pt elected to ext
4/19/2016	31	fract--	Fractured #31 with slight PARL
4/19/2016	31	fract--	Fractured #31, #3-B caries
4/19/2016	4	fract--	Fractured #4
4/19/2016	4	fract--	PPTC with fractured #4.
4/19/2016	4	fract--	Fractured #4 Buccal lingually

Date	Tooth	Key-No-Yes	phrase
4/20/2016	12	fract--	- Fractured crowns #'s 7, 10, 11, and 12
4/20/2016	30	fract--	Fractured and carious #30
4/20/2016	30	fract--root	Fractured and carious #30 with widened PARL around mesial and distal roots
4/20/2016	30	broke--	Pt reports constant worsening throbbing pain associated with broken tooth #30 x 3 days.
4/20/2016	31	fract--	#31 sensitive to percussion- mesial fracture osseous level- pt elects for EXT
4/21/2016	19	fract--	Gross caries/fractured restoration #19
4/21/2016	19	fract--	#19 fractured 1 week ago, pain has worsened last 3 days.
4/21/2016	31	fract--	#31-fractured
4/22/2016	18	fract--	Both #18 and 19 appeared to have fractured lingua
4/22/2016	18	fx-amalgam-	#18 with fx amalgam
4/22/2016	18	fract-amalgam-	A:#18 disto lingual cusp fractured to the gingiva with secondary caries underneath amalgam restoration
4/22/2016	18	fract--	Patient was noted to have fractured #18 at his last appointment, and endo testing revealed necrotic pulp.
4/22/2016	18	fract--root	#18-fractured crown, retained root tips
4/22/2016	18	fract--	#18-fractured crown, nonrestorable
4/22/2016	19	fract--	#19 previous NSRCT - fractured and nonrestorable.
4/22/2016	19	fract--	#19 previous NSRCT - fractured
4/22/2016	19	fract--	#19 fractured

Date	Tooth	Key-No-Yes	phrase
4/22/2016	19	fract--	#19 fractured while eating a few days ago.
4/22/2016	28	fract--	Grossly carious/fractured #3, 12, 28, 32.
4/25/2016	20	vrf--	healing sinus tract on #20, VRF
4/25/2016	29	fract--root	#29 fractured to gingiva with resin on top of root structure
4/25/2016	30	fract--	Caries #30 - endo treated with fractured crown
4/25/2016	30	fract--	Fractured crown on endo treated tooth #30
4/25/2016	30	fract--	Caries #30 - fractured crown, previously endo treated
4/25/2016	4	fract--	#4- fractured
4/26/2016	13	fract--	patient presented to clinic with pain on 13 and crown fracture for 29
4/26/2016	14	broke--	56 y/o female PTC for broken teeth #14 and #15 for about 1 mo.
4/26/2016	15	broke--	56 y/o female PTC for broken teeth #14 and #15 for about 1 mo.
4/26/2016	15	fract--	#15- fractured at gumline
4/26/2016	18	broke--	Broken down crown #18, significant bone loss, mobility
4/26/2016	28	fract--	Gross decay , fractured 27, 28 secondary decay #2 restored with a crown.
4/26/2016	29	fract--	patient presented to clinic with pain on 13 and crown fracture for 29
4/26/2016	30	fract--	#30-fractured with caries
4/26/2016	30	fract--	#30-fractured crown with caries
4/27/2016	15	fract--	#15-fractured below gumline, percussion sensitive

Date	Tooth	Key-No-Yes	phrase
4/27/2016	15	fract--	PPTC with constant pain in UL (points to #15), began 1 year ago when tooth fractured and has been increasing in severity.
4/27/2016	19	fx-forcep-	Patient locally anesthetized with aforementioned LA and tooth #19 extracted in a surgical manner after coronal aspect fx'd during delivery w/forceps.
4/27/2016	19	fx--	55 YO healthy F PTC as a referral from endo for the ext of carious/fx'd/non-restorable tooth #19.
4/27/2016	4	broke--	#14-broken at gumline
4/27/2016	4	broke--	#14-broken at gumline- will need future ext
4/28/2016	19	fract--	S: PPTC for fractured #19
4/28/2016	19	fract--	A: Pt's #19 PFM fractured off with some underlying tooth structure.
4/28/2016	3	fract--	- Fractured teeth #s 3, 5, 10
4/28/2016	3	fract--	Fractured teeth #s 3, 5, 10, 27
4/28/2016	5	fract--	- Fractured teeth #s 3, 5, 10
4/28/2016	5	fract--	Ulceration (~0.5 cm) on R anterior lateral surface of tongue, and smaller (~2 mm) ulceration on R dorsal surface of tongue - appears to be 2/2 trauma from fractured teeth
4/28/2016	5	fract--	Fractured teeth #s 3, 5, 10, 27
4/29/2016	2	fract--	Rampant decay/fractured crown #1-16, 18,19,20,
4/29/2016	2	fract--	Dental - rampant decay/fractured crown #1~16, 18, 19, 20,
4/29/2016	2	fract--	Rampant decay/fractured teeth 1-16, 18, 19, 20
4/29/2016	29	fract--	necrotic/fractured teeth #29 and 30
4/29/2016	30	fract--	necrotic/fractured teeth #29 and 30

Date	Tooth	Key-No-Yes	phrase
5/2/2016	14	fract--	fractured, decayed tooth #14
5/2/2016	14	fract--	non-restorable, fractured tooth #14
5/2/2016	19	fract--	#19 is fractured, percussion positive with chronic apical periodontitis
5/2/2016	2	fract--	Grossly carious #2, fractured 9, 10.
5/2/2016	2	fract--	Dental - Grossly carious/fractured #2, 9, 10
5/3/2016	12	fract--root	A: #12 fractured PFM from root, existing RCT that was performed through the crown.
5/3/2016	13	fract--	crown Fracture: @ #5, 13, 19, 29, 30
5/3/2016	14	broke--	spacer 14 area broken and needs appt to fix.
5/3/2016	19	fract--	#19 fractured DL cusp, with PARL.
5/3/2016	19	fract--root	#20 has a short clinical root and a fracture line on the root, it will be re-accessed after extracting #19.
5/4/2016	12	fract-elevat-	Attempted elevator and forceps extraction of tooth #12, however tooth crown fractured off.
5/4/2016	15	fract--	15 - caries/fracture, percussion sensitive
5/4/2016	15	fract--	15 - caries/fracture
5/4/2016	2	broke--	Number 2 broke 5 weeks ago and a temporary filling was placed in Chile.
5/4/2016	2	fract--	#2-fracture
5/4/2016	2	fract--	2 - carious with fractured crown sensitive to percussion
5/4/2016	2	fract--	2 - decay and fracture sensitive to percussion
5/4/2016	2	fract--	2 - carious with fractured crown
5/4/2016	20	broke--	2009 broken right arm screw retained.
5/4/2016	3	fract--	#3 fractured

Date	Tooth	Key-No-Yes	phrase
5/5/2016	12	broke--	symptomatic, broke down 12 elect for EXT
5/5/2016	15	fx--	-GCNR tooth #15 fx'd to osseous level with decay to pulp and MB PAP
5/5/2016	15	fx--	A small FTMP envelope flap was raised @ tooth #15 following fx of the crown.
5/5/2016	29	fract--vertical	Vertical Root Fracture #29 L
5/5/2016	5	fract--	A: Fractured #12, Grossly carious #15, Leukoplakia on lateral border of the tongue, Defective margin on #30, Cavitated les
5/5/2016	5	fract--	tooth 5 fractured
5/5/2016	5	fract--	A: Fractured #5, localized gingivitis with plaque and calculus, decalcification #8-ML and #9-ML
5/6/2016	20	fract--	Gross decay and fractured #17, 20, 30, 32.
5/6/2016	20	fract--	Gross decay and fractured teeth #17, 20, 32, 30.
5/6/2016	30	fract--	Gross decay and fractured #17, 20, 30, 32.
5/6/2016	30	fract--	Gross decay and fractured teeth #17, 20, 32, 30.
5/6/2016	31	fract-amalgam-	TX: Clinical evaluation of patient's chief complaint revealed fractured ML cusp #31 with existing large occlusal amalgam.
5/9/2016	12	fract-deliver-root	tooth #12- buccal root fractured off, luxated buccally with cogswell, root tip pushed buccally, 15 blade used to make stab incision, root tip delivered.
5/9/2016	12	broke--	S: PPTC for recall and broken tooth #12.
5/9/2016	12	fract--root	Fractured retained root tip at site #12
5/9/2016	12	fract--	#12- grossly carious, fractured to gingival margin
5/9/2016	19	fract--	small fracture noted in buccal of tooth #19 with small carious lesion

Date	Tooth	Key-No-Yes	phrase
5/9/2016	19	fract--	tooth #19 fractured last week and been causing severe pain.
5/9/2016	2	broke--	#2 broke about a week ago
5/9/2016	2	fract--	2x5 ulcer buccal to fractured #2
5/9/2016	5	fract-deliver-root	tooth #12- buccal root fractured off, luxated buccally with cogswell, root tip pushed buccally, 15 blade used to make stab incision, root tip delivered.
5/10/2016	2	fract--	Tooth #2 fractured several weeks ago, and has been causing pt severe pain since Friday 5/6.
5/11/2016	3	fract-amalgam-	Grossly carious and fractured tooth #3, missing MO amalgam
5/11/2016	3	fract--	Grossly decayed and fractured tooth #3
5/11/2016	4	fract--	Dental: Fractured, non-restorable #4
5/11/2016	4	fract--	Fractured #4
5/12/2016	5	fract--	Generalized severe bone loss with multiple grossly carious and fractured remaining maxillary and mandibular teeth (#s 1-16, 17-25, 27-32)
5/13/2016	12	fx--	fx #12, chipped incisors.
5/13/2016	3	fract--	#3 fractured ML cusp
5/13/2016	31	fx--	fx #31
5/13/2016	31	fx--	fx and nonrestorable #31
5/17/2016	15	fract--	Diagnosis: Generalized mild with localized severe chronic periodontitis, Fractured #15, Lack of KT
5/17/2016	20	broke--	MD Hx: Aortic aneurysm, Environmental allergies, GERD, Sx: Gallbladder removal 2012, broken disc removed 2006, no complications.

Date	Tooth	Key-No-Yes	phrase
5/18/2016	15	fract--	Tooth #15-->GCNR with buccal carious fracture down to osseous level-->PDL expansion
5/18/2016	28	fract--	#27, #28 fractured and carious.
5/18/2016	28	fract--	#27, #28 fractured and carious with PAP
5/18/2016	28	fract--	#27, 28 fractured and carious.
5/19/2016	30	fract-porcelain-	PFM Crown #30 has fractured porcelain and questionable margin at distal
5/19/2016	4	fract--root	45 yo F w/ controlled HTN with fractured and root canal treated tooth #4
5/20/2016	18	fract--	#18 fractured, RCT, gross caries
5/20/2016	18	fract--	#18 fractured, gross caries
5/20/2016	18	fract--	#18 fractured tooth
5/20/2016	28	fract--	#28 - fractured crown
5/20/2016	28	fract--	#28 - grossly carious, fractured crown
5/20/2016	30	fract--	#30 fractured, RCT, gross caries
5/20/2016	30	fract--	#30 fractured, gross caries
5/20/2016	30	fract--	#30 fractured tooth
5/23/2016	19	fx--	No evident mobile fx'd segment on tooth #19
5/23/2016	2	fract--	Fractured tooth #2, mesial cusp
5/23/2016	2	fract--	Fractured cusp on mesial of #2
5/23/2016	2	fract--	Fractured mesial cusp on #2
5/23/2016	29	fract--	#29 fractured, patient elects to extract
5/23/2016	29	fract--	#29 fractured right above the gum line
5/23/2016	29	fract--	#29 fractured just above the gumline- patient elects to extract the tooth today

Date	Tooth	Key-No-Yes	phrase
5/23/2016	29	fract--	#29 has been fractured since January and has bothered the patient since
5/23/2016	30	broke--	Broken 30/grossly carious #31
5/23/2016	30	fract--	Lingual cusps fractured off #30
5/23/2016	31	broke--	Broken 30/grossly carious #31
5/23/2016	5	fract--	O: BP-128/78, HR-68-reg, Med Hx no changes, Ill(-), Hosp(-), All(-), Class 2 mobility on #4, 5, #29 buccal cusp fractured off, Widened PDL on #4,5 on PA.
5/23/2016	5	fract--	A: Very heavy occlusion on #4, 5, and 29 leading to fremitus and class II mobility of #4, 5 and the fracture of the buccal cusp on 29.
5/24/2016	12	fract--root	root fractured on teeth #5 and 12.
5/24/2016	18	fract--	Informed patient of risks including possible fracture of #19 during extraction of #18.
5/24/2016	19	fract--	#19 grossly carious fractured.
5/24/2016	19	fract--	#19 distal gross decay and coronal fracture, multiple dental restorations, stable occlusion
5/24/2016	5	fract--root	root fractured on teeth #5 and 12.
5/25/2016	13	fx--	Grossly fx'd/carious/periodontally-involved tooth #13 w/ associated large perio defect/CAL and bone loss at the distal.
5/25/2016	13	fx--	Grossly fx'd/carious/periodontally-involved tooth #13
5/25/2016	13	fract--	tooth 13 has a distal fracture and is carious.
5/25/2016	14	broke--	Broken #14
5/25/2016	18	fx-amalgam-	Upon examination #18 MODB amalgam fx B portion of restoration.

Date	Tooth	Key-No-Yes	phrase
5/25/2016	3	fract--	1993: Orbital rim fracture and nasal cavity reconstruction
5/26/2016	12	fract--	#12 fractured w/PAP
5/26/2016	12	fract--	#12 fractured 5 months ago and was painful at the time when eating or drinking but stopped hurting after a while and kept fracturing into small segments then the pain stopped after a while.
5/26/2016	12	fract--	#12 fractured DB cusp
5/26/2016	12	fract--	Dent - #12 fractured cusp - nonrestorable.
5/26/2016	20	fract--	#20 Fractured
5/26/2016	30	fract--	distal cusp fracture on tooth 30.
5/27/2016	18	fract--	#18- distal cusp fracture
5/27/2016	2	fract--	#2 - fractured crown
5/27/2016	2	fract--	#1 - interradicular pathosis, #2 fractur
5/27/2016	2	fract--	#2 fractured crown
5/27/2016	20	fract-amalgam-	Tooth #20 has MO amalgam with fractures on the distal marginal ridge.
5/27/2016	30	fract--	Dent - #5, #30 caries/fractured - nonrestorable
5/27/2016	30	fract--	#5, #30 caries/fractured
5/27/2016	31	broke--	O: broken crown on #31 and #4.
5/27/2016	5	fract--	Dent - #5, #30 caries/fractured - nonrestorable
5/27/2016	5	fract--	#5, #30 caries/fractured
5/31/2016	13	crack--	Hard tissue exam #4 cracked lingual cusp, #6 marginal staining, #11 L caries, 13 O caries, 14 O caries, #24 M caries
5/31/2016	13	fract--	Fractured cusps 4,13

Date	Tooth	Key-No-Yes	phrase
5/31/2016	13	fract--root	Grossly carious/fractured #13 (retained roots)
5/31/2016	14	crack--	Hard tissue exam #4 cracked lingual cusp, #6 marginal staining, #11 L caries, 13 O caries, 14 O caries, #24 M caries
5/31/2016	14	fract--root	#1 carious fractured with root tips,#2 occlusal carious, #3 M caries, #12,13,14 fractured with root tips, #15 M caries, #16 root tips, #17 missing, #18 O caries, #19 missing, #30-32 missing.
5/31/2016	18	fract--root	#1 carious fractured with root tips,#2 occlusal carious, #3 M caries, #12,13,14 fractured with root tips, #15 M caries, #16 root tips, #17 missing, #18 O caries, #19 missing, #30-32 missing.
5/31/2016	18	fx--vertical	Vertical fx #18
5/31/2016	19	fract--	Grossly carious and fractured #19 nonrestorable.
5/31/2016	28	broke--	#28 broken to gums
5/31/2016	4	fract--	Fractured cusps 4,13
5/31/2016	4	fract--root	Grossly carious/fractured #4 (retained roots)
5/31/2016	5	fract--	Fractured #5- Ext
5/31/2016	5	fract--	Fractured #5
5/31/2016	5	fract--root	Carious fractured #5 and root remnant #19.
5/31/2016	5	fract--root	Carious, fractured #5/root remnants endo tx #19.
5/31/2016	5	fract--	Dental: carious/fractured #5/#19 non restorable
5/31/2016	5	fract--	Carious and fractured #5
6/1/2016	12	fract--horizontal	Horizontal crown fracture at the bottom of prep #12 detected.

Date	Tooth	Key-No-Yes	phrase
6/1/2016	12	split--root	Dental:root fractured tooth #12 split in half ,#12 tooth non restorable
6/1/2016	12	fract--root	fractured root tooth #12 parulus
6/1/2016	12	fract--	evident Fractured #12 bellow gingiva , the 2 segments are mobile,no pain upon palpation and percussion
6/1/2016	12	broke--	I have a broken tooth pointing to #12
6/1/2016	13	fract--	Mandibular tori, Ligual cusp of #13 fractured
6/1/2016	13	fract--	Fractured lingual cusp on #13
6/1/2016	13	fract--	Fractured cusp on the lingual of #13
6/1/2016	13	fract--	Ext fractured #13-
6/1/2016	13	broke--	Throbbing pain in #13 with broken lingual cusp.
6/1/2016	14	fract--	fracture #14
6/1/2016	14	fract--	#14 carious fracture,
6/1/2016	14	fract--	#14 carious fractured crown
6/1/2016	14	fract--	carious, fractured #14, not periapical pathology noticed
6/1/2016	29	fract--	#29 fractured a few weeks ago.
6/1/2016	29	fract--	#29 fractured
6/1/2016	29	fract--	#29 fractured, PAP
6/1/2016	29	fract--	#29 fractured, nonrestorable
6/2/2016	12	fx--	UL tooth #12 fx'd ~ 2 days ago.
6/2/2016	12	fract--	Fractured #12 at the gumline
6/2/2016	12	fract--	Fractured #12 to osseous level.

Date	Tooth	Key-No-Yes	phrase
6/2/2016	12	fract--	Fractured #12 asymptomatic, nonrestorable, patient wants tooth extracted
6/2/2016	12	fx--	Fractured #12-->fx'd to osseous level/non-restorable
6/2/2016	12	broke--	#12 broke off two months ago.
6/2/2016	12	fract--	#12 fractured to gingiva - non-restorable
6/2/2016	14	fract--	Fractured 8, 9, Class II mobile #14, 15.
6/2/2016	15	fract--	Fractured 8, 9, Class II mobile #14, 15.
6/2/2016	3	fract--	Abfractions #13, 14, 18, 19, 20.
6/2/2016	3	fract--	Abfractions on facial surfaces of #13, 18, 19, 20, 30.
6/2/2016	3	fract--	PRTC for restoration of abfractions on #13 and 30.
6/2/2016	31	crack--	S: pptc for ext of #31 (cracked tooth, determined by Grad Endo)
6/2/2016	31	crack--	A: Cracked tooth #31, poor prognosis
6/2/2016	31	fx--vertical	#31 vertical root fx.
6/3/2016	15	fract--	fractured crown and non restorable tooth #15 and #20
6/3/2016	15	fract--	RCT #4,#15,#20,#19 , #15 and #20 crown fractured off.
6/3/2016	15	fract--	#15 and #20 had RCT when in Feb and March 2016 they fractured off.
6/3/2016	2	fract--	PPTC with fractured #2.
6/3/2016	2	broke--	Reports tooth broke approx 2 mo ago.
6/3/2016	2	fract--	#2 - fractured, grossly decayed

Date	Tooth	Key-No-Yes	phrase
6/3/2016	20	fract--	fractured crown and non restorable tooth #15 and #20
6/3/2016	20	fract--	RCT #4,#15,#20,#19 , #15 and #20 crown fractured off.
6/3/2016	20	fract--	#15 and #20 had RCT when in Feb and March 2016 they fractured off.
6/3/2016	29	fract--	#29 Caries and fractur
6/6/2016	30	crack--	#30 cracked tooth
6/6/2016	4	fract--	Cariou/Fractured #4, 5, 7, 8, 9, 10
6/6/2016	5	fract--	Cariou/Fractured #4, 5, 7, 8, 9, 10
6/7/2016	14	fract--	A: #2, 4 and 14 are previous NSRCT and fractured, non-restorable.
6/7/2016	14	fract--	Fractured #2, 4, 14
6/7/2016	15	fract--	- Grossly carious/fractured #15
6/7/2016	15	fract--	#15 MO fracture to pulp.
6/7/2016	15	fract--	Fractured #15 MO to gingiva.
6/7/2016	15	fract--	Fractured restoration #15 MO
6/7/2016	18	fract--	Nonrestorable, carious, fractured #18
6/7/2016	18	fract--	fractured mesial cusp #18
6/7/2016	19	fract--	#19 is grossly decayed, fractured crown at the gingiva.
6/7/2016	2	fract--	A: #2, 4 and 14 are previous NSRCT and fractured, non-restorable.
6/7/2016	2	fract--	Fractured #2, 4, 14
6/7/2016	30	broke-elevat-root	#30 crown broke at CEJ, retrieved and the roots delivered with elevator, bone file used for any sharp margins

Date	Tooth	Key-No-Yes	phrase
6/7/2016	31	fract--	Grossly carious/fractured #31
6/7/2016	31	fract--	- Grossly carious/fractured #31
6/7/2016	4	fract--	A: #2, 4 and 14 are previous NSRCT and fractured, non-restorable.
6/7/2016	4	fract--	Fractured #2, 4, 14
6/9/2016	14	broke--	extraction of tooth #14- tooth badly broken down.
6/9/2016	2	fract--	#4- crown fractured off 2 weeks ago
6/9/2016	2	broke--	broken filling #2/ gross caries, tenderness to percussion , fracture cusp tooth #32, 16 distal caries, 17 gross caries
6/9/2016	2	fract--	#32 fracture cusp, #16 distal caries
6/9/2016	3	fract--	#3 fractured MB cusp
6/9/2016	3	fract--	#3 fractured MB cusp with spontaneous throbbing pain
6/9/2016	3	fx--	Patient with pain hx starting immediately after Ellis Class II fx of tooth #3.
6/9/2016	3	broke-elevat-root	#30 amalgam broke down, sectioned tooth through furcation, elevated D root.
6/9/2016	3	fract--	fractured #3
6/9/2016	3	fract--	carious, fractured #3
6/9/2016	3	fract--	tooth #3- fractured to gum line
6/9/2016	3	fract--	Fractured #3 DL cusp
6/9/2016	3	fract--	Fractured #3 DL cusp/CARIOUS/non-restorable
6/9/2016	3	fract--	Fractured #3
6/9/2016	4	fract--	Caries and fractured crown- #4

Date	Tooth	Key-No-Yes	phrase
6/9/2016	4	fract--	Fractured crown and caries- #4
6/9/2016	4	fract--	caries and fracture crown- #4
6/9/2016	4	fract--	#4- crown fractured off 2 weeks ago
6/9/2016	4	fract--	fractured #4
6/9/2016	4	fract--	#4 grossly decayed/fractured
6/9/2016	4	broke--	PPTC with fractured #4, reports that tooth broke on saturday.
6/9/2016	5	broke--	Broken crown #5,12
6/9/2016	5	fract--	fractured crown #5, non-restorable
6/9/2016	5	fract--	fractured crown #5
6/10/2016	12	fract--	Radiographic caries D #4, D#10, #12 Lingual cusp fracture, Bilateral Mn tori
6/10/2016	12	fract--	#12 Lingual cusp fracture, Bilateral Mn tori
6/10/2016	18	fract--	#18 fractured (very sensitive to percussion, normal response to palpation)
6/10/2016	18	fract--	#18 fractured
6/10/2016	18	fract--	#18 grossly carious and fractured off
6/10/2016	28	fract--	#28-fractured with caries, percussion sensitive
6/10/2016	28	fract--	Caries extending into the pulp of #28 - fractured crown
6/10/2016	3	fract--	#3 fractured crown
6/10/2016	3	fract--	A: #3 fractured crown , non-restorable.
6/10/2016	30	broke--	Tooth #30 broke few months ago but it was not painful.

Date	Tooth	Key-No-Yes	phrase
6/10/2016	30	broke--	Tooth broke second time on 5/30, very sensitive when she biting, drink cold water and when expose to air.
6/10/2016	30	broke--	My tooth broke & hurts a lot,(#30)
6/10/2016	30	broke--	#30 gross caries/ broken tooth
6/10/2016	30	broke--	Dental: #30 broken tooth/ gross caries
6/10/2016	30	broke--	#30 broken tooth/ gross caries
6/13/2016	18	fract-forcep-	#17 and 18 Forceps seated crown fractured off.
6/13/2016	2	fract--	Pt presents with Fractured lingual cusl on PFM crown #12
6/13/2016	2	fract--	tooth 2 fractured and has hopeless px.
6/13/2016	5	fract--	#5 acute, sensitivity to percussion, possible M-D fracture
6/13/2016	5	fract--	EXT #5 due to mesial-distal fracture, severe periodontal disease, sensitivity to percussion
6/13/2016	5	fract--	#5 mesial-distal fracture, severe perio
6/14/2016	14	broke--root	Root tips broke off upon Ext of #14.
6/14/2016	19	fract--	Fractured distal cusps on #19
6/14/2016	5	fract--	Fractured #1, 5, 29
6/15/2016	13	fract--	Car accident April 2013, pt admitted to hospital, for jaws fracture constructed surgically withTitanium
6/15/2016	14	fract--	#14 - decay and fractured crown
6/15/2016	14	fract--	fractured ML and DL of #14
6/15/2016	30	fract--root	#18, 19, 29, 30 - crowns fractured off/only root tips remaining with PARLs

Date	Tooth	Key-No-Yes	phrase
6/16/2016	21	fract--	Hard tissue exam (Findings) Dental exam performed by Dr, he said #21 needs extracted due to being fractured in half.
6/16/2016	21	broke--	#21 is broken and mobile.
6/16/2016	21	broke--	#21 is broken.
6/16/2016	21	fract--	Fractured, gross decay #21
6/16/2016	21	fract--	Fractured #21
6/16/2016	30	fx--	Gross caries #30 with DO fx to osseous level-->PDL expansion,
6/16/2016	30	fx--	Gross caries #30 with DO fx to osseous level-->PDL expansion
6/16/2016	30	fract--	#30- fractured and decay on distal, will probably need NSRCT and crown lengthening to restore
6/16/2016	31	fract-amalgam-	patient has recurrent decay beneath an existing amalgam on #31, tooth fractured as a result, causing an ulcer on the right lateral tongue
6/16/2016	31	fract--	Fractured #31, psychiatric issues
6/16/2016	31	fract--	Fractured tooth #31, generalized caries
6/16/2016	31	fract--	X-rays indicated that #31 was fracture due to recurrent caries into the pulp and was in need of extraction.
6/16/2016	4	fract--	Grossly fractured/carious 2, 4-11, 22-27
6/16/2016	4	fract--	Grossly fractured/carious 4-11, 22-27
6/17/2016	2	fract--	#3, #19, #32 coronal fracture, rampant decay throughout
6/17/2016	2	fract--	#2 & #3 coronal fracture and grossly carious
6/17/2016	2	fract--	#32 coronal fracture

Date	Tooth	Key-No-Yes	phrase
6/20/2016	12	fract--	Gross caries/fractured teeth #4, #12.
6/20/2016	12	fract--	Fractured #4, #12
6/20/2016	13	fract--	PPTC (grad perio) for extraction and implant for fractured #13.
6/20/2016	14	broke--	#14- gross decay and broken crown.
6/20/2016	14	broke--	#14- gross decay and broken crown
6/20/2016	14	broke--	#14 has a broken crown and gross decay.
6/20/2016	18	fract--	#18, #19 - fractured and carious, nonres
6/20/2016	18	fract--	- Grossly carious #s 18 and 19 (fractured crown)
6/20/2016	18	fract--	#18 - grossly carious/fractured
6/20/2016	18	fract--	#18 - grossly carious/fractured, possible PA pathosis
6/20/2016	18	fract--	PPTC with fractured #18.
6/20/2016	19	fract--	#18, #19 - fractured and carious, nonres
6/20/2016	19	fract--	- Grossly carious #s 18 and 19 (fractured crown)
6/20/2016	19	fract--	Grossly carious/fractured crown #19
6/20/2016	19	fract--	- Grossly carious/fractured crown #19
6/20/2016	19	fract--	#19 fractured DMR
6/20/2016	19	fract--	fractured DMR and PAP #19
6/20/2016	29	fract--	#29 fractured crown
6/20/2016	29	fract--	fractured #29
6/20/2016	4	fract--root	fractured #14 with Retained root tips
6/20/2016	4	fract--	#4 - fractured and grossly decayed
6/20/2016	4	fract--	Gross caries/fractured teeth #4, #12.

Date	Tooth	Key-No-Yes	phrase
6/20/2016	4	fract--	Fractured #4, #12
6/21/2016	13	fract--	Previously RCT'ed and grossly fractured #13
6/21/2016	13	fract--	Grossly fractured/decayed #13
6/21/2016	13	fract--root	Surgical EXT fractured root #13:
6/21/2016	15	fract--	#15 crown fractured off
6/21/2016	15	broke--	#15 crown broke off/carious
6/21/2016	15	broke--	#15 crown broke off and is carious, non restorable.
6/21/2016	18	fract--	#18 - fractured and sensitive to palpation
6/21/2016	18	fract--	#18 - fractured crown
6/21/2016	18	fract--	#18 - fractured and sensit
6/21/2016	19	fract--	Gross caries and crown fracture #19, #30.
6/21/2016	19	fract--	Gorss caries and crown fracture #19, #30
6/21/2016	19	fract--	#19 and 30 fractured DMR
6/21/2016	19	fract--	#19 and #30 carious fracture
6/21/2016	19	fract--	#19 and #30 distal decay and fracture crown
6/21/2016	29	broke--	#29 recently broke off this week.
6/21/2016	30	fract--	Gross caries and crown fracture #19, #30.
6/21/2016	30	fract--	Gorss caries and crown fracture #19, #30
6/21/2016	30	fract--	#19 and 30 fractured DMR
6/21/2016	30	fract--	#19 and #30 carious fracture
6/21/2016	30	fract--	#19 and #30 distal decay and fracture crown
6/22/2016	12	broke--	O: Bp: 125/80 Hr: 72reg #6 Abutment crown and #5 pontic of FPD spanning from #2 to #6 has broken off.

Date	Tooth	Key-No-Yes	phrase
6/22/2016	12	fract--	P: Informed pt that #14 will need to be extracted due to the fracture, #13 and 14 will be sectioned off, and will assess whether #12 is restorable.
6/22/2016	14	fract--vertical	Radiographically, #14 has hemisected root with vertical fracture.
6/22/2016	14	fract--	P: Informed pt that #14 will need to be extracted due to the fracture, #13 and 14 will be sectioned off, and will assess whether #12 is restorable.
6/22/2016	3	fract--	edentulous mandible with 3 mini-implants (1 fractured)
6/22/2016	4	fract--	Tooth #4 is fractured on lingual and p
6/23/2016	18	fract--	#18 Fractured
6/23/2016	18	fract--	Fractured #10, and #18
6/23/2016	18	fract--	#18 fractured with vestibular swelling
6/23/2016	30	fract--	fractured Distal Marginal Ridge #30
6/23/2016	4	broke--	O: broken crown on #31 and #4.
6/24/2016	15	fract--	Fractured #1, 15, 16, 17, 18, 32
6/24/2016	19	fract--	Fractured questionable restorable teeth #19 and 20 with lingual cusps that are loose and fractured well below gum line.
6/24/2016	19	fract--	Outside PA, Bite wings and Pano reviewed and show fractured #19 and 20.
6/24/2016	19	fract--	The remainder of the distolingual cusp on #19 was fractured off below the crest of bone with pulp involvement and the mesiolingual cusp of 19 w
6/24/2016	20	fract--	Fractured questionable restorable teeth #19 and 20 with lingual cusps that are loose and fractured well below gum line.

Date	Tooth	Key-No-Yes	phrase
6/24/2016	20	fract--	Outside PA, Bite wings and Pano reviewed and show fractured #19 and 20.
6/24/2016	30	fract--	dental: #30 fracture and caries, #31, 2 caries
6/24/2016	30	fract--root	Fractured distal root #30 - pl
6/24/2016	30	fract--root	Fractured distal root #30
6/24/2016	4	broke--	P: Administed 1 carpule of 4 percent septo infiltration on 11, removed provisional which broke off.
6/24/2016	4	fract--	Today the core retained within the crown is fractured from the post and #4 is non-restorable.
6/27/2016	12	fract--	#12, #30 fractured/carious
6/27/2016	13	fract--	HPI: Pt referred from Pre-Doc to AEGD for evaluation of fractured #11 and #13.
6/27/2016	13	fract--	#13 - fractured crown previously endo treated
6/27/2016	13	fract-partial-	Dental History #13 crown fractured 3 months ago and partial denture no longer fits
6/27/2016	13	fract--	Failed crown #13 with fracture and decay
6/27/2016	13	fract--	Failed crown and fractured #13
6/27/2016	13	broke--	Crown #13 broke 2 weeks ago.
6/27/2016	18	broke--	-#18 broken MB cusp
6/27/2016	19	fract--	#19 fractured
6/27/2016	19	fract--	#19 fractured, possible PA pathosis
6/27/2016	19	fract-elevat-root	#19 crown and mesial root fractured from distal root, elevated and delivered with forceps.
6/27/2016	3	fract--	Fracture/ gross decay #3, sensitive to percussion
6/27/2016	30	broke--	Patient reported today with broken tooth #30.

Date	Tooth	Key-No-Yes	phrase
6/27/2016	30	fract--	#12, #30 fractured/carious
6/28/2016	18	fract-elevat-	Attempted elevator and forceps extraction of tooth #18, however crown fractured off.
6/28/2016	19	broke--root	Crown of #19 recently broke off, mucosa has begun to grow over retained roots
6/28/2016	19	fract--root	#19 fracture, gross decay, RL on apex of D root 4x3mm .
6/28/2016	19	fract--root	#19- gross caries, fractured crow, RL 4x3mm on apex of D root
6/28/2016	19	fract--	Gross decay/fracture, PAP #19
6/28/2016	19	fract--	Gross decay/fracture present #19
6/28/2016	2	broke--	plan to ext #20 and gain attachment on #18 after broken bridge is removed.
6/28/2016	2	fract--	#20 fractured at cervical margin.
6/28/2016	2	broke--	Broken Leg 2000, lingering pain, no other complications
6/28/2016	28	fract--vertical	Non-restorable #28 due to vertical root fracture
6/28/2016	28	fract--vertical	58 F presents with J shaped radiolucency around the apex of #28 indicative of vertical root fracture.
6/28/2016	3	split--	#3 has split into 3 sections with decay present
6/28/2016	3	crack--	#3 cracked
6/28/2016	3	crack--	PPTC for EXT #3 cracked tooth.
6/29/2016	13	fract--	- Remaining maxillary teeth: #s 9 (Class 2 mobility), 10 (fractured), 13
6/29/2016	13	fract--	Remaining maxillary teeth: #s 9 (Class 2 mobility), 10 (fractured), 13

Date	Tooth	Key-No-Yes	phrase
6/29/2016	15	broke--	Broken and grossly tooth #15
6/29/2016	15	broke--	Broken and grossly decayed tooth #15
6/29/2016	18	fract--	fractured DL cusp of 18
6/29/2016	21	fract--	#21 Fracture and periapical abscess
6/29/2016	21	fract--	Pain on percussion tooth and large fracture #21.
6/29/2016	21	fract--	fractured #9, #21
6/29/2016	3	fract-forcep-	#3 gingival cuff reflected forceps seated and crown fractured off.
6/29/2016	31	fract--	#31- fracture ML cusp
6/30/2016	13	fract--vertical	vertical fractured #13
6/30/2016	13	fract--vertical	#13 vertical fractured w/ pain
6/30/2016	14	fract--root	#14 - fractured crown remaining roots
6/30/2016	14	fract--root	#14 fractured with PAP around retained root tips
6/30/2016	15	fract--	#15 fractured.
6/30/2016	15	fract--	- #15 fractured.
6/30/2016	30	fract--	Dental- fractured #30
6/30/2016	30	crack--	#30 is cracked.
6/30/2016	30	fract--	#30 Fractured Mesiodistally, class II mobility
7/1/2016	13	fract--	#1 Gross caries, #13 Fractured crown
7/1/2016	13	fract--	Fractured crown #13
7/1/2016	2	fract--	Dent - #2-5 carious, fractured, and non-restorable
7/1/2016	2	fract--	#20 Fractured
7/1/2016	20	broke--	20 years ago broken leg with no complications
7/1/2016	5	fract--	Dent - #2-5 carious, fractured, and non-restorable

Date	Tooth	Key-No-Yes	phrase
7/5/2016	13	fx--	fx'd carious tooth #13.
7/5/2016	13	fract--	Carious fracture #13
7/5/2016	14	fract--	#2, 4, 31, 14 decay/fracture
7/5/2016	14	fract--	#14- Previous RCT, fractured crown, spontaneous symptomatic
7/5/2016	15	fract--	Fractured/nonrestorable #15
7/5/2016	2	crack--	Past heroin/ crack use, pt has been clean for 2 years and now takes 97mg methodone
7/5/2016	2	crack--	Use of heroin/ crack in the past, has been clean for 2 years and is now on methodone
7/6/2016	18	fract--	#18 endo treated w/ post, fractured crown.
7/6/2016	18	fract--	#18 endo treated tooth with post, fractured crown.
7/6/2016	18	fract--	#18 Fractured Crown
7/6/2016	4	fract--	Fractured tooth 3-4 weeks, pain onset yesterday
7/6/2016	4	fract--	Fractured/decay #4
7/6/2016	4	fract--	Gross Decay/fracture #4, #19
7/6/2016	4	fract--	Decay/fracture #4, #19
7/7/2016	12	fract--	#12 fractured at gum line, #13 fractured at gum line, #16 endo-perio lesion and class III mobility, #17 defective restoration and non-functional after planned EXT of #16, #20 fractured at gum line
7/7/2016	13	fract--	#12 fractured at gum line, #13 fractured at gum line, #16 endo-perio lesion and class III mobility, #17 defective restoration and non-functional after planned EXT of #16, #20 fractured at gum line
7/7/2016	19	crack--	#19 cracked mesio-distally and PARL

Date	Tooth	Key-No-Yes	phrase
7/7/2016	19	crack--	#19 mesio-distally cracked tooth
7/7/2016	19	crack--	#19 mesio-distally cracked tooth with PARL
7/7/2016	20	fract--	#12 fractured at gum line, #13 fractured at gum line, #16 endo-perio lesion and class III mobility, #17 defective restoration and non-functional after planned EXT of #16, #20 fractured at gum line
7/8/2016	12	fract--	PPTC with fractured #12.
7/8/2016	14	fract--	Non-restorable fracture #14
7/8/2016	14	fract--	Fractured #14, large carious lesion, unrestorable
7/8/2016	18	fract--root	Fractured teeth with remaining roots #18 and #29.
7/8/2016	18	fract--	#18 DB fracture
7/8/2016	18	fract--	#18 DB fracture and PAP
7/8/2016	19	broke--	#19 Broken crown.
7/8/2016	2	broke--	Tooth #7 broke 2 days ago.
7/8/2016	20	fract--	Fracture/RL #20
7/8/2016	20	fract--	Fracture/gross decay #20
7/8/2016	20	fract--	Fractured crown #20, gross decay
7/8/2016	29	broke--	Crown of 29 broke off a week ago, causing pain.
7/8/2016	29	fract--root	Fractured teeth with remaining roots #18 and #29.
7/11/2016	15	fract-amalgam-	Fractured amalgam restoration #15
7/11/2016	18	fract--	18 - Gross decay and fracture
7/11/2016	18	fract--	18 - fractured with gross decay
7/11/2016	4	fract--	tooth #4 fractured with periapical pathology

Date	Tooth	Key-No-Yes	phrase
7/12/2016	12	fract--	Crown fractured tooth#12
7/12/2016	12	broke--root	#12 - broken crown, periapical radiolucency, slightly dilacerated root.
7/12/2016	12	broke--	Broken, crown fractured #12
7/12/2016	12	fract--	Tooth#12 Gross caries, fractured crown.
7/12/2016	12	fract--root	Ext 12 fractured crown/retained root tip
7/12/2016	12	fract--	#12 Fractured crown, nonrestorabl
7/12/2016	12	fract--	#12 Fractured crown, nonrestorable
7/12/2016	12	fract--	12- fractured crown
7/12/2016	18	crack--root	Carol had RCT #18 initiated by a civilian endodontist a few months ago and she was told that a crack was present that extended down into the distal canal/root making the long te
7/12/2016	18	fract--	#18 fracture, compromised filling
7/12/2016	18	fract--	Dental: #18 fractured restoration, symptomatic
7/12/2016	18	fx--	Dental: #18 EXT and draining of submandibular infx
7/13/2016	12	fract--	#12 filling fracture, caries
7/13/2016	12	fract--	PPTC with symptomatic pulpitis on #12 due to fractured restoration.
7/13/2016	12	fract--	#12 and #29 have large fractured fillings with caries
7/13/2016	12	fract--	Dental: symptomatic pulpitis on #12 due to fractured filling
7/13/2016	19	fract--	Tooth 19 and 30 gross decay, fractured crown.
7/13/2016	19	fract--	Fracture to MB cusp of 19.
7/13/2016	29	fract--	Fractured crown #29.

Date	Tooth	Key-No-Yes	phrase
7/13/2016	29	broke--	Broken tooth #29
7/13/2016	29	fract--	#29 Crown fracture
7/13/2016	29	fract--	#29 Crown fracture.
7/13/2016	30	fx--	Tooth #30 carious and fx'd down to osseous level-->non-restorable and acutely symptomatic
7/13/2016	4	fract--	-fractured #4 with recurrent decay
7/13/2016	4	fract--	Dental: #4: fractured with recurrent decay and periapical pathology
7/14/2016	19	fract--	Gross caries #19, fractured crown.
7/14/2016	19	fract--	Dental: Caries #19, fractured crown.
7/14/2016	19	broke--	Broken #19 with pain and sensitivity to palpation and percussion.
7/14/2016	19	broke--	Broken #19
7/14/2016	21	fract--	- #21 fractured crown with decay.
7/14/2016	21	fract--	#21 fractured with periapical pathology
7/14/2016	30	fract--	#30 - fractured with recurrent decay.
7/14/2016	30	fract--root	#30 - fractured/non restorable with periapical pathology on mesial root.
7/15/2016	13	fract--	Fractured #16,32,13
7/15/2016	13	fract--root	Fractured/carious #1, root tip #13, root tip #32, fractured #9, carious #17
7/15/2016	13	fract--root	Fractured #1, fractured/non-restorable root tip #13, root tip #32, fractured #9, carious #17
7/15/2016	13	fract--root	#13: Fractured, non-restorable, root tip retained
7/15/2016	13	fract--root	Fractured #1 (already extracted), Fractured #9 (restorable) Fractured #13 nonrestorable root tips

Date	Tooth	Key-No-Yes	phrase
			retained, Fractured #32 nonrestorable root tips retained.
7/15/2016	20	fract--	Fractured restorations on teeth #s 12 and 20.
7/15/2016	20	fract--	Fractured teeth #s 12 and 20, non-tender to palpation.
7/15/2016	29	fract--	Fractured #29
7/15/2016	30	fract--	#30 fractured DL cusp with recurrent decay.
7/15/2016	30	broke--	#30 broken/gross decay
7/15/2016	30	fract--	#30 fractured DL cusp with decay.
7/18/2016	2	fract--	fractured tooth #2
7/18/2016	2	fract--	Tooth #2 grossly decayed/fractured
7/18/2016	2	fract--	Tooth #2, fractured and causing pain for the past month
7/18/2016	30	fract--	Fractured crown #30
7/18/2016	5	fract--	Pt presented with fractured tooth #5 last Saturday.
7/18/2016	5	fract--	#5- MD fracture, lingual cusp mobile.
7/18/2016	5	fract--	-M-D fracture #5.
7/19/2016	14	broke--	grossly decayed #13, 14, 18 and 30 have broken cusps.
7/19/2016	18	fract-elevat-	elevated #18 with forceps and elevator technique but crown fractured.
7/19/2016	18	fract--	#18 and 20 fractured crowns and pain with percussion and palpation.
7/19/2016	19	fract--	Dental History Fractured restoration #19 in March 2016.
7/19/2016	2	fract--	visible fracture in #2

Date	Tooth	Key-No-Yes	phrase
7/19/2016	2	fract--	#2 is fractured mesial/distally.
7/19/2016	2	fract--	Fractured 1 and 2 -- tender to percussion and palpation
7/19/2016	2	fract--	Fractured 1 and 2 symptomatic, non-restorable
7/19/2016	20	fract--	#18 and 20 fractured crowns and pain with percussion and palpation.
7/19/2016	3	fract--	Pt noticed swelling 2-3 days ago with constant pain on the lower left area - fractured tooth/restoration on that side.
7/19/2016	3	fract--	#30 fractured.
7/19/2016	3	fract--	#30 fractured
7/19/2016	3	broke--	grossly decayed #13, 14, 18 and 30 have broken cusps.
7/19/2016	4	fract--	Ext 4 endodontic with chronic apical abscess, likely fractured
7/20/2016	13	fract--	Decay #13 w/ pain upon percussion, incisal fracture #9
7/20/2016	14	fract--	bilateral mand lingual tori, right crossbite, fractured #14.
7/20/2016	14	fract--	PA shows fractured #14
7/20/2016	15	fract--	#15 fractured several years ago
7/20/2016	29	fract-elevat-	tions were routine extractions delivered with small straight elevator, #151 and Ash forceps except #29 where fissure bur was used to make mesial purchase and deliver tooth with small straight elevator
7/20/2016	3	broke--	Pt reports that #3 broke several weeks ago but just starting hurting last week.

Date	Tooth	Key-No-Yes	phrase
7/20/2016	3	broke--	Large broken restoration on #3, sensitive to percussion and palpation
7/21/2016	19	fract--	#19 fractured cusp
7/21/2016	20	fract--	#20 fractured, carious
7/21/2016	20	fract--	#20 fractured
7/21/2016	3	fract--	#3 gross carious lesion and fractured crown.
7/21/2016	3	fract--	#3 gross carious lesion with crown fracture
7/21/2016	30	fract--	#13, 30, 31 fractured
7/21/2016	31	fract--	#31 fractured
7/21/2016	31	fract--	#13, 30, 31 fractured
7/22/2016	19	fract--	#19 carious/fractured
7/22/2016	3	fract--	#3 has enamel fractures on mesial marginal ridge visible with light.
7/22/2016	3	fract--vertical	Dx: generalized moderate chronic periodontitis, localized severe chronic periodontitis (3, 8, 15), vertical root fracture (8)
7/22/2016	3	crack--	A/P: PPTC for cracked tooth #3.
7/22/2016	3	fract--	#3 fracture lines
7/22/2016	3	fract--	Dental: #3 sensitive to percussion, general dentist questions restorability due to fracture
7/25/2016	19	fract--	#19 - D half of crown has fractured off at the gumline
7/25/2016	19	fract--	Crown fracture & caries to the pulp #19
7/25/2016	19	broke--	#19 broke off 1 week ago, pain ever since
7/25/2016	19	fract--root	Tooth #19- distal root fractured, distal root removed with root tip pick.

Date	Tooth	Key-No-Yes	phrase
7/25/2016	19	crack--	Cracked tooth #19, sensitive to palpation and percussion
7/25/2016	19	crack--	Cracked #19 without periapical radiolucency, non-tender to percussion
7/25/2016	19	crack--	Dental- #19 is a cracked tooth, non-tender to percussion
7/25/2016	2	fract--root	#2 probable root fracture
7/25/2016	20	fract--root	#20 with large PARL, fractured retained root, very tender to percussion
7/25/2016	30	fract--	#30 has a fractured DB cusp.
7/25/2016	30	fract--root	Fractured cusp #30, with periapical radiolucency around MB root
7/26/2016	14	crack--	Dental: Cracked #14 with gross decay
7/26/2016	14	crack--	Cracked #14 with gross decay
7/26/2016	14	broke--	#14 slightly sensitive to percussion, mesial marginal ridge broken
7/26/2016	21	fract--	Tooth #21 fractured and mobile.
7/27/2016	12	crack--vertical	#12 has a history of vertical crack and localized severe chronic periodontitis leaving it nonrestorable.
7/27/2016	20	fract--	#20 symptomatic, fractured, carious
7/28/2016	19	fract--	#19 fractured 4 years ago.
7/28/2016	19	fract--	#19 - fractured, carious, sensitive to percussion
7/28/2016	19	fract--	#19 - fractured, carious, PAP, previous NSRCT
7/28/2016	19	fract--	#19 - fractured, carious, sensitive to percussion, nonrestorable

Date	Tooth	Key-No-Yes	phrase
7/28/2016	29	fract--root	- Grossly carious remaining mandibular dentition: Fractured/retained roots #s 20-29, 32
7/28/2016	29	fract--root	Grossly carious remaining mandibular dentition: Fractured/retained roots #s 20-29, 32
7/28/2016	31	fract--	Dental: Apical periodontitis #31 and fracture on #31
7/28/2016	31	fract--	Fractured tooth #31
7/29/2016	19	broke--	#19 grossly carious, broken d
7/29/2016	19	broke--	#19 grossly carious, broken down crown, percussion sensitive
7/29/2016	5	broke--	#5 grossly carious, broken down crown
8/1/2016	15	fract--	#15-carious, nonrestorable, fractured
8/1/2016	15	fract--	#15 - large coronal caries, fractured, spontaneous sharp pain rated 10 out of 10
8/1/2016	15	fract--	#15 - large coronal caries, fractured, nonrestorable
8/1/2016	18	fract--	carious and fractured #18 with swelling in vestibule adjacent to #18.
8/1/2016	20	fract--	Fractured #20 - nonrestorable
8/1/2016	3	fract--	Brianna Hoover is a 23yo female who presents to clinic with pain associated with grossly carious/fractured #3 and #5.
8/1/2016	3	fract--	Reports fracture of teeth approx 3 mo ago.
8/1/2016	5	fract--	Brianna Hoover is a 23yo female who presents to clinic with pain associated with grossly carious/fractured #3 and #5.
8/2/2016	13	fract-amalgam-	#13 - fract amalgam, gross caries, symptomatic to palpation and percussion, PAP.

Date	Tooth	Key-No-Yes	phrase
8/2/2016	13	fract-amalgam-	#13 - fract amalgam, gross caries, symptomatic to palpation and percussion
8/2/2016	19	fract--	#19 fractured Jan 2016 with history of abscess and pain.
8/2/2016	2	fract--	#20 MOD fractured lingual cusp with caries.
8/2/2016	3	fract--	No CC at this time other than fractured #3 from M to D of tooth
8/2/2016	30	fract--	#30-fractured with gross caries, TTP
8/2/2016	30	fract--	#30-fractured with caries, symptomatic irreversible pulpitis
8/3/2016	12	fract--	Dental: Gross caries/crown fracture #9, #12.
8/3/2016	14	fract--	Dental- #14- Fractured tooth with gross decay, and necrotic pulp.
8/3/2016	19	fract--	gross caries and fractured DB cusp #19
8/3/2016	19	fract--	#19 fractured
8/3/2016	19	fract--	#19 fractured DB and D cusp
8/3/2016	19	fract--	pt reports #19 fractured a year ago and has been throbbing pain for a couple months.
8/3/2016	2	fract--	#2 fractured, carious
8/3/2016	2	fract--	#2 fractured, carious, nonrestorable
8/3/2016	2	fract--	Fractured tooth #2.
8/3/2016	2	fract--	#2-fractured crown w/ caries, symptomatic and nonrestorable
8/3/2016	2	fract--	#2-fractured crown, TTP
8/3/2016	29	fract--	Fractured crown and gross decay and evidence of PAP, #29
8/3/2016	29	fract--	Fractured crown and gross decay, #29

Date	Tooth	Key-No-Yes	phrase
8/3/2016	29	fract--	#29 fracture, #2 severe bone loss
8/3/2016	3	broke-elevat-root	#30 crown broke at CEJ, retrieved and the roots delivered with elevator, bone file used for any sharp margins
8/3/2016	30	fract--	fractured #30
8/3/2016	30	fract--	#16 Gross Caries, #30 Fractured
8/3/2016	30	fract--	fractured #30- EXT
8/4/2016	15	fract-amalgam-	defective #2 amalgam restoration with sensitivity, fractured #15 amalgam
8/4/2016	15	fract-amalgam-	fractured #15 amalgam OL
8/4/2016	15	fract--	#15 non restorable (grossly carious with buccal cusps fracture), tooth reports sensitivity with #15 with colder foods
8/4/2016	15	fract--	#15 non restorable (grossly carious with buccal cusps fracture), pt reports sensitivity with tooth with colder foods
8/4/2016	15	fract--	#15 fractured for a few years.
8/4/2016	15	fract--	#15 fractured non restorable carious tooth, no history of swelling
8/4/2016	2	fract--	fractured tooth #2
8/4/2016	3	split--	#3 split, non-restorable
8/4/2016	3	split--	Tooth #3 split.
8/4/2016	3	split--	Split #3
8/4/2016	4	fract--vertical	#4 PAP, vertical root fracture
8/5/2016	13	crack--	Except caries and cracked crown #13.
8/5/2016	13	crack--	Dental: Cracked crown with caries #13, non-restorable

Date	Tooth	Key-No-Yes	phrase
8/5/2016	13	crack--	#13- Cracked crown, tender to palpation and percussion.
8/5/2016	13	fract--	Grossly carious/fractured #13 and 29
8/5/2016	13	fract--	- Grossly carious/fractured #s 13 and 29
8/5/2016	13	fract--	Grossly carious #13, fractured off at gingival level
8/5/2016	13	fract--	Grossly carious #13, fractured off at bone level
8/5/2016	13	fract--	#13 grossly carious, fractured
8/5/2016	18	fract--	#18 fractured off crown
8/5/2016	18	fract--	#18 gross caries, crown has fractured off-sensitive to palpation, and percussion
8/5/2016	18	fract--	#18 gross caries, crown has fractured off
8/5/2016	19	broke--	19, 30 crowns broken down and at the level of gingiva
8/5/2016	2	fract--	OH Assessment:fair, food impaction between 2/3- #2 is unopposed and has a fractured MO
8/5/2016	2	fract--	Discussed #2 fractured restoration and food impaction, advised tooth is also unopposed and has no occlusion, if pt does not desire to have restoration repaired, tooth can be extracted.
8/5/2016	30	broke--	19, 30 crowns broken down and at the level of gingiva
8/8/2016	13	fract--	gross decay, fractured #13
8/8/2016	3	crack--	I have a cracked tooth (points to #3)
8/8/2016	3	fract-amalgam-	Deep MOD amalgam #3 that fractured in May.
8/8/2016	3	fract--	#3 Class III Fracture
8/8/2016	3	fract--	#3 Class III Ellis Fracture

Date	Tooth	Key-No-Yes	phrase
8/8/2016	31	fract--	#31 fractured distally, caries
8/8/2016	31	fract--	#31 fractured distally, caries approximating pulp
8/8/2016	31	fract--	Carious fractured #31 with poor prognosis
8/8/2016	31	fract--	#31 grossly carious to pulp, fractured
8/8/2016	31	crack--	#31 has a temporary crown with a crack underneath.
8/8/2016	31	crack--	#31: Cracked occlusally.
8/8/2016	31	crack--	Dental: #31 cracked tooth.
8/9/2016	15	fract--	Carious Lesion #15 /Fractured
8/9/2016	15	fract--	Non-restorable due to coronal fracture #15
8/9/2016	19	fract--	Fractured #19 w/ gross caries and nonrestorable
8/9/2016	19	fract--	Fractured #19 w/ gross decay
8/9/2016	2	fx--	#31- MODB restoration with M secondary decay, non-fxnl tooth post ext of #2.
8/9/2016	2	fract--	Myocardial infraction 2013
8/9/2016	29	fract--	gross caries and fractured tooth #29 requiring ext, to allow for healing prior to beginning mandibular RPD
8/9/2016	30	crack--	A: #30 Occlusal adjustment, suspect but could not confirm cracked DL cusp reeval if symptoms persist, #4 DO, restore #4 with Phd
8/9/2016	30	crack--	possible cracked tooth #30.
8/9/2016	30	fract--	Etiology possible fracture on #30
8/9/2016	30	fract-amalgam-	Dental History #30 was restored with amalgam DO as well as B, pt was told that at placement of amalgam restoration possible fracture of tooth

Date	Tooth	Key-No-Yes	phrase
			was present, will not know if tooth is fractured unless a
8/9/2016	30	fract--	#30 & 31 fractured, non-restorable
8/9/2016	30	fract--	Fractured #7, 9, 10, 19, 30, 31
8/9/2016	30	fract--	#30 and #31 fractured, pt does not recall how long ago they were fractured.
8/9/2016	31	fract--	#30 & 31 fractured, non-restorable
8/9/2016	31	fract--	Fractured #7, 9, 10, 19, 30, 31
8/9/2016	31	fract--	#30 and #31 fractured, pt does not recall how long ago they were fractured.
8/9/2016	4	fract--	#4 fractured to gum line, sensitive to percussion and palpation
8/9/2016	4	fract--	#4 fractured to gumline
8/10/2016	2	fract--	Pt is aware (from previous note) that it is recommended that he have retreat RCT #12, core and new PFM crown since he has fractured the buccal cusp from the tooth.
8/10/2016	2	fract--	right wrist fracture, surgery to fix it in 2010
8/10/2016	2	broke--	#2 was removed with broken buccal plate and associated soft tissue attached to it.
8/10/2016	31	fract--	#31 fractured L cusps/caries with radiographic PAP
8/10/2016	5	fract--	Carious and fractured teeth #s 5, 6, 7, 8, 9, 10, 11
8/11/2016	12	broke--	#12- broken down, L cusp fracture.
8/11/2016	12	fract--	#12 fracture
8/11/2016	12	fract--	- #12 gross decay, L cusp fracture.

Date	Tooth	Key-No-Yes	phrase
8/11/2016	12	fract--	#12 Lingual fracture, Symp.
8/11/2016	12	fract--	#12 Lingual cusp fractured about a year ago.
8/11/2016	12	broke--	#12- gross caries, broken crown
8/11/2016	12	broke--	Pt reported that the tooth #12 has broken down since 2010 and 4 and 5 since March 2016
8/11/2016	20	fract--	Decay found: #7 D, #20 B, #13 BO fracture cusp with recurrent decay.
8/11/2016	4	broke--	#4- gross caries, broken down crown
8/11/2016	4	broke--	Pt reported that the tooth #12 has broken down since 2010 and 4 and 5 since March 2016
8/11/2016	5	broke--	Pt reported that the tooth #12 has broken down since 2010 and 4 and 5 since March 2016
8/12/2016	13	fract--	Dental: Carious/fractured/limited prognosis #2, 4, 5, 6-11, 13, 15, 22-27
8/12/2016	13	split--	Appointment 1: EXT posteriors (#2, 4, 5, 13, 15) May possibly split this first appointment into 2 visits depending on hemostasis.
8/12/2016	15	fract--	Dental: Carious/fractured/limited prognosis #2, 4, 5, 6-11, 13, 15, 22-27
8/12/2016	15	split--	Appointment 1: EXT posteriors (#2, 4, 5, 13, 15) May possibly split this first appointment into 2 visits depending on hemostasis.
8/12/2016	2	fract--	Carious/fractured/non-restorable #2, 6, 7, 10, 11
8/12/2016	2	split--	Appointment 1: EXT posteriors (#2, 4, 5, 13, 15) May possibly split this first appointment into 2 visits depending on hemostasis.
8/12/2016	3	fract--	#3, 12, 19 - fractured
8/12/2016	3	fract--	is a 35yo female who presents to clinic with pain associated with fractured #3.

Date	Tooth	Key-No-Yes	phrase
8/12/2016	4	fract--	Dental: Carious/fractured/limited prognosis #2, 4, 5, 6-11, 13, 15, 22-27
8/12/2016	4	split--	Appointment 1: EXT posteriors (#2, 4, 5, 13, 15) May possibly split this first appointment into 2 visits depending on hemostasis.
8/12/2016	5	fract--	Dental: Carious/fractured/limited prognosis #2, 4, 5, 6-11, 13, 15, 22-27
8/12/2016	5	split--	Appointment 1: EXT posteriors (#2, 4, 5, 13, 15) May possibly split this first appointment into 2 visits depending on hemostasis.
8/15/2016	12	fract--	A: Max: fractured #3, #12, caries, defected restoration
8/15/2016	12	fract--	#3 & 12 fractured, non-restorable
8/15/2016	3	broke--	He mentioned the possibility of a broken down subgingival restoration located on the lingual wall of #3.
8/15/2016	3	fract--	A: Max: fractured #3, #12, caries, defected restoration
8/15/2016	3	fract--	#3 & 12 fractured, non-restorable
8/17/2016	2	fract--	#2DB fractured & decay
8/17/2016	3	crack--	43 yof originally presented 7/15/15 for evaluation of cracked teeth and symptomatic upper left wisdom tooth.
8/17/2016	30	fract--	#30 fractured DMR
8/17/2016	30	fract--	#30 fractured Distal cusp
8/17/2016	30	fract--	#30 Fractured distal cusp
8/17/2016	30	fract--	Dental: Severely fractured and decayed #30
8/18/2016	12	broke--	broken off crown 12 and 15, RL #30, RL #4, no sinus pathology.

Date	Tooth	Key-No-Yes	phrase
8/18/2016	12	broke--	severe attrition 7-10, crown is broken off 12, and 15.
8/18/2016	15	fract--	#15 gross decay, fracture down the buccal surface
8/18/2016	15	crack--	weeks ago, patient visited her dentist who explained to patient the tooth was non-restorable due to cracked tooth, PPTC VCUSOD for ext #15
8/18/2016	19	fract--	Gross Decay/fracture #4, #19
8/18/2016	19	fract--	Decay/fracture #4, #19
8/18/2016	19	fract--	#19 carious w/fract crown.
8/19/2016	14	fract-elevat-	PPTC with severe pain #14, periosteal elevator used, crown was fractured.
8/19/2016	19	crack--	Pt c/o pain with chewing on LL (#19), broken tooth (#19), cracked tooth (#3), and possible cracked tooth LR (#30)
8/19/2016	19	fract--	fractured #19
8/19/2016	19	fract--	determined fractured tooth at last appointment #19
8/19/2016	3	fract--	Fractured #3
8/19/2016	30	fract--	#10, 30, and 31 fractured and TTP
8/19/2016	31	fract--	#10, 30, and 31 fractured and TTP
8/22/2016	19	fract--root	Dental: Fractured tooth and retained root tips tooth #19
8/22/2016	3	broke--	43 YO healthy male presents with CC of pain and swelling on the upper right with a broken tooth.
8/22/2016	3	broke--	Dental: #3 broken, tenderness to percussion
8/22/2016	3	broke--	#3 broken, tenderness to percussion

Date	Tooth	Key-No-Yes	phrase
8/22/2016	3	broke--	#3 broken, tender to percussion on the upper right buccal vestibule of #3
8/23/2016	13	fract-porcelain-	#13 fractured lingual porcelain, crown is stable otherwise and does not need restoration, just smoothing for now.
8/23/2016	15	crack--	53yo female healthy presents today evaluation of tooth #15 due to tooth cracked.
8/23/2016	15	fract--	Dental - Fractured #15.
8/23/2016	15	fract--	Dental - Fractured #15
8/24/2016	18	fract--	Examined #18 and noted significant M-D fracture with caries present.
8/24/2016	18	crack--	Dr suspects cracked cusp syndrome and recommends temporary crown at next visit to stabilize #18.
8/24/2016	19	fract--	Upon clinical examination it was found that the tooth #19 was fractured and severe decay was present.
8/24/2016	19	fract--	#19 Fractured and carious (non-restorable),
8/24/2016	19	fract--	#19 gross decay, fractured restoration - non-restorable
8/24/2016	29	fract-elevat-	#29- attempted to luxated tooth, tooth fractured, handpiece used to create mesial and distal troughs, tooth elevated with periotomes.
8/24/2016	3	fract-amalgam-	Fractured #3-distal aspect of amalgam restoration
8/24/2016	3	fract--root	#3-Distal caries at root, fractu
8/24/2016	5	fract--	Upon evaluation, tooth #5 has fractured lingual wall to the gingiva with remaining buccal wall.
8/24/2016	5	fract--root	#5 root fracture
8/24/2016	5	fract--root	#5 root fracture, percussion sensitive

Date	Tooth	Key-No-Yes	phrase
8/25/2016	18	fract-amalgam-	Large fractured DO amalgam restoration, #18
8/25/2016	18	fract--	#18 carious, fractured, nonrestor., symp
8/25/2016	18	fract--	#18 - nonrestorable fractured and carious
8/25/2016	18	fract--	#18-fractured crown and coronal radiolucency
8/25/2016	18	fract--	#18 large coronal caries and fractured crown, symptomatic, tender to percussion
8/25/2016	3	fract--	#3 fractured, carious, non-restorable
8/25/2016	30	fract--	Fractured #30
8/25/2016	30	fract--	Grossly carious tooth #30 with fractured crown
8/25/2016	30	broke--root	Pt has broken teeth #4,7,30,10,14 where just the root tips remain.
8/25/2016	30	broke--root	crowns broken off of #4,7,10,14,30 with root tips remaining
8/25/2016	30	broke--root	Crowns are broken off on #4,7,10,13,14,30 with root tips remaining.
8/25/2016	4	broke--root	Pt has broken teeth #4,7,30,10,14 where just the root tips remain.
8/25/2016	4	broke--root	crowns broken off of #4,7,10,14,30 with root tips remaining
8/25/2016	4	broke--root	Crowns are broken off on #4,7,10,13,14,30 with root tips remaining.
8/26/2016	12	fract--root	Surgical notes: Severe bone loss extending into furcation mesial #12, no root fracture observed.
8/26/2016	13	fract--	#13 fractured crown
8/26/2016	18	fract--	Fractured crown and RCT'ed #18
8/26/2016	18	fract--	Grossly fractured #18
8/26/2016	20	fract--	Fractured/carious #20, #28, caries #30

Date	Tooth	Key-No-Yes	phrase
8/26/2016	20	fract--	Gross caries and fractured #20
8/26/2016	20	broke--	Tx: Pt has broken multiple appointments since I first saw her in August 2010.
8/26/2016	20	fract--	#20 - large restoration, fractured, recurrent decay
8/26/2016	30	fract--	Fractured ML cusp #30
8/26/2016	30	fract--root	Fractured crown #30, PAP mesial root #30
8/26/2016	30	fract--	Fractured #30, gross decay #30
8/26/2016	31	fract--	#31 - large restoration, fractured, recurrent decay
8/26/2016	5	fract-forcep-root	Site #5- extracted with forceps, buccal root fracture off.
8/26/2016	5	fract--	#5 fractured crown
8/26/2016	5	fract--	PPTC with fractured #5 reports that the crown fractured off approx 1 week ago.
8/29/2016	31	fract--	Diagnosis Fractured restoration #32 and primary caries #31
8/30/2016	2	fract--root	#2 Gross Decay, #3 Fractured Root Tip
8/30/2016	2	fract--	#2 Gross Decay, #3 fractured beneath gumline
8/30/2016	2	fract--	Gross Decay #2, #3 fractured at gumline
8/30/2016	2	fract--root	Panoramic shows gross decay D #2, Fractured #3 root tips
8/30/2016	3	fract--root	#2 Gross Decay, #3 Fractured Root Tip
8/30/2016	3	fract--	#2 Gross Decay, #3 fractured beneath gumline
8/30/2016	3	fract--	Gross Decay #2, #3 fractured at gumline
8/30/2016	3	fract--root	Panoramic shows gross decay D #2, Fractured #3 root tips
8/31/2016	5	fract--	#5: carious, fractured, nopnrest., sympt

Date	Tooth	Key-No-Yes	phrase
8/31/2016	5	fract--	#5: nonrestorable, grossly carious, fractured MB, symptomatic.
8/31/2016	5	fract--	#5: fractured MB, grossly carious, symptomatic to percussion, nonrestorable
9/1/2016	30	fract--	#30 Non-restorable crown fracture
9/1/2016	30	fract--	#30 crown fracture- non-restorable
9/1/2016	30	fract--	#30 crown fracture (spontaneous pain)
9/1/2016	5	fract--	Fractured #5 and #6
9/1/2016	5	fract--	Fractured, symptomatic #5 and #6
9/1/2016	5	fract--	PPTC for pain in around fractured #5 and #6.
9/4/2016	30	fract--	decayed and fractured teeth Large PA lesion tooth #30
9/6/2016	2	fract--	-knee reconstruction for tibial plateau fracture, July 2016, no complications
9/6/2016	2	fract--	knee reconstruction for tibial plateau fracture, July 2016, no complications
9/6/2016	20	fract--	Fractured and carious tooth #20 w/ symptomatic apical periodontitis.
9/6/2016	28	fract--	crown fractured tooth #28
9/6/2016	3	fract--	Fractured and grossly carious #3, 4, 13, 15, 20
9/6/2016	30	broke--	Broken teeth: #14, #18, #30
9/6/2016	30	broke--	Gross carious decay/broken teeth #14, 18, 30
9/6/2016	4	fract--	Was fractured during extraction of #14
9/6/2016	4	fract--	Fractured and grossly carious #3, 4, 13, 15, 20
9/7/2016	15	fract--	#1 fractured and #15 decayed to bone level, nonrestorable

Date	Tooth	Key-No-Yes	phrase
9/7/2016	15	fract--	Fractured #1 and #15 to bone, nonrestorable
9/7/2016	15	fract--	#15 fractured, gross decay extending to bone level, non-restorable
9/7/2016	18	fract--	#18: Fractured Distal
9/7/2016	18	fract--	31 yo male presents to clinic with pain associated with #18, and fractured #2.
9/7/2016	18	fract--	#2 fractured, #18 symptomatic/carious
9/7/2016	2	fract--	#2: Fractured crown/caries
9/7/2016	2	fract--	31 yo male presents to clinic with pain associated with #18, and fractured #2.
9/7/2016	2	fract--	#2 fractured
9/7/2016	2	fract--	#2 fractured, #18 symptomatic/carious
9/8/2016	20	broke--	#20 restoration broke 2-3 years ago.
9/8/2016	20	broke--	#20- broken crown
9/8/2016	20	broke--	Pt use to have restoration on #20 but restoration broke 2-3 years ago.
9/8/2016	20	broke--	#20- broken crown, carious
9/8/2016	20	broke--	#20- broken crown, PAP
9/8/2016	4	fract--	A: fractured #4 desiring an impant/ Hard tissue exam with 4 bitewings
9/8/2016	4	fract--	Fractured crown on #4
9/8/2016	4	fract--	Fractured crown on tooth #4 with visible decay.
9/9/2016	14	broke--	A: DL portion of existing composite restoration on #14 DOL is broken off.
9/9/2016	14	crack--	As discussed with the discovery of the crack and associated symptoms, patient was advised to

Date	Tooth	Key-No-Yes	phrase
			schedule appointment with VCU OMFS clinic to have tooth #14 extracted.
9/9/2016	15	crack--	#2 decay - nonrestorable, #15 cracked to
9/9/2016	15	crack--	#15 cracked cusp - EXT
9/9/2016	15	crack--	#15 MB cracked cusp
9/9/2016	15	crack--	#15 MB cracked cusp to beyond bone
9/9/2016	2	broke--	Broken Leg - 2011
9/9/2016	2	broke--	Broken Hand - 2006
9/9/2016	2	crack--	#2 decay - nonrestorable, #15 cracked to
9/9/2016	30	fract--	#30 - grossly carious, fractured, symptomatic, nonrestorable
9/9/2016	30	fract--root	#30 - fractured, grossly carious, 3x3 mm PAP at M root
9/9/2016	31	broke--	Broken crown #31
9/9/2016	31	broke--	#31- broken down, non-restorable
9/12/2016	12	fract--	Clinical exam reveals #11,12,26,29 with fractures and decay.
9/12/2016	13	fract--	#s 5-13, 20-29 all fractured
9/12/2016	20	fract--	#s 5-13, 20-29 all fractured
9/12/2016	29	fract--	Clinical exam reveals #11,12,26,29 with fractures and decay.
9/12/2016	29	fract--	#s 5-13, 20-29 all fractured
9/12/2016	3	fract--	#s 5-13, 20-29 all fractured
9/12/2016	5	fract--	#s 5-13, 20-29 all fractured
9/13/2016	19	fract--	Gross caries/fractured #19

Date	Tooth	Key-No-Yes	phrase
9/13/2016	19	fract--	#19 Tooth fractured about two months ago and is sensitive upon chewing and to cold/hot.
9/14/2016	13	fract--	#13 fractured tooth/carious - sensitive to percussion and slight sensitivity to palpation
9/14/2016	13	fract--	#13 fractured tooth/carious - nonrestorable
9/14/2016	13	fract--	Fractured and grossly carious 13 and 15
9/14/2016	14	fract--	O: #14 MB cusp fractured into dentin.
9/14/2016	14	fract--	O: #14- MB cusp was fractured and was temp restored with limelite (GI).
9/14/2016	15	fract--	#15 fractured tooth/carious - sensitive to percussion and slight sensitivity to palpation
9/14/2016	15	fract--	#15 fractured tooth/carious - potentially restorable but pt denied tx and consented to extraction
9/14/2016	15	fract--	Fractured and grossly carious 13 and 15
9/14/2016	19	fract--	#19 fractured restoration, gross caries, sensitive to percussion
9/14/2016	30	fract--	fractured, carious #30
9/15/2016	13	fract--	Fractured and grossly carious #3, 4, 13, 15, 20
9/15/2016	13	crack--	Dental: Cracked crown on #13, pt opts to extract
9/15/2016	14	fract--root	Fractured root tips #14
9/15/2016	14	broke--	#14 broke off 2 weeks ago, occasionally gives her pain.
9/15/2016	14	fract--root	Fractured/root tips #14
9/15/2016	14	broke--	Broken down #14
9/15/2016	20	fract--	Fractured and grossly carious #3, 4, 13, 15, 20

Date	Tooth	Key-No-Yes	phrase
9/15/2016	30	fract--	RCT performed on tooth #29, #30, Crown fracture on tooth #29 as well as deep caries present.
9/15/2016	30	fract--	Dental: Frank carious lesions, RCT #29,#30 along with crown fracture tooth#29
9/15/2016	30	fract--	grossly carious/fractured #30.
9/15/2016	31	fract--	Fracture of #31 DL cusp, observe for progression.
9/15/2016	31	fract--	Fractured tooth #31
9/15/2016	31	crack--	-#31 cracked yesterday, painful to chewing
9/15/2016	31	crack--	cracked #31
9/15/2016	31	fract--	-Fracture going subgingival on lingual of #31
9/16/2016	5	fract--	The distobuccal restoration material on tooth #5 sustained a small hairline fracture.
9/16/2016	5	fract--	Dental: Extract #5 fractured crown
9/16/2016	5	fract--	#5 crown fractured about a month ago
9/16/2016	5	fract--	#5 fractured crown
9/16/2016	5	fract--	Tooth #5 fractured crown
9/16/2016	5	fract--	#5 caries, fractured cusp
9/19/2016	2	fract--	#2 cusp fracture.
9/19/2016	2	fract--	#2 fractured cusp, gross caries
9/19/2016	2	fract--	Dental- #2 fractured D cusp, gross caries, non-restorable
9/19/2016	2	fract--	#2- fractured D cusp, gross caries
9/19/2016	2	fract--	#2 fractured D cusp, gross caries, sensitive to palpation and percussion, non-restorable

Date	Tooth	Key-No-Yes	phrase
9/19/2016	20	fract--	Crown of tooth #20 is fractured.
9/19/2016	20	broke--	Grossl carious #20 - broken off at gumline.
9/19/2016	30	fract--	fractured/symptomatic #30
9/20/2016	13	broke--root	#13 broken at gingiva (previously endo tx), root tip present
9/20/2016	13	broke--	#13 broken at gingiva (previously endo tx)
9/20/2016	13	broke--root	#13 broken at gum, residual root tip
9/20/2016	15	fract--	#15 - Fractured crown
9/20/2016	15	fract--root	Dental: #15 - fracture, retained roots, swelling present
9/20/2016	19	fract--	Fractured/non-restorable #19
9/20/2016	19	fract--	Dental: Fractured/non-restorable #19, sensitivity to percussion
9/20/2016	19	fract--	Fractured/non-restorable #19, sensitivity to percussion
9/20/2016	2	fract--	Fractured tooth #2 has been hurting for a week.
9/20/2016	2	fract--	Fractured and grossly carious #2
9/20/2016	2	fract--	#2 mostly caries and fracture - sens.
9/20/2016	2	fract--	#2 Fractured tooth
9/20/2016	4	fract--	Fractured tooth #4
9/21/2016	12	crack--	#12 cracked tooth syndrome.
9/21/2016	12	crack--	suspect cracked tooth #12
9/21/2016	3	fract--	Fractured/carious #3
9/21/2016	3	fract--	Dental: Fractured/carious #3
9/21/2016	3	fract--	fracture/caries #3

Date	Tooth	Key-No-Yes	phrase
9/22/2016	13	fract--	#13 fractured mesiodistally
9/22/2016	13	crack--	Dental: #13 cracked mesiodistally, nonrestorable
9/22/2016	13	crack--	Hard tissue exam #13 cracked through and through mesiodistally
9/22/2016	13	fract--	#13- fracture
9/22/2016	29	fract--	Fractured subgingival, unrestorable #29
9/23/2016	13	broke--root	Crowns are broken off on #4,7,10,13,14,30 with root tips remaining.
9/23/2016	14	broke--root	Pt has broken teeth #4,7,30,10,14 where just the root tips remain.
9/23/2016	14	broke--root	crowns broken off of #4,7,10,14,30 with root tips remaining
9/23/2016	14	broke--root	Crowns are broken off on #4,7,10,13,14,30 with root tips remaining.
9/26/2016	18	fract--	Fractured #18
9/26/2016	2	fract--	Fractured tooth #2, #4
9/26/2016	3	fract--	#3MO fracture
9/26/2016	3	fract--	#3 MO fracture
9/26/2016	3	fract--	#3-MO fractured
9/26/2016	4	fx--root	#2-DO caries, #4-DO caries, #5- crown fx, root tip, #8 incisal fx, #28-O caries, #29 reeval O after cleaning, #31-MO amalg fx mesial marginal cusp
9/26/2016	5	fx--root	#2-DO caries, #4-DO caries, #5- crown fx, root tip, #8 incisal fx, #28-O caries, #29 reeval O after cleaning, #31-MO amalg fx mesial marginal cusp
9/26/2016	5	fx--root	#5- fx crown, root tip

Date	Tooth	Key-No-Yes	phrase
9/27/2016	12	fract--	#4 with fractured lingual cusp and M overhang, #5 mobile with RL at apex from previous radiographs, #11 D RL, DL decay, #12 F composite marginal defect, #18 purulent drainage from sulcus #19 D margina
9/27/2016	12	fract--	Hard tissue exam Clinical caries noted on #11D #31DL, Abfraction noted on #12B, #13B, #19B, #21B (See Tx developed 4/2012).
9/27/2016	12	fract-amalgam-root	Hard tissue exam (Findings) #11D decay, abfraction #12, #13 exposing root canal and needs restoration, #19 decay, #20 occlusal amalgam
9/27/2016	14	fract--	Abfractions #2,3,14,15.
9/27/2016	14	fract-amalgam-	#14 D amalgam fracture.
9/27/2016	14	fract-amalgam-	#14 fractured lingual portion of existing MODB amalgam.
9/27/2016	15	fract--	Abfractions #2,3,14,15.
9/27/2016	28	fract--	Fractured crown #28
9/27/2016	28	fract--	Fractured crown #28, widened PDL
9/27/2016	28	fract--	Dental: Fractured #28
9/27/2016	28	fract--	Fractured #28
9/27/2016	3	fract--vertical	#3 - Vertical root fracture discovered during excavation of caries yesterday in GP
9/27/2016	3	fract--vertical	#3 - Vertical root fracture discove
9/27/2016	4	fract--	#4 with fractured lingual cusp and M overhang, #5 mobile with RL at apex from previous radiographs, #11 D RL, DL decay, #12 F composite marginal defect, #18 purulent drainage from sulcus #19 D margina

Date	Tooth	Key-No-Yes	phrase
9/27/2016	4	fract--	Hard tissue exam Clinical caries noted on #11D #31DL, Abfraction noted on #12B, #13B, #19B, #21B (See Tx developed 4/2012).
9/29/2016	29	fract--	Gross caries/fractured #29
9/29/2016	29	fract--	#29 - fractured DL cusp, gross caries
9/29/2016	29	fract--	Pt reports lower right tooth in area of #29 fracturing about 3 weeks ago.
9/29/2016	30	fract--	Fractured #1, Fractured #17, Fractured #30
9/29/2016	30	fract--	Fractured and unrestorable #1,17,30
9/29/2016	4	fract--	#4 fractured and carious #5-MOD #19-MO
9/29/2016	4	fract--	#4 fractured at the gum line
9/30/2016	13	split--	function, broken restorations, #5 questionable prognosis, due to significant tooth structure loss, #13 split - hopeless, strongly recommended stress control, occlusal guard, pati
9/30/2016	13	fract--	13 fractured with assoc large lesion.
9/30/2016	19	fract--	caries #19, fractured #18
10/3/2016	14	fract--	Fractured ML cusp of #14, Distal angular bone loss
10/3/2016	2	split--	Split dam will be necessary for isolation #14-12.
10/3/2016	2	fract--	pptc: C/O fractured filling #2.
10/3/2016	3	fract--	PPTC with fractured tooth #3 below gingival margin.
10/3/2016	3	fract--	NNV: restorative appt with student- pt fractured #3
10/3/2016	3	fract--	Fractured crown #3 - non restorable - reviewed PA taken in grad perio

Date	Tooth	Key-No-Yes	phrase
10/3/2016	3	fract--	#3 fractured crown - non restorable.
10/3/2016	3	crack--	Since last visit, pt reports implant crown #30 became loose after she heard a crack while chewing.
10/3/2016	3	fract--	Fractured #3
10/3/2016	4	fract--	Fractured ML cusp of #14, Distal angular bone loss
10/4/2016	13	fract--	#13 restoration fractured off.
10/4/2016	13	fract--	multiple missing teeth, decay on #13, 17, fractured #13.
10/4/2016	13	fract--	#13- moderate bone loss, fractured endo treated
10/4/2016	13	fract--	#13, 17 carious, fract., nonrest., sympt
10/4/2016	3	fract--	Grossly carious and fractured #3 and #17 - nonrestorable
10/4/2016	4	fract--	Fractured and gross decay on #14, 4, 5, 6, 7, 10, 13, 18, 19, 30
10/4/2016	5	fract--	Fractured and gross decay on #14, 4, 5, 6, 7, 10, 13, 18, 19, 30
10/5/2016	14	fract--	Dental: Fractured/carious/non-restorable #1, 2, 10, 14, 30, 32, multiple other carious teeth
10/5/2016	14	fract--	Fractured/carious/non-restorable #2, 10, 14, 30, 32
10/5/2016	2	fract--	Frictional keratosis BM adjacent fractured #2
10/5/2016	2	fract--	#2 F fracture
10/5/2016	3	fract--	Fractured #13
10/5/2016	3	fract--	#3 M fracture

Date	Tooth	Key-No-Yes	phrase
10/5/2016	30	fract--	Re: #14 requires access closed and fractured acrylic facing on crown #30.
10/5/2016	4	fract-deliver-root	Buccal root of #4 fractured during delivery.
10/6/2016	12	fract--	Additional Narrative Performed cleaning and exam, fixed fractured restoration on #12 MOL
10/6/2016	3	fract-porcelain-	#5 3/4 porcelain crown replace due to fracture and repair.
10/6/2016	3	fx-porcelain-	#30 facial caries, replace crown.#2 has fx'ed facial porcelain that is neither a cosmetic or functional failure but pt c/o roughness.
10/6/2016	3	fract-partial-	Tx: limited oral eval, #13 has fractured partial coverage crown in gingival 1/2.
10/7/2016	19	fract-amalgam-root	#19 fractured mesiolingual cusp, occlusal amalgam, PAP around the mesial root
10/7/2016	19	fract--	Dental: #19 fractured mesiolingual cusp, PAP, recurrent caries
10/7/2016	19	fract--	#19 PAP, caries, fractured cusp
10/7/2016	31	broke--	A: Broken off chip from #31.
10/10/2016	18	fract-amalgam-	A: #18 MOL amalgam has fractured and is missing.
10/10/2016	19	fract--	Fractured #19
10/11/2016	12	fract--	#12 fractured and non-restorable.
10/11/2016	13	broke-partial-	Dental: Caries/broken teeth: #1,13,16,17, partially impacted #32
10/11/2016	14	fract--	#14 fractured
10/11/2016	14	fract--	PPTC with fractured #14.
10/11/2016	15	fract--	#15 extensive decay , fractured crown, TTP

Date	Tooth	Key-No-Yes	phrase
10/11/2016	15	fract--	Decayed, Fractured crown #15
10/11/2016	15	fract--	discussed about potential for fracture of decayed #14 during extraction of #15,
10/11/2016	18	fract--	Fractured #18
10/11/2016	30	fract--	#30/31 - coronal fractures and gross carious lesions
10/11/2016	30	fract--	#30/31 - coronal fractures and gross carious lesions - EXT
10/11/2016	31	fract--	#30/31 - coronal fractures and gross carious lesions
10/11/2016	31	fract--	#30/31 - coronal fractures and gross carious lesions - EXT
10/12/2016	19	fract--	#19, 20, 31 fractured crown
10/12/2016	19	fract--	Dental tooth #19 carious/fractured needs extraction
10/13/2016	14	fract--	Fractured and carious teeth #14 and #31 w/ large resin restorations.
10/13/2016	20	fract--	#20 carious and fractured crown
10/13/2016	20	fract--	S: 63yo male presents to clinic today for f/u s/p R subcondylar fracture, L intracapsular fractures on 7/24/2016 due to syncopal episode.
10/13/2016	31	fract--	Fractured and carious teeth #14 and #31 w/ large resin restorations.
10/13/2016	31	fract--	#31 Fractured crown.
10/13/2016	5	broke--root	Generalized broken down teeth with root tips remaining #3, #8, #9, #10, #13, #15,
10/13/2016	5	fract--	#5 fractured
10/14/2016	12	fract--	fractured #12

Date	Tooth	Key-No-Yes	phrase
10/14/2016	12	fract--	Tooth #12 grossly carious/fractured.
10/14/2016	12	fract--	Oral - Impacted teeth, grossly carious/fractured #12
10/14/2016	18	fract--	Dental: #1 DB cusp has fractured, tooth is sensitive to percussion and palpation, #18 Fractured but is not sensitive to percussion or palpation.
10/14/2016	18	fract--	#18 carious and fractured.
10/14/2016	18	fract--	A: #18 gross caries w/ fractured DB + DL cusps.
10/14/2016	18	fract--	Fractured and gross decay on #18
10/14/2016	18	split--	Fractured #18 split in half with gross decay
10/14/2016	3	broke--	Nov 2013: broken pinky, pins & wires currently in finger
10/14/2016	3	fract--	May 2013: right knee cap fracture, follow-up to remove hardware was in Feb 2015
10/14/2016	30	fract--	Fractured #30
10/17/2016	13	fract--	Mobile tooth 4, fractured tooth 5, mobile 6-8, fractured tooth 9, mobile bridge 11-13, mobile tooth 14.
10/17/2016	14	fract--	Mobile tooth 4, fractured tooth 5, mobile 6-8, fractured tooth 9, mobile bridge 11-13, mobile tooth 14.
10/17/2016	2	fract--	#2- parulis on buccal, large restoration, fractured tooth
10/17/2016	31	crack--	consult for 31, hx endo and has been told for yrs cracked, but has had no real pain.
10/17/2016	4	fract--	Mobile tooth 4, fractured tooth 5, mobile 6-8, fractured tooth 9, mobile bridge 11-13, mobile tooth 14.

Date	Tooth	Key-No-Yes	phrase
10/17/2016	5	fract--	Mobile tooth 4, fractured tooth 5, mobile 6-8, fractured tooth 9, mobile bridge 11-13, mobile tooth 14.
10/18/2016	12	fract--	Fractured tooth #5, #6, #12, #19
10/18/2016	12	fract--	Fractured tooth #5, #6, #12
10/18/2016	12	fract--	#12 fractured.
10/18/2016	18	fract--root	#18-Fractured M root, NON-Restorable
10/18/2016	18	fract--root	#18 fractured root- EXT, NON restorable
10/18/2016	18	fract--root	Fractured root, non restorable #18
10/18/2016	19	fract--	Fractured tooth #5, #6, #12, #19
10/18/2016	19	split-elevat-root	For tooth #19, Buccal trough created w/ surgical handpiece, roots split, and each elevated and retrieved separately.
10/18/2016	5	fract--	Fractured tooth #5, #6, #12, #19
10/18/2016	5	fract--	Fractured tooth #5, #6, #12
10/18/2016	5	broke--	Surgery on broken ankle when patient was 15 y.o.
10/19/2016	19	fract--	tooth #19 non-restorable, fractured
10/19/2016	19	fract--	Non-restorable, fractured tooth #19.
10/19/2016	19	broke--	Broken down #16 and #19.
10/19/2016	19	fract--	Gross caries and fracture on #19 and #16
10/19/2016	19	broke--	Dental: broken down #16 and #19
10/19/2016	3	split--	She has been religiously following 3 month recall split between private practice DDS and hygiene here at VCU.
10/19/2016	30	fract--	Fractured and carious tooth #30.

Date	Tooth	Key-No-Yes	phrase
10/19/2016	30	fract--	#30 Fractured filling
10/19/2016	5	fract--	#4 with fractured lingual cusp and M overhang, #5 mobile with RL at apex from previous radiographs, #11 D RL, DL decay, #12 F composite marginal defect, #18 purulent drainage from sulcus #19 D margina
10/20/2016	12	fract--	Gross caries on multiple teeth, fractured #12
10/20/2016	12	fract--	#12 fractured while eating mashed potatoes x 2 weeks ago and #21 is sensitive off and on percussion x several weeks.
10/20/2016	12	fract--	Gross caries on multiple teeth, tooth #12 fractured and decayed, tooth 21 decayed with percussion sensitivity
10/20/2016	12	fract--	Gross caries and fractured #12
10/20/2016	12	fract--	Dental: EXT #12 and 21, Carious #21 and fractured #12, symptomatic and on restorable.
10/20/2016	21	fract--	#12 fractured while eating mashed potatoes x 2 weeks ago and #21 is sensitive off and on percussion x several weeks.
10/20/2016	21	fract--	Gross caries on multiple teeth, tooth #12 fractured and decayed, tooth 21 decayed with percussion sensitivity
10/20/2016	21	fract--	Dental: EXT #12 and 21, Carious #21 and fractured #12, symptomatic and on restorable.
10/21/2016	2	fract--	A: Pt had implant consult in 11/2009 and was assigned to Dr in grad perio for implant placement in place of fractured/non-restorable #4.
10/21/2016	2	fract--	#20 - fractured MOD composite with recurrent decay

Date	Tooth	Key-No-Yes	phrase
10/21/2016	2	fract--	A: #20 temporary crown fractured, discarded by Pt
10/21/2016	20	fract--	Grossly fractured and carious #20
10/21/2016	3	fract--	#3 RCT w/ coronal fracture
10/24/2016	29	fract--	fractured #29
10/24/2016	29	fract--	Dental: fractured #29, occlusal wear
10/24/2016	29	fract--	Fractured #29
10/24/2016	29	fract--	PPTC for fractured #29
10/24/2016	29	fract--	Grossly carious #s 29, 19 (fractured), 15 (fractured)
10/24/2016	29	fract--	#29 carious, fract.,nonrest.,sympt
10/24/2016	5	fract--	2 PA's were taken.Tooth #5 fractured at the gingiva.
10/25/2016	15	fract--	#15, 32 carious, fract.,nonrest.,symptom
10/25/2016	31	fract--	#3 MO recurrent decay, #5 fractured off crown, #6 Fractured MI with caries, #7 MIDFL recurrent decay, #9DL caries, #12 fractured off crown, #20 B caries, #25 mobile, #27 D caries, #28 B Comp, #31 open
10/25/2016	31	fract--	PAP at apex of #6, PAP at Apex of #22, #5 fractured crown, #12 fractured crown, #25 periodontally hopeless, #31 open margin with M caries and furcation involvement
10/26/2016	4	fract--	O: BP 108/80 HR 72R Pt uses chewing tobacco, PSR 4,1,12,2,2, perio charting, fractured restoration 18-O
10/26/2016	4	fract--	Additional Narrative Note- repair fracture on #19 when restoring #20, and look at the 14 M when prepping 13, and 5 D when prepping #4

Date	Tooth	Key-No-Yes	phrase
10/26/2016	4	fract--	A: PPTC with fractured lingual cusp #4.
10/26/2016	4	fract--	Fractured Lingual cusp #4, pain
10/27/2016	30	fract--	Fractured #30
10/31/2016	18	broke--	#18 gross caries/broken tooth
10/31/2016	3	fract--	#3 Class IV ellis fracture symptomatic
10/31/2016	3	fract--	#3, 4, 7 are fractured at the gum line
10/31/2016	3	fract--	#3 is percussion sensitive and pt states it bothers him the most specially with the involved sharp area to his tongue at the fracture line
10/31/2016	3	broke--	pt states he's had dental tx on #3 2 years ago and broke while eating steak 4 months ago and its been bothering his tongue due to a sharp area at the fracture line
10/31/2016	3	fract--	#3 class IV ellis classification fracture
10/31/2016	5	fract--	#5 fractured with poor prognosis, caries extending to gingiva
10/31/2016	5	fract--	#5 fractured, approximating pulp
10/31/2016	5	fract--	#5 carious fractured non restorable
11/1/2016	13	fract--	jaw fracture closed reduction-2013
11/1/2016	19	fract--	Gross decay/fracture #19
11/1/2016	19	fract--	Dental: generalized carious, fractured #19 (grossly carious, symptomatic)
11/1/2016	30	fract--	#30 class IV ellis fracture
11/1/2016	30	fract--	#30 coronal fracture
11/1/2016	31	fract--	Crown of #31 fractured off a couple months ago.

Date	Tooth	Key-No-Yes	phrase
11/2/2016	14	crack-amalgam-	Hard tissue: #2-MB cusp crack about 5mm but not to CEJ and recurrent decay on O margin of amalgam, #14-distal margin of CVC crown leaking radiographically, #15-mesial margin is a radiographic artifact
11/2/2016	14	crack--	Hard tissue: #2-MB cusp crack about 5mm but not to CEJ (WATCH) , #14-D, #15-M, #19-D defective margins of crown - do not require replacemnt at this time (WATCH), class I-II mobility lower anteriors (p
11/2/2016	18	fract-forcep-	Forceps to extract teeth #18, 19 and crowns fractured at gumline.
11/2/2016	19	fract--	Abfraction on #8,9, 19,20, 21
11/2/2016	19	fract-forcep-	Forceps to extract teeth #18, 19 and crowns fractured at gumline.
11/2/2016	3	fract-amalgam-	exam: #30-fractured amalgam and lingual cusp, informed pt that she will need referral for restorative treatment #30.
11/2/2016	3	fract--	aegd to evaluate fractured #30
11/2/2016	3	broke--	Prob: Pt referred from perio to evaluate broken tooth #30
11/2/2016	3	fract--	TX: Evaluation #30 revealed fractured lingual cusps, supragingival.
11/2/2016	3	fract--	Prob: Fractured tooth #30
11/2/2016	3	fract-amalgam-	Prob: Weakened tooth structure #30, fractured amalgam core build-up
11/2/2016	3	fract--	Prepared #30 for full gold crown and determined that fractured lingual portion of build-up was insufficient for adequate R & R and that new build-up should be done with composite.

Date	Tooth	Key-No-Yes	phrase
11/2/2016	3	broke--	Treatment Note PPCT for LOE w/ CC: My filling broke (points #3)
11/2/2016	3	fract--	Pt reports #3 restoration fractured a couple of weeks ago.
11/2/2016	3	broke--	#3 broken ,
11/2/2016	3	broke--	referral made to AEGD for POPE and to eval broken tooth , #3
11/2/2016	3	broke--	RTC POE /Eval #3 (broken) and keep pt on a 6 mo recall
11/2/2016	3	fract--	Clinical exam of #3 show lingual decay and lingual fracture of restoration
11/2/2016	30	fract--	#30 Fractured 2 months ago, and is now bothering the patients gums and tongue specially while eating.
11/2/2016	30	fract--	#30 Fractured with evident decay.
11/2/2016	30	fract--	#30 Fractured D half
11/2/2016	30	fract--	#30 D Fracture
11/3/2016	2	fract--	#2 has large restoration that appears fractured
11/3/2016	2	fract--root	#2 root canal treated with post, suspect fractured temp filling
11/3/2016	5	fract--root	Fractured/decayed #3 and #5 with retained root tips
11/4/2016	13	broke--root	#13 broken root tip
11/4/2016	13	fx--	#13 fx
11/4/2016	13	fx--	numerous carious or fx teeth - 13,14,15,18,31
11/4/2016	15	fx--	numerous carious or fx teeth - 13,14,15,18,31
11/4/2016	18	broke--	#18 gross caries/ broken down

Date	Tooth	Key-No-Yes	phrase
11/4/2016	18	broke--	#18 - badly broken down, caries approximating pulp
11/4/2016	29	broke--	A: Patient stated that he broke crown off #29 on saturday eating hard candy.
11/4/2016	31	fract--	#15, 31, 32: gross carious, fractured lesions
11/4/2016	31	fract--	#5, 6 fractured, #30/31 carious
11/7/2016	3	fract--	Fractured #3
11/7/2016	31	fx--	EOE/IOE: hyperkeratosis on R buccal mucosa due to #31-MB fx.
11/8/2016	15	fract--	#15 fractured crown
11/8/2016	15	broke--root	Generalized broken down teeth with root tips remaining #3, #8, #9, #10, #13, #15,
11/8/2016	3	broke--root	Generalized broken down teeth with root tips remaining #3, #8, #9, #10, #13, #15,
11/8/2016	3	fract--	Fractured #3, Missing #20
11/8/2016	3	fract--	Fractured #3
11/8/2016	3	fract--root	Fractured #3, Palatal root in proximity to maxillary sinus
11/8/2016	3	fract--root	Fractured #3, Palatal root extending into maxillary sinus
11/8/2016	3	fract--vertical	Tooth #3 has Vertical root fracture and is non-restorable
11/9/2016	21	fract--	Dental History Pt has a C/RPD, tooth #21 fractured.
11/10/2016	14	fract--	#14, fractured off crown, #15 D of tooth fractured with gross decay, #17 recurrent decay
11/10/2016	15	fract--	#14, fractured off crown, #15 D of tooth fractured with gross decay, #17 recurrent decay

Date	Tooth	Key-No-Yes	phrase
11/10/2016	31	fract--	Pt reports of fracturing his tooth #31 while eating almonds couple of weeks ago and pain has gotten worse since past week.
11/11/2016	12	fract--	#3 MO recurrent decay, #5 fractured off crown, #6 Fractured MI with caries, #7 MIDFL recurrent decay, #9DL caries, #12 fractured off crown, #20 B caries, #25 mobile, #27 D caries, #28 B Comp, #31 open
11/11/2016	12	fract--	PAP at apex of #6, PAP at Apex of #22, #5 fractured crown, #12 fractured crown, #25 periodontally hopeless, #31 open margin with M caries and furcation involvement
11/11/2016	12	fract--	#3 MO recurrent decay, #5 fractured off crown, #6 Fractured MI with caries, #7 MIDFL recurrent decay, #9DL caries, #12 fractured off crown, #20 B caries, #25 mobile, #27 D caries, #28 B
11/11/2016	14	fract--	Fractured #14, RCT #14
11/11/2016	14	crack--	#14 cracked mesiodistally
11/11/2016	5	fract--	#3 MO recurrent decay, #5 fractured off crown, #6 Fractured MI with caries, #7 MIDFL recurrent decay, #9DL caries, #12 fractured off crown, #20 B caries, #25 mobile, #27 D caries, #28 B Comp, #31 open
11/11/2016	5	fract--	#5 Fractured off crown - explained treatme
11/11/2016	5	fract--	PAP at apex of #6, PAP at Apex of #22, #5 fractured crown, #12 fractured crown, #25 periodontally hopeless, #31 open margin with M caries and furcation involvement
11/11/2016	5	fract--	#3 MO recurrent decay, #5 fractured off crown, #6 Fractured MI with caries, #7 MIDFL recurrent decay, #9DL caries, #12 fractured off crown, #20 B caries, #25 mobile, #27 D caries, #28 B

Date	Tooth	Key-No-Yes	phrase
11/14/2016	2	broke--	pt states he's had dental tx on #3 2 years ago and broke while eating steak 4 months ago and its been bothering his tongue due to a sharp area at the fracture line
11/14/2016	4	fract--	#3, 4, 7 are fractured at the gum line
11/14/2016	4	broke--	pt states he's had dental tx on #3 2 years ago and broke while eating steak 4 months ago and its been bothering his tongue due to a sharp area at the fracture line
11/15/2016	18	fract-amalgam-	#18 Perc (slight), Palp (-), cold(non-lingering pain), Probing 3-4 mm, PA Radiograph reveals: coronal radiopacity consistent with O amalgam fractured distally, coronal radiolucency consistent with f
11/15/2016	2	fract--	1st operation: Fractured Tibia, April, 2014
11/15/2016	4	fract--	1st operation: Fractured Tibia, April, 2014
11/16/2016	14	fract--	14 ML cusp is fractures
11/16/2016	14	fract--	#14 fracture
11/16/2016	14	fract--vertical	Vertical fracture on 14 ML
11/16/2016	15	broke--	Grossly carious and broken down teeth: #3, 15, 19, 31.
11/16/2016	15	broke--	Multiple broken down clinical crowns: #3, 15, 19
11/16/2016	3	broke--	Multiple broken down clinical crowns: #3, 15, 19
11/16/2016	31	broke--	Grossly carious and broken down teeth: #3, 15, 19, 31.
11/16/2016	5	fract--	Teeth 5 and 6 symptomatic, fractured to gumline
11/16/2016	5	fract--	A: Restoration #5-MO fractured along central groove.

Date	Tooth	Key-No-Yes	phrase
11/17/2016	12	fract--	Facial abfraction lesions noted on #12 and #13 without sensitivity.
11/17/2016	12	fract--	A: #12 fractured, patient brought fractured tooth and restoration with him in ziplock bag.
11/17/2016	12	fract--	fractured #12
11/17/2016	12	fract--	fractured #12, patient chooses to EXT
11/17/2016	21	broke--	gross caries broken off #21 to make it non-restorable
11/18/2016	12	fract--	Fractured restoration and deep caries and apical PDL widening on #12,
11/18/2016	12	fract--	#12 fractured restoration, pain on palpation and percussion
11/18/2016	12	fract--	#12-fractured, carious, nonrestor., symp
11/18/2016	31	fract--	#31 ML cusp fractured
11/18/2016	31	fract--	#31 Caries and ML fracture
11/21/2016	14	fract--	Fractured 14
11/21/2016	15	fract--	#15 Non restorable tooth fracture.
11/21/2016	18	broke--root	#18 Broken D cusp down to root w/ gross caries.
11/21/2016	2	fract--	#2: Grossly carious with lingual cusp fracture.
11/21/2016	2	fract--	#2 Grossly carious and fractured.
11/21/2016	2	fract--	#2 fractured/carious.
11/21/2016	20	fract--	sue exam (Findings) Patch caries on facial #7 underneath crown margin , tooth #15 previous amalgum fracture on distal and portion lingual recommending that it be redone, repair on margin of the buccal

Date	Tooth	Key-No-Yes	phrase
11/22/2016	18	fract--	Significant dental findings: dentist referred to periodontist, #4 lingual fracture w/ carries, subgingival calculus, 4-8 mm PD, separation #9 facial, BOP, separation b/w #17-18, 31-32 inter
11/22/2016	18	fract--	Tooth #18 has crown fractured, non-tender
11/22/2016	3	fract--	#13- fractured crown
11/22/2016	30	fract--vertical	I/O: Hard tissue (including caries): DL cusp on #30 had a vertical fracture (possibly due to grinding habit), no other clinical carried upon very limited exam
11/22/2016	30	fract--root	Explained to parents that #30 will most likely need to be extracted due to the vertical fracture present as the fracture seems to be extending to the root.
11/22/2016	31	fract--	Fractured restoration #31
11/22/2016	31	fract--root	Fractured restoration #31 - previously root canal treated tooth
11/22/2016	31	fract--root	Fractured restoration on previously root canal tooth #31 - not restorable
11/22/2016	31	fract--	Fractured #31
11/22/2016	31	fract--	Fractured tooth #31
11/22/2016	31	fract--	36 yo female with fractured restoration on tooth #31.
11/22/2016	4	fract--	#4 lingual cusp fractured, non-restorable
11/28/2016	14	fract-elevat-	Elevator and forceps luxation of #14 - crown fractured off to below gumline.
11/28/2016	29	broke--	#29 started hurting 2 weeks ago after it broke.
11/28/2016	3	fract--	FPD #3-5 - fractured #5
11/28/2016	5	fract--	FPD #3-5 - fractured #5

Date	Tooth	Key-No-Yes	phrase
11/28/2016	5	fract--	#5 is also fractured but not painful.
11/30/2016	15	fract--	#15 examined by Dr and it was determined that there 10 mm pockets and furcation involvement with possible tooth fracture.
11/30/2016	2	fract--	A: Cervical abfraction of 12
11/30/2016	2	fract--	Tooth 16 appeared to have fractured the distal palatal cusp.Tooth anesthetised using two 2 percent Lidocaine with 1:100,000 epi and one half of 4 percent articaine with 1:100,000 epi placed buccal inf
11/30/2016	2	broke--	Pt reports tooth broke when eating sandwich 2 weeks ago.
11/30/2016	2	fract--	A: Patient reports fracture of #2 three days ago.
11/30/2016	2	fract--	Non-restorable/fractured #2
11/30/2016	2	fract--	Fractured/Non-restorable #2
11/30/2016	2	fract--	Dental: Fractured/non-restorable #2, multiple other carious teeth
11/30/2016	2	fract--	#2 fractured a week ago, constant dull pain since then.
11/30/2016	20	broke--	#20 broken tooth, Radiolucency and PAP
11/30/2016	20	broke--	Broken crown/ caries #20
11/30/2016	20	fract--	#20 non-restorable caries, crown has been fractured for about 1 year.
11/30/2016	20	broke--	Broken down #20
12/1/2016	14	broke--	Broken #2, Caries #14,18,19
12/1/2016	18	fract--	Fractured, nonrestorable teeth #1, #16, #18
12/1/2016	18	fract--	Fractured #18 nonrestorable

Date	Tooth	Key-No-Yes	phrase
12/1/2016	18	broke--	Broken #2, Caries #14,18,19
12/1/2016	19	broke--	patient has temp implant crown #3 with the occlusal screw exposed, broken down tooth #19, subgingival caries #11, 21, 28 and 31.
12/1/2016	19	broke--	Broken #2, Caries #14,18,19
12/1/2016	2	fract--	Tooth 12 fractured to gumline.
12/1/2016	2	fract--root	Previous RCT 12 fractured root tip.
12/1/2016	21	broke--	patient has temp implant crown #3 with the occlusal screw exposed, broken down tooth #19, subgingival caries #11, 21, 28 and 31.
12/1/2016	28	broke--	patient has temp implant crown #3 with the occlusal screw exposed, broken down tooth #19, subgingival caries #11, 21, 28 and 31.
12/1/2016	3	fract--	#30 fractured, arrested caries--endo testing completed and tooth is vital--core build up
12/1/2016	3	fract--	Fractured crown: #30
12/1/2016	3	fract--	Fractured crown: #3 with caries
12/1/2016	3	fract--	Fractured crown #30
12/1/2016	31	broke--	patient has temp implant crown #3 with the occlusal screw exposed, broken down tooth #19, subgingival caries #11, 21, 28 and 31.
12/2/2016	14	crack--	DX: Cracked tooth; PD of 14 mm on DL of #15 with chronic apical abscess traced with gutta percha.
12/2/2016	14	vrf--	Due to the deep probings on the buccal along with furcation involvement I recommended extraction of #14 because of a suspected VRF.

Date	Tooth	Key-No-Yes	phrase
12/2/2016	14	broke--	It was taken from Dr. and he recommended the extraction to be done in GradPerio for the ext of #14 and socket preservation after that a bone graft must be done and sinus lift might be recommended t
12/2/2016	4	fract--	Radiographic caries D #4, D#10, #12 Lingual cusp fracture, Bilateral Mn tori
12/5/2016	14	broke--	S: PPTC with broken crown on #14
12/5/2016	14	fract--	fractured crown on #14
12/5/2016	14	fract--	#14 fractured crown with RCT
12/5/2016	18	fract--	Grossly carious/fractured #18, 19.
12/5/2016	18	fract--	Dental - difficult exam, but grossly carious/fractured #18, 19.
12/5/2016	19	fract--	Grossly carious/fractured #18, 19.
12/5/2016	19	fract--	Dental - difficult exam, but grossly carious/fractured #18, 19.
12/5/2016	5	split--	Tx: comprehensive oral eval, identified signs of parafunction, broken restorations, #5 questionable prognosis, due to significant tooth structure loss, #13 split - hopeless, strongly recommended stres
12/6/2016	18	fract--	#18- grossly carious and fractured, PAP
12/6/2016	28	broke--	A: #2, 4, 5, 11, 12, 13, 14, 15, 19, 20, 21, 23, 24, 25, 26, 28, 29, 30, 31 are all broken down or non-restorable.
12/6/2016	28	broke--	Dental: #2, 4, 5, 11, 12, 13, 14, 15, 19, 20, 21, 23, 24, 25, 26, 28, 29, 30, 31 are all broken down or non-restorable.

Date	Tooth	Key-No-Yes	phrase
12/6/2016	28	broke--	#2, 4, 5, 11, 12, 13, 14, 15, 19, 20, 21, 23, 24, 25, 26, 28, 29, 30, 31 are all broken down or non-restorable.
12/7/2016	29	fract--	Fractured #29
12/7/2016	29	fract--	Fractured #29 - Pt elects to restore
12/7/2016	5	fract--	interested in the bridge from #7-10 and that she was also interested in having a bridge from #4-6 (#5 has fractured and only has lingual cusp remaining).
12/8/2016	29	fract--	Large caries/fracture #29
12/8/2016	29	fract--	Dental - Large fracture #29, PAP #29
12/8/2016	29	broke--	Tooth 29 broke about a month ago.
12/9/2016	18	crack--	Pt referred by his dentist for cracked #18.
12/9/2016	19	broke--	#19- broken crown, carious
12/9/2016	19	broke--	- #19- carious, broken crown, PAP
12/9/2016	19	broke--	- #19- broken crown, carious, PAP
12/9/2016	19	broke--	#19- abscess, broken crown
12/12/2016	30	fract--	Fractured #30
12/13/2016	14	crack--	Explained to Christine with the visible cracks noted and the persistant symptoms the recommendation at this point is an extraction of tooth #14.
12/13/2016	18	fx--	O: CompExam/ medDentHxRev / 128/92=70 / 2HBWX / clinical evidence of Fx 18-19 (see WandPic) also #1Fx / heavy sub and supra gingival
12/13/2016	18	fract--	Fracture on 18, large restorations on 18-20, endo tested necrotic

Date	Tooth	Key-No-Yes	phrase
12/13/2016	20	fract--	Fracture on 18, large restorations on 18-20, endo tested necrotic
12/13/2016	21	fract--	21 - NR NSRCT tooth with fractured crown at level of alveolar crest.
12/14/2016	14	fract--root	RCT tooth #30 fractured x "QUOTE" and #14 root tips have been present since the tooth fractured x "I can't remember when."
12/14/2016	14	fract--root	Fractured #30 and root tips #14
12/14/2016	14	fract--root	Dental: Extract fractured #30 and root tips #14
12/14/2016	19	broke-amalgam-	#18 M aspect of amalgam filling broke off when removing Alike temporary #19 at last appt
12/14/2016	19	broke--	A: IRM in access of 19, broken temp on 19 and temp on 20
12/14/2016	19	fract--	#19 restoration fracture
12/14/2016	3	fract--root	Patient was informed that #3 had a very questionable prognosis because of suspected root fracture observed on PA.
12/14/2016	30	fract--root	RCT tooth #30 fractured x "QUOTE" and #14 root tips have been present since the tooth fractured x "I can't remember when."
12/14/2016	30	fract--root	Fractured #30 and root tips #14
12/14/2016	30	fract--root	Dental: Extract fractured #30 and root tips #14
12/15/2016	14	fract--	Fractured #14
12/15/2016	18	fract--	Fractured #18
12/15/2016	30	fract-elevat-root	PPTC with #30 fractured crown at CEJ, reflected periostium, Elevated from furcation during which tooth fractured BL between the D and M root.
12/16/2016	2	broke--	98 - Neck (C2-C4) vertebrae broken during surfing accident

Date	Tooth	Key-No-Yes	phrase
12/16/2016	2	broke--	98 - Neck (C2-C4) vertebrae broken during surfing accident
12/16/2016	31	fract--	#31: gross fracture of the crown
12/20/2016	12	fract--	Initial evaluation of #12 reveals exposed pulp horn and distal fracture of crown below gum line.
12/20/2016	12	fract--	#12 fractured/grossly carious
12/20/2016	14	broke--	A: Broken #4, mobile crown #13, percussion sensitive on #14
12/20/2016	19	fract--	Fractured #19
12/21/2016	3	fract--	Fractured #30 crown at distal aspect
12/22/2016	14	fract--	#14 fractured
12/22/2016	15	broke--	2015 - broken collar bone repair
12/22/2016	19	fract--	#19-Fractured distal crown
12/22/2016	19	fract--	dental: Fractured tooth #19
12/22/2016	19	broke--	Broke part of the crown on #19 in august.

Vita

Dr. Riley Beth Sturgill was born on October, 1986 in Johnson City, TN and is an American citizen. Dr. Sturgill received her Bachelor of Science in Cell and Molecular Biology from the King University in 2008 and Doctor of Dental Medicine from the Arizona School of Dentistry & Oral Health. Dr. Sturgill then entered private practice in Phoenix, AZ and completed one year in general dental practice. In 2015, she came to the Virginia Commonwealth University School of Dentistry for the Advanced Specialty Program in Endodontics. Dr. Sturgill is a member of the AAE, ADA, and VDA and will enter private practice in Johnson City, TN. She will graduate with a Master of Science in Dentistry and a Certificate in Endodontics.